

Is there any special imaging finding in a pedunculated focal nodular hyperplasia with suspected torsion?

Soultana Foutziti, Alexandra Giatromanolaki, Ioannis Chrysafis, Savas P Deftereos

CASE REPORT

A 31-year-old woman with no significant medical history presented with epigastric pain in the emergency department of our hospital. Her laboratory tests revealed slightly elevated levels of serum glutamic-oxaloacetic transaminase with 97 U/L (normal <33 U/L) and serum glutamic pyruvic transaminase with 110 U/L (normal <31 U/L) and leukocytosis with 12.52 white blood cells (WBC)/ μ L (normal 3.50–10.80 WBC/ μ L). Severe tenderness was felt over the epigastrium, which extended to the right upper quadrant of the abdomen. Abdominal ultrasonography (US) revealed a well-defined, solid, oval structure with an approximate diameter of 4 cm and a heterogeneous, largely isoechoic to liver echogenicity. The mass was in contact with the lower surface of the liver and has an echogenic structure (scar) at its center. Abdominal computed tomography with a multiphase liver protocol (arterial, venous, and delayed phases) (CECT) revealed a mass-like lesion attached to the liver (segment II), measuring 4 cm at its widest dimension (Figure 1). The mass was hanging from the liver, with a vascular pedicle. On CT, the lesion was hypodense at the native time (Figure 1A), heterogeneously hyperdense at the arterial phase (Figure 1B), with a hypodense central scar that started capturing the intravenous contrast

in the late phase (Figure 1C and D). This heterogeneity on CT strengthened the possibility of a pedunculated Focal Nodular Hyperplasia (FNH) with torsion, which was in accordance with the referred abdominal pain. This possibility was reinforced by the “corkscrew-like” appearance of the peduncle on CT scan (Figure 1E and F). This was considered an evidential finding (special imaging finding, otherwise key finding).

Surgically, a well-circumscribed, ovoid tumor mass, histopathologically confirmed as FNH (Figure 1G), originating from segment II of the liver, and a semi-twisted pedicle was identified and removed.

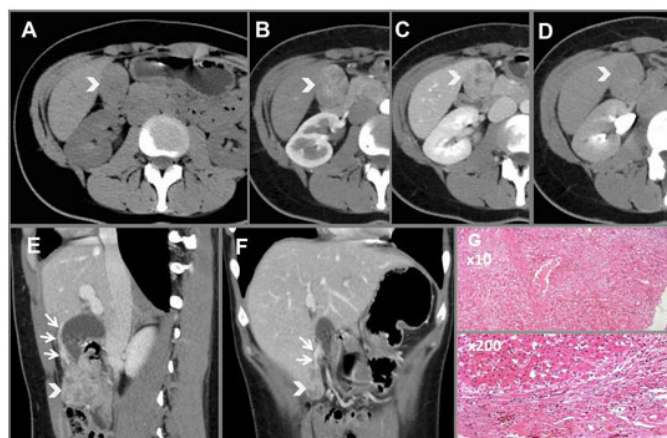


Figure 1: A multiphase CECT, revealing a mass-like lesion attached to the liver segment II: (A) hypodense in the native time and (B) heterogeneously hyperdense in the arterial time, with a hypodense central scar (B, C) that started contrast enhancement in the late phase (D). The mass (arrowhead) viewed in sagittal (E) and coronal plane (F), hanging from the liver, with a prominent vascular pedicle (arrows), considered as the key finding (G). Microscopically, liver sections revealed typical nodular appearance with prominent fibrosis, dilated arterial branches, and lymphocytic infiltration.

Soultana Foutziti¹, Alexandra Giatromanolaki², Ioannis Chrysafis³, Savas P Deftereos⁴

Affiliations: ¹MD, MSc Consultant of Radiology Department, University Hospital of Alexandroupolis, Alexandroupolis, Greece; ²MD, PhD Professor of Pathology Department, University Hospital of Alexandroupolis, Alexandroupolis, Greece; ³MD, Director of Radiology Department, University Hospital of Alexandroupolis, Alexandroupolis, Greece; ⁴MD, PhD, Associate Professor of Radiology, University Hospital of Alexandroupolis, Alexandroupolis, Greece.

Corresponding Author: Soultana Foutziti, Dragana, Alexandroupolis, Greece; Email: foutzita@gmail.com

Received: 24 October 2022

Accepted: 13 December 2022

Published: 28 December 2022

DISCUSSION

Focal nodular hyperplasia [1–3] is a benign liver tumor that usually does not require surgery [4]. The diagnosis is challenging for rare pedunculated forms of

FNH, which may require resection. Furthermore, torsion of the pedicle must be considered when heterogeneity is depicted by CT. While FNH is a common benign liver tumor, pedunculated FNH is a rare entity of a challenging diagnosis, since it may be mistaken for other benign or malignant liver tumors. The depiction of “corkscrew-like” appearance of the peduncle on CT scan was considered an evidential finding (special imaging finding, otherwise key finding).

CONCLUSION

The recognition of “corkscrew-like” appearance of the peduncle on CT scan improves patient care by avoiding potential complications such as torsion of the pedicle or compression of the surrounding organs.

Keywords: CT, Pedunculated FNH, Torsion

How to cite this article

Foutzitzi S, Giatromanolaki A, Chrysafis I, Deftereos SP. Is there any special imaging finding in a pedunculated focal nodular hyperplasia with suspected torsion? *Int J Case Rep Images* 2022;13(2):243–245.

Article ID: 101370Z01SF2022

doi: 10.5348/101370Z01SF2022CI

REFERENCES

1. Badea R, Meszaros M, Al Hajjar N, Rusu I, Chiorean L. Benign nodular hyperplasia of the liver-pedunculated form: Diagnostic contributions of ultrasonography and consideration of exophytic liver tumors. *J Med Ultrason* (2001) 2015;42(1):97–102.
2. Zeina AR, Glick Y. Pedunculated hepatic focal nodular hyperplasia. *Ann Hepatol* 2016;15(6):929–31.
3. Koolwal J, Birkemeier KL, Zreik RT, Mattix KD. Pedunculated focal nodular hyperplasia in a healthy toddler. *Proc (Bayl Univ Med Cent)* 2018;31(1):97–9.
4. Martiniuc A, Dumitraşcu T. Pedunculated focal nodular hyperplasia of the liver. *Surg Gastroenterol Oncol* 2018;23(1):79–82.

Author Contributions

Soultana Foutzitzi – Conception of the work, Design of the work, Acquisition of data, Analysis of data,

Interpretation of data, Drafting the work, Final approval of the version to be published, Agree to be accountable for all aspects of the work in ensuring that questions related to the accuracy or integrity of any part of the work are appropriately investigated and resolved

Alexandra Giatromanolaki – Design of the work, Acquisition of data, Analysis of data, Interpretation of data, Revising the work critically for important intellectual content, Final approval of the version to be published, Agree to be accountable for all aspects of the work in ensuring that questions related to the accuracy or integrity of any part of the work are appropriately investigated and resolved

Ioannis Chrysafis – Acquisition of data, Interpretation of data, Drafting the work, Final approval of the version to be published, Agree to be accountable for all aspects of the work in ensuring that questions related to the accuracy or integrity of any part of the work are appropriately investigated and resolved

Savas P Deftereos – Conception of the work, Design of the work, Acquisition of data, Interpretation of data, Drafting the work, Revising the work critically for important intellectual content, Final approval of the version to be published, Agree to be accountable for all aspects of the work in ensuring that questions related to the accuracy or integrity of any part of the work are appropriately investigated and resolved

Guarantor of Submission

The corresponding author is the guarantor of submission.

Source of Support

None.

Consent Statement

Written informed consent was obtained from the patient for publication of this article.

Conflict of Interest

Authors declare no conflict of interest.

Data Availability

All relevant data are within the paper and its Supporting Information files.

Copyright

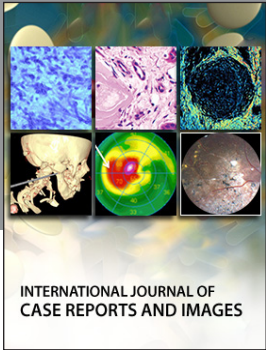
© 2022 Soultana Foutzitzi et al. This article is distributed under the terms of Creative Commons Attribution License which permits unrestricted use, distribution and reproduction in any medium provided the original author(s) and original publisher are properly credited. Please see the copyright policy on the journal website for more information.

Access full text article on
other devices



Access PDF of article on
other devices





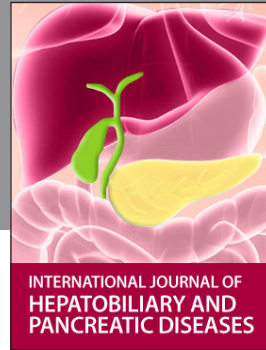INTERNATIONAL JOURNAL OF CASE REPORTS AND IMAGES



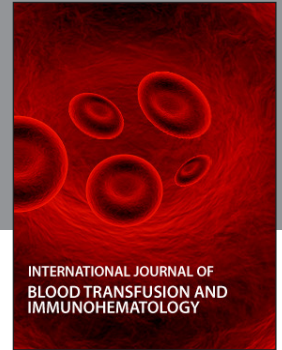VIDEO JOURNAL OF CLINICAL RESEARCH



VIDEO JOURNAL OF BIOMEDICAL SCIENCE



INTERNATIONAL JOURNAL OF HEPATOBILIARY AND PANCREATIC DISEASES



INTERNATIONAL JOURNAL OF BLOOD TRANSFUSION AND IMMUNOHEMATOLOGY



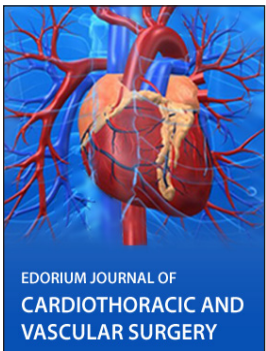
EDORIUM JOURNAL OF OPHTHALMOLOGY



Submit your manuscripts at
www.edoriumjournals.com



EDORIUM JOURNAL OF MEDICINE



EDORIUM JOURNAL OF CARDIOTHORACIC AND VASCULAR SURGERY



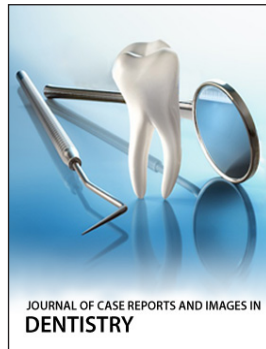
JOURNAL OF CASE REPORTS AND IMAGES IN ORTHOPEDICS AND RHEUMATOLOGY



EDORIUM JOURNAL OF PSYCHOLOGY




EDORIUM JOURNAL OF CELL BIOLOGY



JOURNAL OF CASE REPORTS AND IMAGES IN DENTISTRY



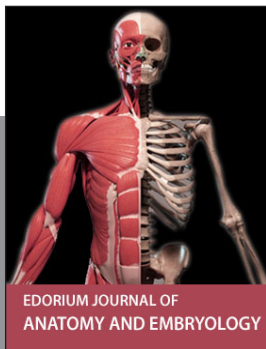
EDORIUM JOURNAL OF CANCER



EDORIUM JOURNAL OF PSYCHIATRY



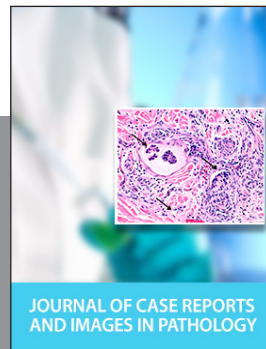JOURNAL OF CASE REPORTS AND IMAGES IN INFECTIOUS DISEASES



EDORIUM JOURNAL OF ANATOMY AND EMBRYOLOGY



EDORIUM JOURNAL OF SURGERY



JOURNAL OF CASE REPORTS AND IMAGES IN PATHOLOGY



EDORIUM JOURNAL OF ANESTHESIA