

Successful management of primary intestinal diffuse large B-cell lymphoma complicated with chylothorax

Dian Pratiwi Meliala, Adeodatus Yuda Handaya,
Radhea Miraz Bagaskoro, Nugira Dinantia, Mardiah Suci Hardianti

ABSTRACT

Introduction: Primary intestinal non-Hodgkin's lymphoma is a part of extranodal non-Hodgkin's lymphoma which is rare in incidence, moreover when complicated with chylothorax.

Case Report: A 26-year-old female patient was referred to our hospital presenting a distended abdomen, dyspnea, and sepsis due to infected surgical wound from a laparotomy and hemi-colectomy with ileostomy done 11 days before in other hospital. Pathology result was an intestinal activated B-cell non-Hodgkin lymphoma with positive CD20 and MUM1 immunostaining. A massive milky pleural effusion with a high level of triglycerides indicating a chylothorax was managed by insertion of water seal drainage. An R-CHOP regimen was commenced after stabilization of critical condition, and the chylothorax improved after two cycles of chemotherapy. The patient completed eight cycles of R-CHOP and achieved complete remission followed by a surgical re-anastomosis. She remained in complete remission with fully active life for almost four years until this report was submitted.

Conclusion: This case emphasized the importance of awareness due to the non-specific symptoms of an intestinal lymphoma. The prompt evacuation of co-occurring chylothorax is another important management to highlight. Optimum primary surgery followed by R-CHOP chemotherapy has led to successful outcome as remarked by prolonged disease free survival in this case.

Keywords: Chylothorax, DLBCL, Intestinal lymphoma, Lymphoma

How to cite this article

Meliala DP, Handaya AY, Bagaskoro RM, Dinantia N, Hardianti MS. Successful management of primary intestinal diffuse large B-cell lymphoma complicated with chylothorax. Int J Case Rep Images 2022;13:101292Z01DM2022.

Article ID: 101292Z01DM2022

doi: 10.5348/101292Z01DM2022CR

Dian Pratiwi Meliala¹, Adeodatus Yuda Handaya², Radhea Miraz Bagaskoro¹, Nugira Dinantia¹, Mardiah Suci Hardianti¹

Affiliations: ¹MD, Division of Hematology and Medical-Oncology, Department of Internal Medicine, Faculty of Medicine, Public Health and Nursing, Universitas Gadjah Mada/Dr. Sardjito Hospital, Yogyakarta, Indonesia; ²MD, PhD, Division of Digestive Surgery, Department of Surgery, Faculty of Medicine, Public Health and Nursing, Universitas Gadjah Mada/Dr. Sardjito Hospital, Yogyakarta, Indonesia.

Corresponding Author: Mardiah Suci Hardianti, MD, PhD, Division of Hematology and Medical-Oncology, Department of Internal Medicine, Faculty of Medicine, Public Health and Nursing, Universitas Gadjah Mada/Dr. Sardjito Hospital, Yogyakarta 55281, Indonesia; Email: mardiah.suci@ugm.ac.id

Received: 14 December 2021

Accepted: 23 February 2022

Published: 04 March 2022

INTRODUCTION

Most non-Hodgkin's lymphoma (NHL) arises in the lymph nodes, spleen, Waldeyer's ring, and thymus. One-third cases arise from extranodal sites such as gastrointestinal tract (GIT), thyroid, testis, and ovarium. Gastrointestinal tract is the most common site of extranodal NHL including diffuse large B-cell lymphoma (DLBCL) subtype, and the prevalence has been rising [1–4].

Small bowel/intestinal lymphoma is a rare form of intestinal tumor, although it is most common after adenocarcinoma. The symptoms were not specific, which usually lead to misdiagnosis at the initial stage. It occurs more in immunocompromised people. The incidence is higher in eastern than western countries, with male to be more prevalent than female [1, 2].

Establishing clinical diagnosis of lymphoma in GIT is quite difficult due to the non-specific symptoms with common complaints of stomachache or weight loss due to anorexia. The diagnosis is mostly established after a surgery due to an intestinal obstruction, intra-abdominal bleeding, or perforation [5, 6].

Chylothorax is a leakage of the lymph fluid accumulating in the pleural cavity due to a damaged thoracic duct. It may be caused by either a trauma (iatrogenic) or non-trauma. The most common cause of non-trauma is malignancy-related lymphoma. Chylothorax can be life-threatening or fatal with morbidity and mortality rate of 10% [7, 8]. Lymph fluid which leaks into pleural cavity causes malnutrition, immunological metabolic disorder, and dyspnea. Chylothorax in lymphoma is quite rare, with an incidence about 2% from all causes of pleural effusion in adult [8].

CASE REPORT

A 26-year-old female patient was admitted to an emergency unit in Pulau Pinang Hospital, Malaysia due to fever, severe lower abdominal pain radiating to epigastrium, and profuse diarrhea (10 times per day). She had been suffering from abdominal pain and weight loss around 8 kilograms within the last two months, and occasional subfebrile temperature. She only weighed 37 kilograms, with height of 155 cm and body surface area (BSA) of 1.29 m². An abdominal ultrasound examination revealed free fluid, and an X-ray showed air below the left diaphragm. Blood gas analysis showed metabolic acidosis. She was suspected to have a perforated appendicitis. She underwent an emergency abdominal surgery and right hemicolectomy with ileostomy. A mass and inflammation of the caecum with perforated appendix and mesenteric lymph moderate to large size were found alongside small bowel and colon mesentery. One liter of seropurulent fluid was evacuated from peritoneal cavity.

Based on the pathological anatomy report of right hemicolectomy tissue (terminal ileum, appendix, distal colon, cecum), omentum, ovarian tissue, and right mesentery lymph node showed a diffuse large B-cell lymphoma (DLBCL) activated B cell (ABC) type with strong positivity for CD20, PAX 5, BCL-2, MUM1/IRF4 immunostaining and negative stain for CD3, CD5, CD10, BCL-6 cMYC, Epstein–Barr virus (EBV), and AE1/AE3 with proliferative index around 80–90%.

On day 5 after abdominal surgery, pleural effusion was found on thorax X-ray. An insertion of chest tube obtained a 900 mL of hemoserous fluid. On day 11 after surgery, the abdomen was distended. A contrast enhanced computed tomography (CT) showed bilateral pleural effusion with multiple right hila, pericardial, and abdominopelvic lymphadenopathy. Lobulated presacral mass was also present and suspected as rectal or pelvic mass. Due to personal reason, the patient requested to continue therapy in Indonesia.

She was admitted to Dr. Sardjito Hospital, Yogyakarta, Indonesia on July 15, 2018 with heavy dyspnea. Thorax X-ray showed massive bilateral pleural effusion (Figure 1A). A water-sealed drainage (WSD) was inserted revealing milky pleural effusion with a high triglycerides level (442 mg/dL). Cytology analysis showed an atypical lymphoid cell. She also presented an infected surgical wound accompanied with fever. She was diagnosed as primary intestinal DLBCL complicated with chylothorax and sepsis due to the infected surgical wound. Initial laboratory parameters showed anemia and thrombocytosis (Table 1). Ten days after clinical stabilization, first chemotherapy was commenced on July 25, 2018 with adjustment to 80% from standard dose of R-CHOP based on BSA due to high tumor burden and low performance status (ECOG 4), with Rituximab 400 mg (day 1), Doxorubicin 50 mg (day 1), Vincristine 2 mg (day 1), Cyclophosphamide 750 mg (day 1), and Prednisone 100 mg day 1–5. Following first chemotherapy, the pleural effusion was still produced and the patient was discharged carrying the inserted WSD. The thorax X-ray evaluation on July 26, 2018 has not yet showed significant improvement of pleural effusion (Figure 1B).

Three weeks later, she continued the second cycle of R-CHOP after transfusion with one unit of packed red cells on August 15, 2018. The dose of chemotherapy was

Table 1: Laboratory examination comparison of initial condition and after second chemotherapy cycle with adjusted dose of R-CHOP

Parameters	July 15, 2018	Sept 4, 2018
Leukocyte (10 ³ /μL)	9.03	1.79↓
Erythrocyte (10 ⁶ /μL)	3.83	4.95
Hemoglobin (g/dL)	10.3	13.5
Hematocrit (%)	32.1	40.6
MCV (fL)	n/a	82.0
MCH (pg)	n/a	27.3
MCHC (g/dL)	n/a	33.3
RDW-CV (%)	n/a	14.8
Thrombocyte (10 ³ /μL)	587↑	279
SGOT/AST (U/L)	n/a	12
SGPT/ALT (U/L)	n/a	25
BUN (mg/dL)	5.50	6
Creatinine (mg/dL)	0.40	0.38
Albumin (g/dL)	2.99	n/a
Natrium (mmol/L)	132	n/a
Kalium (mmol/L)	3.88	n/a
Chloride (mmol/L)	92	n/a

MCV: Mean corpuscular volume; MCH: Mean corpuscular hemoglobin; MCHC: Mean corpuscular hemoglobin concentration; RDW-CV: Red cell distribution width-coefficient of variation; SGOT/AST: Serum glutamic-oxaloacetic transaminase/aspartate aminotransferase; SGPT/ALT: Serum glutamic-pyruvic transaminase/alanine transaminase; BUN: Blood urea nitrogen

maintained with the same dose as the first cycle. By this time the overall symptoms had improved, the production of effusion had also decreased resulting only around 50 mL/day followed by WSD release. After five days, on August 20, 2018, the thorax X-ray showed decreasing pleural effusion production (Figure 1C). Evaluation of the routine blood work on September 4, 2018 before 3rd chemotherapy cycle showed total leukocyte of $1.79 \times 10^3/\mu\text{L}$ (Table 1).

The standard dose of R-CHOP was started on 3rd cycle of chemotherapy and continued until 8 cycles. Patient condition gradually improved along with subsequent cycles. Evaluation of abdominal contrast multislice CT (MSCT) on February 1, 2019 showed a complete remission (CR) of the abdominal mass, with ileostomy stoma. The patient was referred to a digestive surgeon for surgical reanastomosis.

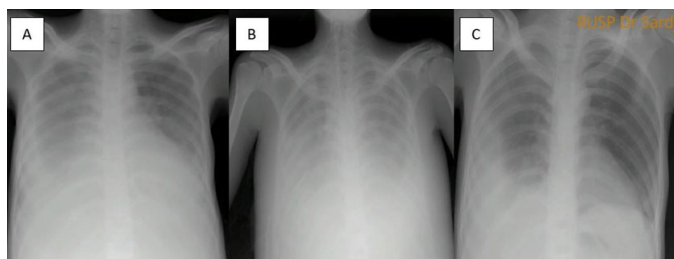


Figure 1: (A) Thorax X-ray before chemotherapy (July 15, 2018). (B) After first cycle chemotherapy (July 26, 2018). (C) After second cycle chemotherapy (Aug 20, 2018).

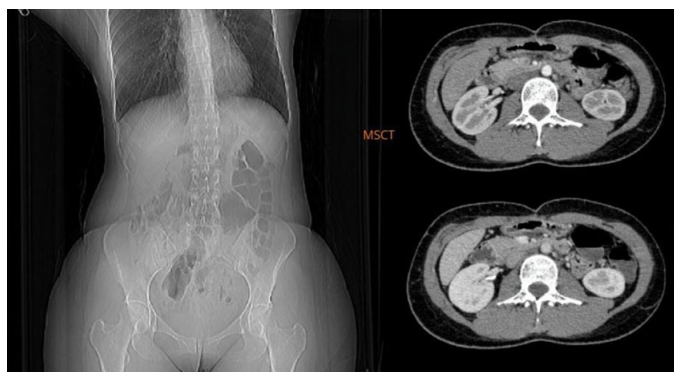

Figure 2: Latest evaluation of abdominal contrast multislice CT (MSCT) with no mass or lymphadenopathies (Oct 25, 2021).

The latest serial evaluation of abdominal contrast MSCT on October 25, 2021 was clear (Figure 2). The patient remained in complete remission with an active life (ECOG 0) for almost four years until this report was submitted.

DISCUSSION

Gastrointestinal tract lymphoma is usually secondary to the widespread nodal diseases and primary GIT lymphoma is very rare, accounting for 1–4% of all gastrointestinal malignancies. The symptoms of GIT

lymphoma were unspecific and difficult to be distinguished with other GIT diseases [2, 3]. This case presented non-specific gastrointestinal symptoms in the last two months accompanied with B-symptoms of lymphoma such as unintended weight loss and occasional fever.

Diffuse large B-cell lymphoma is the most common subtype of GIT lymphoma and almost involved to the entire site of GIT. There have been many advances in the management of GIT lymphoma in the last two decades leading to a better understanding of the etiology, molecular aspect, and knowledge of critical signaling pathways [3]. The histopathology of this case was DLBCL.

Based on the proportion among GIT lymphoma, gastric lymphomas have highest incidence (50–60%), followed by small bowel lymphoma (20–30%), and colon as the rarest case (6–12%). In the small bowel lymphoma, the most common location is ileum (58%), jejunum (26.5%), and duodenum (17.6%). Ileum is a part of small bowel correlated most to the lymphoid tissue [2, 5, 9]. Cecum is also common site for lymphoma, which is most likely spreading from the ileum. The incidence proportion of GIT lymphoma is 2:1 between male and female [3, 5]. This case presented a mass and inflammation of the cecum with perforated appendix and mesenteric lymph moderate to large size alongside small bowel and colon mesentery.

Almost 90% of primary GIT lymphomas arise from B-cell lineage, small number from T-cell lymphoma and Hodgkin lymphoma. Based on histologic subtypes, there are some predilections such as mucosa-associated lymphoid tissue (MALT) lymphoma on gaster, mantle cell lymphoma (MCL) in terminal ileum, jejunum, and colon similar to enteropathy-associated T-cell lymphoma (EATL) on jejunum, and follicular lymphoma (FL) in duodenum. Lymphomas which appeared in several sites or multifocal are MALT lymphomas and follicular lymphomas [3].

Dawson's criteria are used for labeling primary gastrointestinal lymphoma, which include (1) absence of peripheral lymphadenopathy at the time of presentation; (2) lack of enlarged mediastinal lymph nodes; (3) normal total and differential white blood cell count; (4) predominance of bowel lesion at the time of laparotomy with only lymph nodes obviously affected in the immediate vicinity; and (5) no lymphomatous involvement of liver and spleen [2]. This case fits the all these criteria for primary GIT lymphoma.

Risk factor

Several risk factors that have been known to play a role in GIT lymphoma were infection of *Helicobacter pylori* (*H. pylori*), human immunodeficiency virus (HIV), *Campylobacter jejuni* (*C. jejuni*), EBV, Hepatitis B virus (HBV), human T-cell lymphotropic virus-1 (HTLV-1), celiac disease, inflammatory bowel disease, and immunocompromised condition [3].

The etiopathogenesis of small bowel lymphoma

is still unclear, but there was a study predicting the disease arises from local antigen-responsive B-cells that result in B-cell lymphoma of large cell variety in 70% of small bowel neoplasms [3, 5]. In this case report, the histopathological subtype was DLBCL. Non-Hodgkin's lymphomas which arose on different sites at the same time (ileum and cecum) were rare, and moreover on the appendix [5]. Possible explanation for this case is the spreading of lymphoma from the intestine to appendix and cecum.

Molecular subtypes of DLBCL

There are two subtypes of DLBCL, i.e., germinal center B-cell like DLBCL (GCB-DLBCL) and activated B-cell like DLBCL (ABC-DLBCL), with ABC subtype had been reported to have worse prognosis than GCB-DLBCL [10, 11]. In addition to GCB and ABC subtypes, double-hit lymphomas (approximately 5–10% of patients), and double-expressor lymphomas, with concurrent overexpression of MYC protein and BCL2 protein are also an aggressive type of DLBCL with poor prognosis [12]. Regardless of molecular subtypes, standard front-line treatment for DLBCL remained R-CHOP or CHOP regimen. However, around 40% DLBCL patients will relapse after initial therapy [12]. In this case the molecular subtype was ABC-DLBCL with positive CD20, MUM1/IRF4, and negative BCL-6 immunostaining.

Staging of intestinal DLBCL

There is no consensus to determine the most suitable staging system for intestinal DLBCL. There are three staging systems, those are modified Ann Arbor system, Lugano system, and Paris staging system. The comparison between the three systems is shown in Table 2.

A research from Korea have compared the three staging systems with 66 cases of resected intestinal DLBCL including 15 cases of small intestine lymphoma and 51 cases with ileocecal lymphoma [4]. The patients underwent initial surgical resection and continued with adjuvant CHOP chemotherapy (n=26); and 40 patients were given R-CHOP. Median follow-up was 40.4 months

with interquartile range (2.1–171.6 months). Fifty-six patients (84.8%) reached complete remission. Five years survival rate was 86.4%. From those three staging systems, only T stage component of Paris classification showed significant prognostic score to overall survival of univariate analysis. However, when multivariate analysis was done, there was no significant correlation between those three staging systems. The conclusion of this study was that T stage of Paris classification system might be the prognostic factor in intestinal DLBCL. Furthermore, in resectable intestinal DLBCL, addition of Rituximab to the CHOP regimen did not increase the overall survival [4]. Although the pathological anatomy report from right hemicolectomy had included quite wide tissues involving terminal ileum to caecum with surrounding enlarged lymph nodes, an ileostomy and a contrast enhanced-CT on day 11 after surgery showing bilateral pleural effusion with multiple right hila, pericardial, abdominopelvic lymphadenopathy and lobulated presacral mass. This indicated the non-resectable stage of this case that obliged subsequent chemotherapy. Eight cycles of R-CHOP resulted in a complete remission which allowed a successful surgical reanastomosis and prolonged progression free survival.

Mechanism of chylothorax

Chylothorax is the accumulation of chyle in the pleural cavity. There are two mechanisms that promote the chyle influx to the pleural cavity, which are traumatic (iatrogenic/surgical) and non-traumatic. Traumatic chylothorax is mostly caused by thoracic surgery where an increase of pressure inside the thoracic duct causing a retrograde flow of chyle through lymph channels in parietal pleural to the pleural cavity. Traumatic chylothorax is usually unilateral involving the affected side of ruptured duct. Malignancy, particularly NHL is the most cause of non-traumatic chylothorax in adult. The rupture of the thoracic duct due to tumor infiltration to the thoracic duct causes the chyle accumulated in pleural cavity. Non-traumatic chylothorax usually involves bilateral pleural spaces [8, 13].

Table 2: Comparison of Lugano stages, modified Ann Arbor stages, and Paris TNMB classifications

Stage	Lugano stage	Modified Ann Arbor stage	Ann Arbor stage	Paris TNMB stage	Extent of lymphoma
Stage I	Stage I	IE1		T1N0M0-1 B0	Mucosa, submucosa, muscularis propria, subserosa, serosa penetration
Stage II	Stage III1	IIE1		T1-4N1M0-1 B0	Regional lymph nodes
	Stage II2	IIE2		T1-4N2M0-1 B0	Intra-abdominal distant lymph nodes
	Stage IIE	IIE2		T1-4N0M0-1 B0	Invasion of neighboring organ
Stage IV	Stage IV	IIIE		T1-4N3M0-1 B0	Extra-abdominal lymph nodes
		IVE		T1-4N0-2M2 B0	Diffuse/disseminated spread
		IVE		T1-4N0-2M0-1 B1	Bone marrow involvement

T: Tumor, N: Nodal involvement, M: Metastasis, B: Bone marrow involvement, E: Extranodal involvement.

Diagnosis of chylothorax is established with the presence of chylomicrons in lipoprotein electrophoresis analysis of pleural effusion. Triglyceride levels above 110 mg/dL indicates high probability of chylothorax. The complication of chylothorax includes malnutrition, immunocompromise, and respiratory distress. Accumulative duration, volume, and chronicity of effusion affect severity of the complications [14].

In this patient, there were still two possible causes of chylothorax. Iatrogenic cause was supported by the fact of abdominal surgery, and non-traumatic cause was also possible due to the extensive pressure related to the massive extension of the intestinal mass extending to the cecum and surrounding lymph nodes. Moreover, the chylothorax involved bilateral pleural spaces in this case.

CONCLUSION

Primary gastrointestinal DLBCL particularly of the intestinal site complicated with chylothorax has been exceptionally rare in the literature. This case emphasized the importance of awareness due to the non-specific symptoms of an intestinal lymphoma. The prompt evacuation of co-occurring chylothorax is another important management to highlight. Optimum primary surgery followed by R-CHOP chemotherapy has led to successful outcome despite the advanced stage of the disease, as remarked by prolonged disease free survival in this case.

REFERENCES

1. Watson GA, Gleeson JP, Kelly D, et al. Non-Hodgkin's lymphoma of the appendix. *Cancer and Clinical Oncology* 2015;5(1):1.
2. Sharma U, Baidya JL. Uncommon diagnosis of common presentation: Diffuse large B-cell lymphoma of ileocaecal region. *BBMed* 2017;1(1):37–41.
3. Ghimire P, Wu GY, Zhu L. Primary gastrointestinal lymphoma. *World J Gastroenterol* 2011;17(6):697–707.
4. Hwang HS, Yoon DH, Suh C, Park CS, Huh J. Intestinal diffuse large B-cell lymphoma: An evaluation of different staging systems. *J Korean Med Sci* 2014;29(1):53–60.
5. Jagdish B, Tati SY, Pai G, et al. Non Hodgkin's lymphoma of ileum and cecum presented as pelvic abscess followed by right iliac fossa mass – A rare presentation. *IOSR Journal of Dental Medical Science* 2014;13(11):86–9.
6. Giriyan SS, Jain G. Non Hodgkin lymphoma of caecum – A case report. *IOSR Journal of Dental Medical Science* 2015;14(11):90–2.
7. McGrath EE, Blades Z, Anderson PB. Chylothorax: Aetiology, diagnosis and therapeutic options. *Respir Med* 2010;104(1):1–8.
8. Khosravi A, Anjidani AA. Spontaneous recovery of chylothorax caused by lymphoma. *Hematol Oncol Stem Cell Ther* 2009;2(3):431–4.

9. Lo Re G, Federica V, Midiri F, et al. Radiological features of gastrointestinal lymphoma. *Gastroenterol Res Pract* 2016;2016:2498143.
10. Akinleye A, Chen Y, Mukhi N, Song Y, Liu D. Ibrutinib and novel BTK inhibitors in clinical development. *J Hematol Oncol* 2013;6:59.
11. Blenk S, Engelmann J, Weniger M, et al. Germinal center B cell-like (GCB) and activated B cell-like (ABC) type of diffuse large B cell lymphoma (DLBCL): Analysis of molecular predictors, signatures, cell cycle state and patient survival. *Cancer Inform* 2007;3:399–420.
12. Nowakowski GS, Czuczman MS. ABC, GCB, and double-hit diffuse large B-cell lymphoma: Does subtype make a difference in therapy selection? *Am Soc Clin Oncol Educ Book* 2015;e449–57.
13. Van De Voorde L, Vanneste B, Borger J, Troost EGC, Werner P. Rapid decline of follicular lymphoma-associated chylothorax after low dose radiotherapy to retroperitoneal lymphoma localization. *Case Rep Hematol* 2014;2014:684689.
14. Kumar A, Harris K, Roche C, Dhillon SS. A 69-year-old woman with lymphoma and chylothorax looking beyond the usual suspect. *Ann Am Thorac Soc* 2014;11(9):1490–3.

Author Contributions

Dian Pratiwi Meliala – Conception of the work, Design of the work, Acquisition of data, Interpretation of data, Drafting the work, Final approval of the version to be published, Agree to be accountable for all aspects of the work in ensuring that questions related to the accuracy or integrity of any part of the work are appropriately investigated and resolved

Adeodatus Yuda Handaya – Conception of the work, Interpretation of data, Revising the work critically for important intellectual content, Final approval of the version to be published, Agree to be accountable for all aspects of the work in ensuring that questions related to the accuracy or integrity of any part of the work are appropriately investigated and resolved

Radhea Miraz Bagaskoro – Acquisition of data, Drafting the work, Revising the work critically for important intellectual content, Final approval of the version to be published, Agree to be accountable for all aspects of the work in ensuring that questions related to the accuracy or integrity of any part of the work are appropriately investigated and resolved

Nugira Dinantia – Acquisition of data, Drafting the work, Revising the work critically for important intellectual content, Final approval of the version to be published, Agree to be accountable for all aspects of the work in ensuring that questions related to the accuracy or integrity of any part of the work are appropriately investigated and resolved

Mardiah Suci Hardianti - Conception of the work, Design of the work, Analysis of data, Interpretation of

data, Drafting the work, Revising the work critically for important intellectual content, Final approval of the version to be published, Agree to be accountable for all aspects of the work in ensuring that questions related to the accuracy or integrity of any part of the work are appropriately investigated and resolved

Guarantor of Submission

The corresponding author is the guarantor of submission.

Source of Support

None.

Consent Statement

Written informed consent was obtained from the patient for publication of this article.

Conflict of Interest

Authors declare no conflict of interest.

Data Availability

All relevant data are within the paper and its Supporting Information files.

Copyright

© 2022 Dian Pratiwi Meliala et al. This article is distributed under the terms of Creative Commons Attribution License which permits unrestricted use, distribution and reproduction in any medium provided the original author(s) and original publisher are properly credited. Please see the copyright policy on the journal website for more information.

Access full text article on
other devices



Access PDF of article on
other devices





Submit your manuscripts at
www.edoriumjournals.com

