EDORIUM Journals

Int J Case Rep Images 2021;12:101277Z01KR2021.
www.ijcasereportsandimages.com

CASE REPORT PEER REVIEWED | OPEN ACCESS

Massive and unilateral rheumatoid pleural effusion without overt disease

Kamel El-Reshaid, Shaikha Al-Bader

ABSTRACT

Introduction: Rheumatoid arthritis (RA) is an autoimmune disease that manifests as a progressive mutilating arthritis with rare systemic involvement. The prevalence of its pleuropulmonary manifestations hardly exceeds 5% of cases. The reported ones include: pleurisy, interstitial fibrosis, effusion, rheumatoid nodules, and Caplan's syndrome. The latter has been described in association with disease activity or as late complications.

Case Report: We present a patient with progressive and unilateral pleural effusion (PE) due to rheumatoid arthritis (RA) yet without overt systemic manifestations of disease which is exceedingly rare. Diagnosis was suspected by an exudative PE that had low glucose (compared to his serum) and pathognomonic cytology. Subsequently, it was confirmed by high anti-cyclic citrullinated peptide (anti-CCP) antibody. The effusion regressed significantly, 1 month later, after Prednisone and Rituximab therapy.

Conclusion: Rheumatoid arthritis should be considered in patients presenting with exudative PE that lacks history of trauma, and manifestations of infection, malignancy, and autoimmune diseases. High anti-CCP and cytological examination are useful in diagnosis.

Keywords: Lung, Pleural effusion, Rheumatoid arthritis, Rituximab

Kamel El-Reshaid[1], Shaikha Al-Bader[2]

Affiliations: [1]Department of Medicine, Faculty of Medicine, Kuwait University, Safat, Kuwait; [2]Department of Medicine, Nephrology Unit, Amiri Hospital, Ministry of Health, Kuwait, Kuwait.

Corresponding Author: Dr. Kamel El-Reshaid, Professor, Department of Medicine, Faculty of Medicine, Kuwait University, P O Box 24923, 13110 Safat, Kuwait; Email: kamel@hsc.edu.kw

Received: 29 September 2021
Accepted: 30 November 2021
Published: 27 December 2021

How to cite this article

El-Reshaid K, Al-Bader S. Massive and unilateral rheumatoid pleural effusion without overt disease. Int J Case Rep Images 2021;12:101277Z01KR2021.

Article ID: 101277Z01KR2021

****

doi: 10.5348/101277Z01KR2021CR

INTRODUCTION

A pleural effusion (PE) is accumulation of excessive fluid in the pleural space that surrounds each lung. Under normal conditions, pleural fluid is secreted by the parietal pleural capillaries at a rate of 0.01 mL/kg weight per hour, and is cleared by lymphatic absorption leaving behind only 5–15 mL of fluid, which helps maintaining a functional vacuum between the parietal and visceral pleurae. Excess fluid within the pleural space can impair inspiration by upsetting the functional vacuum and hydrostatically increasing the resistance against lung expansion, resulting in a fully or partially collapsed lung [1]. Various types of fluid can accumulate in the pleural space, viz., serous (hydrothorax), blood (hemothorax), pus (pyothorax or empyema), chyle (chylothorax), and urine (urinothorax). Excessive PE results from two pathophysiological derangements; (a) transudates due to excessive production, reduced resorption and decrease oncotic pressure as in congestive heart failure, renal failure, liver cirrhosis, nephrotic syndrome, and Meig's syndrome while (b) exudative ones result from pleural damage by trauma, infection, malignancy, and autoimmune diseases [2]. In the United States, the incidence of PE is estimated to be at least 1.5 million cases annually and the industrialized countries the prevalence of is 320 cases per 100,000 people [3]. Most of these cases are caused by congestive heart failure, bacterial pneumonia, malignancy, and pulmonary embolism. In our case report, we present a patient with progressive

and unilateral PE due to rheumatoid arthritis (RA) yet without systemic manifestations of disease which is exceedingly rare.

CASE REPORT

A 70-year-old man presented with shortness of breath for two weeks. He denied fever, chest and abdominal pain, skin rash, and joint pains. Past history was significant for type II diabetes mellitus (DM) for 10 years that had disappeared after progressive worsening of his renal function with edema and hypertension in the past three years. Lately, he was started on hemodialysis and kidney biopsy had confirmed that he had advanced nodular glomerulosclerosis. On his initial physical examination, the patient was conscious, oriented X3, and in distress of shortness of breath. Blood pressure was 120/80 mmHg. He was afebrile with a body weight of 77 kg. He did not have lymphadenopathy, goiter, jugular venous distension, or edema. Systemic examination did not show abnormality except for dull percussion at right lower chest zones. Laboratory investigations showed normal peripheral leukocytic and platelets counts. Hemoglobin was 110 g/L with normal mean corpuscular volume (MCV). Serum urea and creatinine were elevated at 21 mmol/L and 440 umol/L, respectively. Serum glucose was 12 mmol/L. Serum electrolytes and liver functions were normal except for albumin at 28 g/L. Serum lactate dehydrogenase (LDH) was 280 U/L. Serum cholesterol was 6 mmol/L. Thyroid stimulating hormone (TSH) was normal. Urine routine and microscopy showed 3(+) protein without hematuria and pyuria. Serum complements (C3 and C4) and protein electrophoresis were normal. Antinuclear antibody (ANA), anti-ds DNA, antineutrophil cytoplasmic antibody (ANCA), anti-GBM AB, hepatitis B surface antigen, and anti-HCV antibodies were negative. Chest X-ray showed large right-sided pleural effusion without pulmonary infiltrate and lymphadenopathy (Figure 1A). Electrocardiogram (ECG) was normal. Abdominal and pelvic ultrasound was normal except for bilateral normal-sized yet echogenic kidneys and without ascites. Ultrasound examination of the chest confirmed the effusion and allowed its pleural tapping (Figure 2). Its analysis showed pH: 7.4, leukocytic count: 600 cells/mm^3 of which 82% were lymphocytes, LDH 1528 U/L, glucose 6 mmol/L. Pleural fluid and blood cultures for bacteria, fungus, and mycobacteria were negative. Smear of pleural fluid, stained with Giemsa stain, showed spindle and giant multinucleated macrophage (Figure 3). No acid-fast bacilli were seen on Ziehl-Neelsen stain. Real-time polymerase chain reaction (PCR) for mycobacteria tuberculosis was negative. Based on such data which suggested RA, anti-cyclic citrullinated peptide antibody was done. The results were very high (280 EU/mL. Normal < 20) which further confirmed the diagnosis of PE associated with RA. Moreover, kidney biopsy was done and showed diffuse nodular glomerulosclerosis without granulomatous interstitial nephritis. Ancillary stains were negative for Congo-red and immune deposits. After establishment of final diagnosis; the patient was treated with Prednisone 60 mg daily and the effusion has decreased dramatically one month later (Figure 1B). To avoid long-term steroid side effects on his DM and bones; he was treated also with Rituximab 1 g followed by 1 g two weeks later and Prednisone was tapered down and

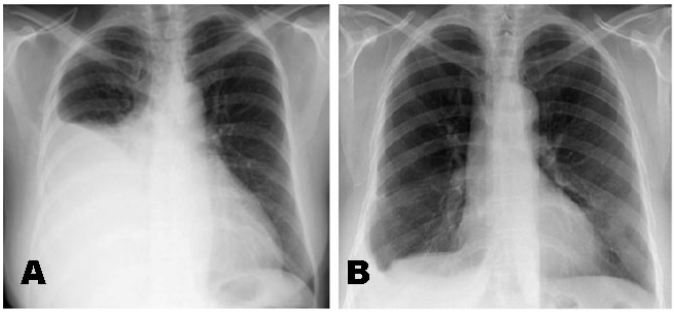

Figure 1: AP chest X-ray of a patient with rheumatoid arthritis showing large right-sided pleural effusion at presentation (A) and one month after treatment with Prednisone and Rituximab (B).

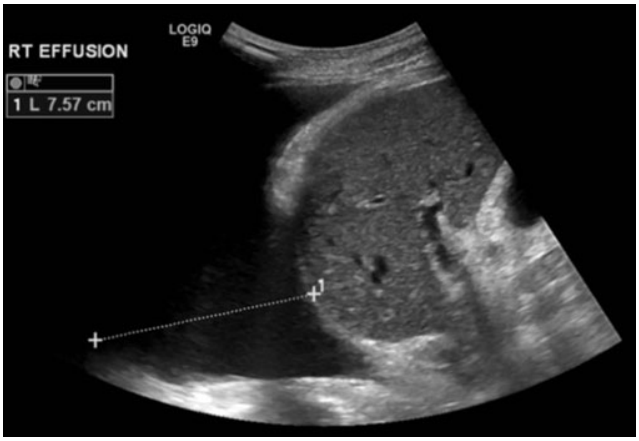

Figure 2: Lateral transthoracic ultrasound view showing a large right-sided pleural effusion (measurement line).

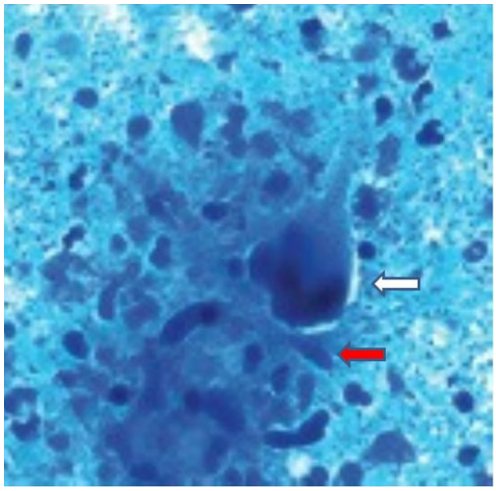

Figure 3: Photomicrograph of smear of pleural fluid showing spindle (red arrow) and multinucleated (white arrow) giant cells (Giemsa, ×400).

discontinued after two months. Up to one year of follow-up; the patient did not manifest active RA or recurrence of his PE.

DISCUSSION

Rheumatoid arthritis (RA) is an autoimmune disease that manifests as a progressive mutilating arthritis with a worldwide prevalence at 0.24% [4]. Its extra-articular manifestations are rare [5]. Pleuropulmonary manifestations of RA without primary articular symptoms are exceedingly rare and therefore pose difficult problems in differential diagnosis [6]. In our elderly and diabetic patient with severe renal disease the list of differential diagnosis is huge yet the algorithm plan had narrowed the diagnosis. The initial step was the pleural tap which, based on criteria, has confirmed its exudative nature and ruled out fluid overload or hypoalbuminemia associated with his diabetic renal disease [7]. Lack of significant pyothorax and culture ruled out parapnemonic etiology. Moreover, lack of lung infiltrates, lymphadenopathy, and negative PE polymerase chain reaction (PCR) test for mycobacteria excluded tuberculosis [8]. Moreover, his kidney biopsy showed diabetic glomerulosclerosis without evidence of interstitial granulomatous tuberculous involvement. Autoimmune workup had ruled out systemic diseases such as systemic lupus erythematosis and vasculitis. Patients with severe renal disease can develop uremic pleuropericarditis and subsequent effusions yet the modest level of his renal disease was against such complication. In our patient, the low PE glucose compared to plasma and its cytopathological findings were suggestive of RA [9]. Finally, the high level of anti-CCP consolidated the diagnosis. The latter test has a sensitivity of 61.6–75.2% for rheumatoid arthritis and specificity of 94–99% [10]. In difficult cases; thoracoscopic pleural biopsy may assist in diagnosis and exclusion of other etiologies [11].

CONCLUSION

Rheumatoid arthritis should be considered in patients presenting with exudative PE that lacks history of trauma, and manifestations of infection, malignancy, and autoimmune diseases. High anti-CCP and cytological examination are useful in diagnosis.

REFERENCES

1. Noppen M. Normal volume and cellular contents of pleural fluid. Curr Opin Pulm Med 2001;7(4):180–2.
2. Diaz-Guzman E, Dweik RA. Diagnosis and management of pleural effusions: A practical approach. Compr Ther 2007;33(4):237–46.
3. Sahn SA. The value of pleural fluid analysis. Am J Med Sci 2008;335(1):7–15.
4. Cross M, Smith E, Hoy D, et al. The global burden of rheumatoid arthritis: Estimates from the global burden of disease 2010 study. Ann Rheum Dis 2014;73(7):1316–22.
5. Young A, Koduri G. Extra-articular manifestations and complications of rheumatoid arthritis. Best Pract Res Clin Rheumatol 2007;21(5):907–27.
6. Shaw M, Collins BF, Ho LA, Raghu G. Rheumatoid arthritis-associated lung disease. Eur Respir Rev 2015;24(135):1–16.
7. Light RW. Clinical practice. Pleural effusion. N Engl J Med 2002;346(25):1971–7.
8. Trajman A, Kaisermann MC, Luiz RR, et al. Pleural fluid ADA, IgA-ELISA and PCR sensitivities for the diagnosis of pleural tuberculosis. Scand J Clin Lab Invest 207;67(8):877–84.
9. Rodríguez-Zarco E, Vallejo-Benítez A, Otal-Salaverri C. Pleural effusion associate with rheumatoid arthritis: Diagnostic clues. J Cytol 2019;36(4):222–3.
10. van Venrooij WJ, van Beers JJBC, Pruijn GJM. Anti-CCP antibodies: The past, the present and the future. Nat Rev Rheumatol 2011;7(7):391–8.
11. Faurschou P, Francis D, Faarup P. Thoracoscopic, histological, and clinical findings in nine cases of rheumatoid pleural effusion. Thorax 1985;40(5):371–5.

****

Author Contributions

Kamel El-Reshaid – Conception of the work, Design of the work, Acquisition of data, Analysis of data, Interpretation of data, Drafting the work, Revising the work critically for important intellectual content, Final approval of the version to be published, Agree to be accountable for all aspects of the work in ensuring that questions related to the accuracy or integrity of any part of the work are appropriately investigated and resolved

Shaikha Al-Bader – Conception of the work, Design of the work, Acquisition of data, Analysis of data, Interpretation of data, Drafting the work, Revising the work critically for important intellectual content, Final approval of the version to be published, Agree to be accountable for all aspects of the work in ensuring that questions related to the accuracy or integrity of any part of the work are appropriately investigated and resolved

Guarantor of Submission

The corresponding author is the guarantor of submission.

Source of Support

None.

Consent Statement

Written informed consent was obtained from the patient for publication of this article.

Conflict of Interest

Authors declare no conflict of interest.

Data Availability

All relevant data are within the paper and its Supporting Information files.