

# Intestinal intussusception and obstruction due to entrapped Ascaris

Fallou Galass Niang, Abdourahmane Ndong, Afef Attia, Imane Draidry, Abdoulaye Ndoye DIOP

## ABSTRACT

**Introduction:** Intussusception is idiopathic in over 90% of cases. The main causes exceptionally found are Merkel's diverticulum, polyps, and lymphomas. We report a case of ileo-ileal intussusception due to entrapped Ascaris.

**Case Report:** A 3-year-old child referred to the emergency department for vomiting, diffuse abdominal pain, and cessation of passage of flatus and feces evolving for 24 hours. Ultrasound showed in the right peri-umbilical region a sandwich like bowel mass compatible with an intestinal intussusception. There were multiple "bull's eye" and "railway track" images suggestive of intestinal ascariasis in the mass and beside it. Surgical intervention by laparotomy found an ileo-ileal intussusception with impacted Ascaris. An enterotomy was performed and worms were removed. Medical treatment with albendazole was administrated after restart of intestinal transit.

**Conclusion:** Through this case we illustrate a rare cause of intestinal intussusception and the interest of ultrasound in diagnosis by a correlation with surgery.

**Keywords:** Ascaris, Intussusception, Roundworm, Sonography

## How to cite this article

Niang FG, Ndong A, Attia A, Draidry I, DIOP AN. Intestinal intussusception and obstruction due to entrapped Ascaris. Int J Case Rep Images 2021;12:101199Z01FN2021.

Article ID: 101199Z01FN2021

\*\*\*\*\*

doi: 10.5348/101199Z01FN2021CR

## INTRODUCTION

Ascariasis is an infection caused by a giant roundworm named *Ascaris lumbricoides* which is the most common intestinal nematode affecting human beings. It is endemic in underdeveloped areas and particularly affects children [1]. Infestation could be silent or may lead to serious complications like intestinal obstruction, volvulus, and intussusception [2]. Intestinal intussusception is idiopathic in over 90% of cases. Uncommon etiologies such as Merkel's diverticulum, polyp, lymphoma, and parasitosis are found in 6–8% of cases [3]. We report a case of small bowel obstruction by acute intussusception due to impacted Ascaris in a 3-year-old child.

## CASE REPORT

A 3-year-old child referred to the emergency department for vomiting, diffuse abdominal pain, and cessation of passage of flatus and feces. The clinical symptoms had progressed for approximately 24 hours. On physical examination vitals were stable, abdomen was distended without any palpable mass. Mild eosinophilia (12.6%) was reported. Ultrasound showed in the right peri-umbilical region a dilated bowel loops with a doughnut like bowel mass in transverse section (Figure 1A) and

Fallou Galass Niang<sup>1</sup>, Abdourahmane Ndong<sup>2</sup>, Afef Attia<sup>3</sup>, Imane Draidry<sup>3</sup>, Abdoulaye Ndoye DIOP<sup>1</sup>

**Affiliations:** <sup>1</sup>Department of Radiology, CHRSL, Gaston Berger University, Saint-Louis, Senegal; <sup>2</sup>Department of Surgery, CHRSL, Gaston Berger University, Saint-Louis, Senegal; <sup>3</sup>Department of Radiology, CHRSL, Saint-Louis, Senegal.

**Corresponding Author:** Fallou Galass Niang, Department of Radiology, Saint-Louis Hospital, Saint-Louis, Senegal; Email: niang.fallou-galass@ugb.edu.sn

Received: 12 October 2020

Accepted: 08 January 2021

Published: 04 March 2021

sandwich like bowel mass in longitudinal section (Figure 1B) compatible with an intestinal intussusception. There were multiple “bull's eye” and “railway track” images (Figure 1A and B) suggestive of intestinal ascariasis in the mass and beside it. Surgical intervention by laparotomy found an ileo-ileal intussusception with impacted *Ascaris* without sign of necrosis or intestinal perforation (Figure 2). Intussusception relief was done followed by an enterotomy for the evacuation of most roundworms and leaving the rest to medical treatment with albendazole. The patient was discharged 5th day postoperatively without complication.

## DISCUSSION

Intussusception most often affects children between 6 months and 3 years old and is rare over the age of 6 [4]. In the majority of cases (more than 90%) no cause is found. Exceptionally, an underlying condition, constituting a lead point for intussusception, is found in 6–8% of cases [3]. The most commonly encountered lead points are Merkel's diverticulum, polyps, lymphomas, vascular malformations, worms, and Henoch–Schönlein's purpura [3, 5]. Ascariasis is the most common helminthiasis in humans. It can occur at any age but most often in preschool

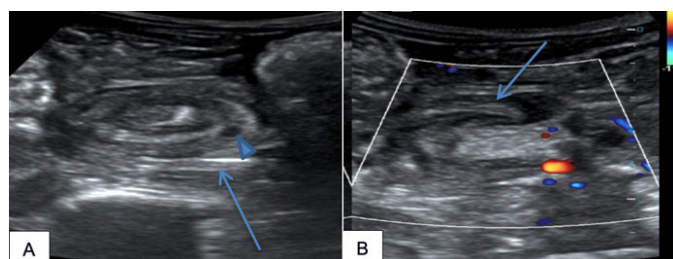


Figure 1: Ultrasound showing a bowel mass with several images of “bull's eye” (blue arrowhead) and “railway track” (blue arrow) suggestive of intestinal ascariasis. (A) Transverse section showing a bowel mass like a doughnut. (B) Longitudinal scan showing a bowel mass like a sandwich.

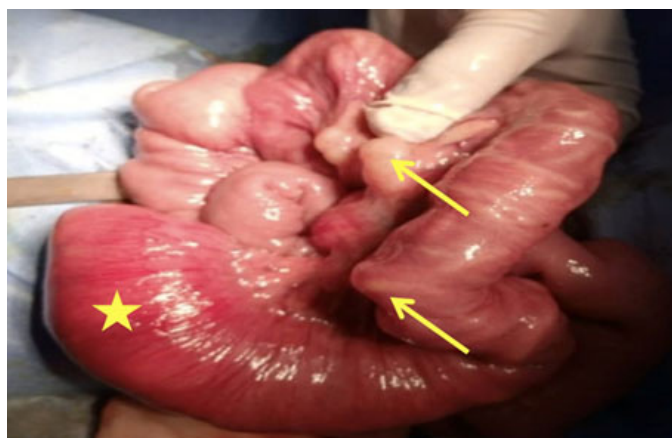

Figure 2: Per-operative images showing an ileo-ileal intussusception (yellow star) with the relief of round worms through the wall (yellow arrows).

children. The clinical and biological manifestations are not specific. The most serious complications of this parasitosis are intestinal obstruction and perforation. Partial occlusion often resolves on its own with medical treatment. On the other hand, when the mechanical obstacle persists, the roundworm bolus acts as a fixed point and leads to intussusception and volvulus [6].

Ultrasound is a simple and reliable method for both positive and etiological diagnosis of intussusception with high sensitivity (98–100%) and specificity (88–100%) [7]. Indeed, it often shows a typical appearance of intussusceptions in the form of a target or doughnut sign in transverse section in which hypo-echoic outer ring corresponding to the wall of the recipient intestinal segment and a central hyperechoic zone corresponding to the interfaces of the invaginated segment. In longitudinal section, sandwich sign, hayfork sign, pseudokidney sign can be seen. Three parallel hypo-echoic bands with interposing two hyper-echoic band give sandwich sign [7]. Hayfork sign is a variant of sandwich sign seen at apex where three hypo-echoic bands go to join. Pseudokidney sign seen in oblique scan or curved intussusceptions in which hyper-echoic mesentery is seen on only one side of central limb of intussusceptum [8]. Ultrasound can also help visualize roundworms. They appear as a double echogenic tubular structure (“railway track”) in longitudinal section and as a target in transverse section (“bull's eye”) [9, 10]. These tubular structures can be mobile, making the diagnosis easier [9] as shown in our example.

Treatment of bowel obstruction by roundworm is usually surgical, but in the absence of signs of peritonitis, medical treatment may give good results, even with complete obstruction [11, 12]. In our patient, the management was surgical and consisted of an intussusception relief followed by an enterotomy for the evacuation of the round worm. All roundworms could not be milked to the colon because of the extension of the infestation, reason why an ileum enterotomy was done. The post-operative course was uneventful. Medical treatment with albendazole was started after the resumption of intestinal transit.

## CONCLUSION

This case illustrates a rare cause of intussusception and intestinal obstruction in children. Ultrasound remains the best imaging modality for the management of pediatric abdominal emergency. It plays a key role for positive and etiological diagnosis of intestinal intussusception.

## REFERENCES

1. Crompton DW. *Ascaris* and ascariasis. *Adv Parasitol* 2001;48:285–375.

2. Galiano Gil J, Leyva Esturo C, Peña Ayala R. Intestinal obstruction due to ascaris. *The Internet Journal of Surgery* 2005;8(2):16.
3. Blakelock RT, Beasley SW. The clinical implications of non-idiopathic intussusception. *Pediatr Surg Int* 1998;14(3):63-7.
4. Navarro O, Daneman A. Intussusception. Part 3: Diagnosis and management of those with an identifiable or predisposing cause and those that reduce spontaneously. *Pediatr Radiol* 2004;34(4):305-12.
5. Yetim I, Ozkan OV, Semerci E, Abanoz R. Rare cause of intestinal obstruction, *Ascaris lumbricoides* infestation: Two case reports. *Cases J* 2009;2:7970.
6. Rode H, Cullis S, Millar A, Cremin B, Cywes S. Abdominal complications of *ascaris lumbricoides* in children. *Pediatr Surg Int* 1990;5:397-401.
7. Titare PU, Sonawane BD, Rathod PB, Tembhekar NG. Intussusception due to entrapped ascaris: An ultrasound case report. *J Evolution Med Dent Sci* 2014;56(3):12848-52.
8. del-Pozo G, Albillos JC, Tejedor D, et al. Intussusception in children: Current concepts in diagnosis and enema reduction. *Radiographics* 1999;19(2):299-319.
9. Chawla A, Patwardhan V, Maheshwari M, Wasnik A. Primary ascaridial perforation of the small intestine: Sonographic diagnosis. *J Clin Ultrasound* 2003;31(4):211-3.
10. Mehta V, Goyal S, Pandit S, Mittal A, Aggarwal A. Sonographic diagnosis of *Ascaris lumbricoides* infestation as a cause of intestinal obstruction. *Indian J Pediatr* 2010;77(7):827.
11. Peck RJ. Ultrasonography of intestinal ascaris. *J Clin Ultrasound* 1990;18(9):741-3.
12. Diouf C, Kane A, Ndoeye NA, et al. Volvulus of the small bowel due to *ascaris lumbricoides* package: About a case. [Article in French]. *Pan Afr Med J* 2016;24:208.

\*\*\*\*\*

### Author Contributions

Fallou Galass Niang – Conception of the work, Design of the work, Acquisition of data, Analysis of data, Interpretation of data, Drafting the work, Final approval of the version to be published, Agree to be accountable for all aspects of the work in ensuring that questions related to the accuracy or integrity of any part of the work are appropriately investigated and resolved

Abdourahmane Ndong – Analysis of data, Revising the work critically for important intellectual content, Final approval of the version to be published, Agree to be accountable for all aspects of the work in ensuring that

questions related to the accuracy or integrity of any part of the work are appropriately investigated and resolved

Afef Attia – Acquisition of data, Interpretation of data, Drafting the work, Final approval of the version to be published, Agree to be accountable for all aspects of the work in ensuring that questions related to the accuracy or integrity of any part of the work are appropriately investigated and resolved

Imane Draidry – Acquisition of data, Interpretation of data, Drafting the work, Final approval of the version to be published, Agree to be accountable for all aspects of the work in ensuring that questions related to the accuracy or integrity of any part of the work are appropriately investigated and resolved

Abdoulaye Ndoeye DIOP – Analysis of data, Interpretation of data, Revising the work critically for important intellectual content, Final approval of the version to be published, Agree to be accountable for all aspects of the work in ensuring that questions related to the accuracy or integrity of any part of the work are appropriately investigated and resolved

### Guarantor of Submission

The corresponding author is the guarantor of submission.

### Source of Support

None.

### Consent Statement

Written informed consent was obtained from the patient for publication of this article.

### Conflict of Interest

Authors declare no conflict of interest.

### Data Availability

All relevant data are within the paper and its Supporting Information files.

### Copyright

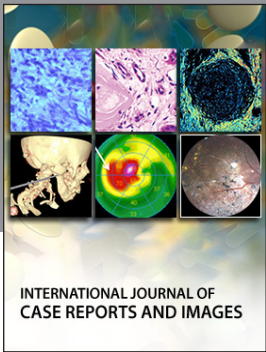
© 2021 Fallou Galass Niang et al. This article is distributed under the terms of Creative Commons Attribution License which permits unrestricted use, distribution and reproduction in any medium provided the original author(s) and original publisher are properly credited. Please see the copyright policy on the journal website for more information.

Access full text article on  
other devices



Access PDF of article on  
other devices





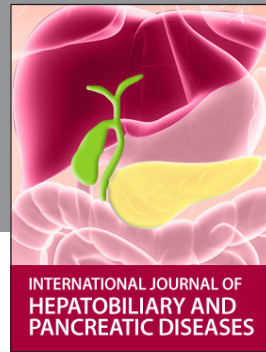INTERNATIONAL JOURNAL OF CASE REPORTS AND IMAGES



VIDEO JOURNAL OF CLINICAL RESEARCH



VIDEO JOURNAL OF BIOMEDICAL SCIENCE



INTERNATIONAL JOURNAL OF HEPATOBILIARY AND PANCREATIC DISEASES



INTERNATIONAL JOURNAL OF BLOOD TRANSFUSION AND IMMUNOHEMATOLOGY



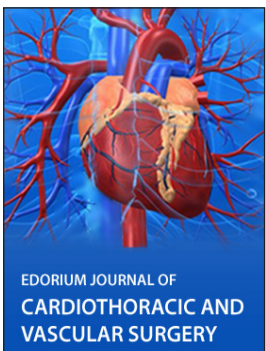EDORIUM JOURNAL OF OPHTHALMOLOGY



**Submit your manuscripts at**  
[www.edoriumjournals.com](http://www.edoriumjournals.com)




EDORIUM JOURNAL OF MEDICINE



EDORIUM JOURNAL OF CARDIOTHORACIC AND VASCULAR SURGERY



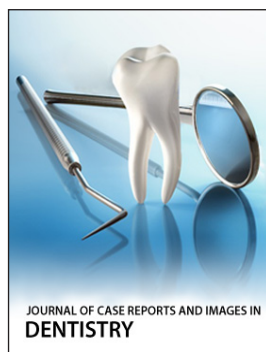
JOURNAL OF CASE REPORTS AND IMAGES IN ORTHOPEDICS AND RHEUMATOLOGY



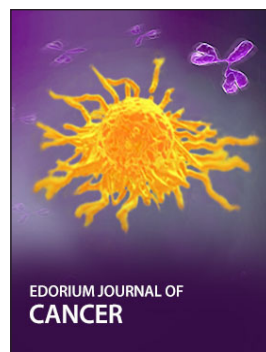EDORIUM JOURNAL OF PSYCHOLOGY




EDORIUM JOURNAL OF CELL BIOLOGY



JOURNAL OF CASE REPORTS AND IMAGES IN DENTISTRY



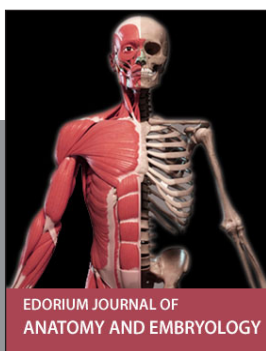EDORIUM JOURNAL OF CANCER



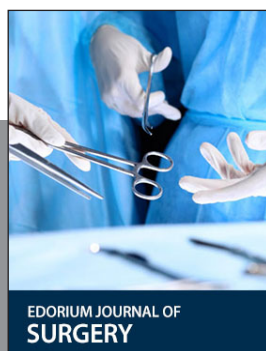EDORIUM JOURNAL OF PSYCHIATRY



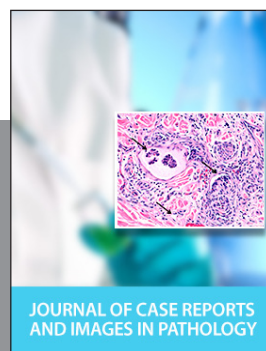
JOURNAL OF CASE REPORTS AND IMAGES IN INFECTIOUS DISEASES



EDORIUM JOURNAL OF ANATOMY AND EMBRYOLOGY



EDORIUM JOURNAL OF SURGERY



JOURNAL OF CASE REPORTS AND IMAGES IN PATHOLOGY



EDORIUM JOURNAL OF ANESTHESIA