

## CASE REPORT

## PEER REVIEWED | OPEN ACCESS

## Angiographic infundibular dilation: Is it worth exploring?

Pedro Nogarotto Cembraneli, Italo Nogarotto Cembraneli,  
Renata Brasileiro de Faria Cavalcante, Volmer Fernandes Valente Junior,  
José Edison da Silva Cavalcante, Rherold Santana,  
Julia Brasileiro de Faria Cavalcante

## ABSTRACT

**Introduction:** Infundibular dilations are generally considered normal anatomical variants devoid of pathogenic significance. However, some of them change in time and show certain characteristics similar to saccular aneurysms.

**Case Report:** A 40-year-old male patient was hospitalized due to subarachnoid hemorrhage, resulting from the rupture of an aneurysm at the level of the anterior communicating artery. Additionally, an infundibular dilation of 6 mm in diameter was detected at the level of the right posterior communicating artery. The patient underwent an open surgery, using the pterional craniotomy approach to the right. The aneurysm of the anterior communicating artery was clipped with some difficulty because previous

hemorrhage and hematoma were covering the aneurysmal neck. A mini clip was used to laterally decrease the infundibular dilation. Upon releasing the clip, we evidenced not an infundibulum, but a typical aneurysm, with the posterior communicating artery well attached to its wall, which was released and exposed at the time of clipping.

**Conclusion:** Infundibular dilation is a potential source of bleeding, but it rarely ruptures and is little valued by radiologists and neurosurgeons. The care inherent in the discovery of an infundibular aneurysm, even if it is insidious, must be the same as that applied to classical types of aneurysm. Moreover, the therapeutic approach should be chosen when the infundibular aneurysm is equal to or greater than 4 mm in diameter.

**Keywords:** Aneurysm, Angiographic findings, Angiography, Infundibular dilation

Pedro Nogarotto Cembraneli<sup>1</sup>, Italo Nogarotto Cembraneli<sup>2</sup>, Renata Brasileiro de Faria Cavalcante<sup>3</sup>, Volmer Fernandes Valente Junior<sup>3</sup>, José Edison da Silva Cavalcante<sup>4</sup>, Rherold Santana<sup>5</sup>, Julia Brasileiro de Faria Cavalcante<sup>1</sup>

**Affiliations:** <sup>1</sup>MD, Santa Mônica Hospital, Aparecida de Goiânia, GO, Brazil; <sup>2</sup>Medical Sciences Course, Health Sciences School, Faculdade Ceres (FACERES), São José do Rio Preto, SP, Brazil; <sup>3</sup>MD, Neurosurgeon, Member of the Brazilian Society of Neurosurgery (SBN), Santa Monica Hospital, Aparecida de Goiânia – GO, Brazil; <sup>4</sup>MD, PhD in Neurosurgery, Neurosurgeon, Member of the Brazilian Society of Neurosurgery (SBN), Head of the Neurosurgery Medical Residency Service, Santa Monica Hospital, Aparecida de Goiânia – GO, Brazil; <sup>5</sup>MD, Resident in Neurosurgery at Santa Mônica Hospital, Aparecida de Goiânia, GO, Brazil.

**Corresponding Author:** Pedro Nogarotto Cembraneli, Santa Mônica Hospital, Chácara Aurora, BR-153, km 8,5 Vila Sul, Aparecida de Goiânia, GO, Brazil; Email: pedrocembraneli@hotmail.com

Received: 11 August 2020  
Accepted: 27 October 2020  
Published: 18 December 2020

## How to cite this article

Cembraneli PN, Cembraneli IN, Cavalcante RBF, Valente VF, Cavalcante JES, Santana R, Cavalcante JBF. Angiographic infundibular dilation: Is it worth exploring? Int J Case Rep Images 2020;11:101182Z01PC2020.

Article ID: 101182Z01PC2020

\*\*\*\*\*

doi: 10.5348/101182Z01PC2020CR

## INTRODUCTION

The posterior communicating arteries originate from the cerebral part of the internal carotid arteries on both sides, mainly due to the posterolateral or posterior aspect, and after a course of approximately 12 mm it

joins the posterior cerebral artery in the interpeduncular cistern [1–3]. The posterior communicating arteries may present conical, triangular, or funnel-shaped infundibular dilations, which are considered normal anatomical variants devoid of pathogenic significance. Nonetheless, some of them change in time and show certain characteristics that are similar to saccular aneurysms [3, 4].

Although they rarely rupture, infundibular dilations are a potential source of bleeding, and therefore are little valued by radiologists and neurosurgeons. Radiological control is usually disregarded even by the patients. Consequently, they are often only diagnosed in the presence of subarachnoid hemorrhage, when they rupture [5–7].

## CASE REPORT

A 40-year-old male patient, with no previous diseases, was hospitalized due to subarachnoid hemorrhage, resulting from the rupture of an aneurysm at the level of the anterior communicating artery, diagnosed through conventional cerebral angiography, by catheterization (Figure 1). In addition to this aneurysm, an infundibular dilation of 6 mm in diameter was detected at the level of the right posterior communicating artery (Figures 2 and 3). The radiologist suggested that it was a simple infundibular dilation, and the main focus of the radiological interpretation was to assess the characteristics of the anterior communicating artery aneurysm that had caused the subarachnoid hemorrhage.

Our team decided for an open surgery, using the pterional craniotomy approach to the right. The aneurysm of the anterior communicating artery was clipped with some difficulty, since previous hemorrhage and hematoma were covering the aneurysmal neck.

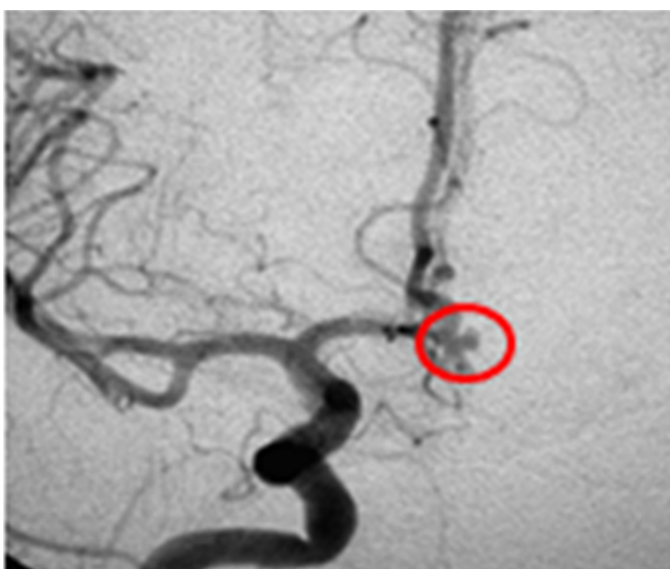

Figure 1: Saccular aneurysm of the anterior communicating artery.

Immediately after, we explored the referred infundibular dilation. At first, the image observed in the microscope was really very typical of a dilation in the emergence of the posterior communicating artery, triangle-shaped and with an enlarged base, as it can be seen in the angiography (Figure 4).

We chose to use a mini clip to laterally decrease the infundibular dilation. Upon releasing the clip, we evidenced not an infundibulum, but a typical aneurysm, with the posterior communicating artery well attached to its wall, which was released and exposed at the time of this clipping (Figure 5).

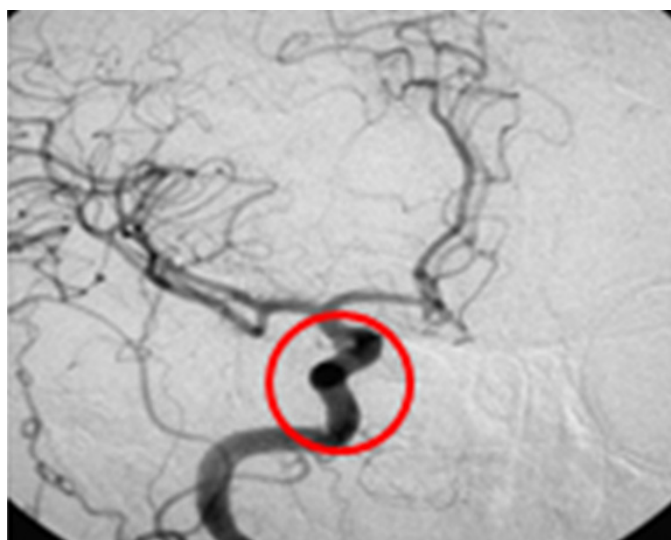


Figure 2: Infundibular dilation at the level of the posterior communicating artery.

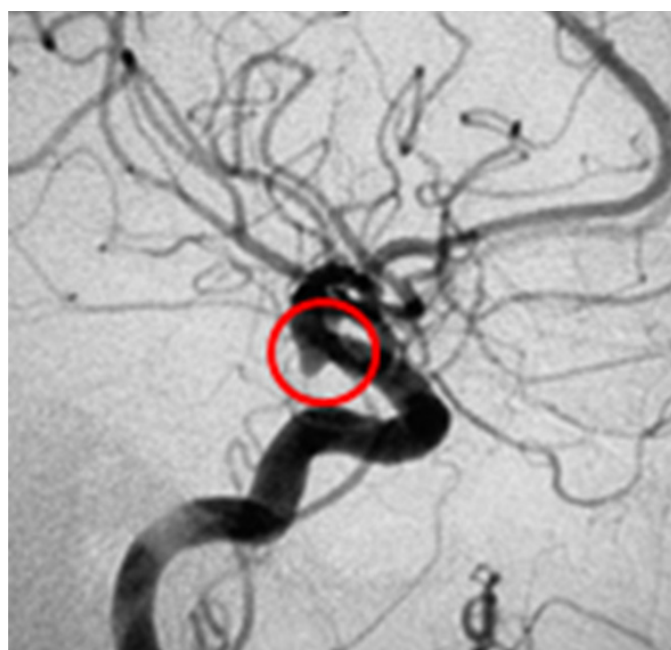


Figure 3: Typical conical infundibular dilation.

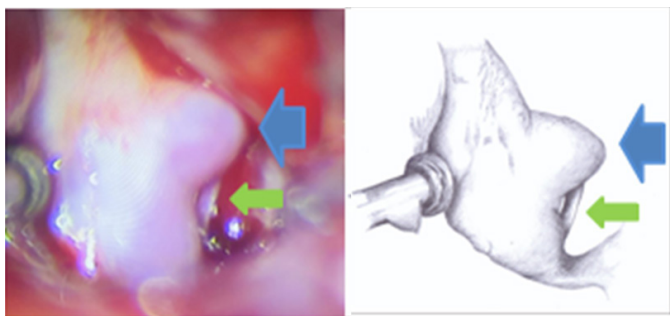


Figure 4: Surgical aspect of infundibular dilation (blue arrow) and posterior communicating artery (green arrow).

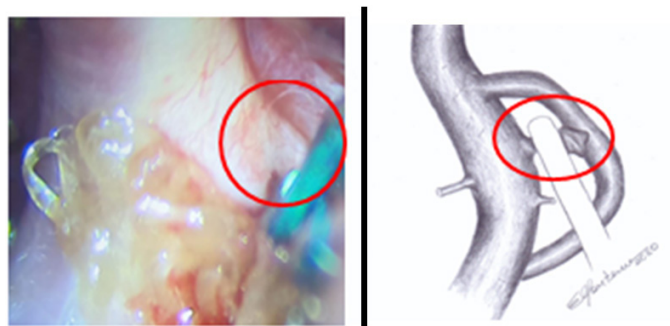


Figure 5: Individualization of the posterior communicating artery and clipped aneurysm.

## DISCUSSION

The reported incidence of infundibular dilation of the posterior communicating artery detected by angiography varies from 6% to 17% and increases with age. The dilation is approximately triangle-shaped and its diameter does not exceed 3 mm [8, 9].

The exact and natural history of infundibular dilation is still controversial [6, 10]. Radiological images not always clarify the real shape of this dilation, or reveal hidden or adherent vessels on its surface, hence the difficulty of indicating surgery without a precise diagnosis [8, 11, 12].

The differential diagnosis between an infundibular dilation and a small aneurysm is not always easy, even with conventional service techniques. Given that dilations are considered benign, the most sophisticated radiological techniques are not used. Sometimes, the structure of the service does not allow the purchase of more sophisticated devices [6, 7, 12].

## CONCLUSION

The care inherent in the discovery of an infundibular aneurysm, even if it is insidious, must be the same as that applied to classical types of aneurysm. Systematic follow-ups with imaging exams (angiography, magnetic resonance imaging, tomography) should be performed. Moreover, the therapeutic approach should be chosen when the infundibular aneurysm is equal to or greater than 4 mm in diameter.

## REFERENCES

1. De Aguiar PHP, Zicarelli CAM, Aires R, et al. Posterior communicating artery aneurysms: Technical pitfalls. *Neurosurg Q* 2010;20(2):74–81.
2. Yoshida M, Watanabe M, Kuramoto S. “True” posterior communicating artery aneurysm. *Surg Neurol* 1979;11(5):379–81.
3. Machado ABM. *Neuroanatomia Funcional*. 2ed. São Paulo: Atheneu; 2006.
4. Martins JH. *Neuroanatomia: Texto e Atlas*. 2ed. Porto Alegre: Artes Médicas; 1998.
5. Endo S, Furuichi S, Takaba M, Hirashima Y, Nishijima M, Takaku A. Clinical study of enlarged infundibular dilation of the origin of the posterior communicating artery. *J Neurosurg* 1995;83(3):421–5.
6. Horikoshi T, Akiyama I, Yamagata Z, Nukui H. Retrospective analysis of the prevalence of asymptomatic cerebral aneurysm in 4518 patients undergoing magnetic resonance angiography – when does cerebral aneurysm develop? *Neurol Med Chir (Tokyo)* 2002;42(3):105–13.
7. Pia HW. Discussion of: “Pertuiset B. Intraoperative aneurysmal rupture and reduction by coagulation of the sac.” In: Pia HW, Langmaid C, Zierski J, editors. *Cerebral Aneurysm Advances in Diagnosis and Therapy*. Berlin: Springer-Verlag; 1979. p. 401.
8. Gallo P, de Pádua Bonatelli A. Avaliação prognóstica dos aneurismas intracranianos por estudo do grau clínico, tomografia computadorizada e angiografia cerebral. *Arq Bras Neurocir* 2000;19(2):71–82.
9. VanderArk GD, Kempe LG, Koblina A. Classification of internal carotid aneurysms as a basis for surgical approach. *Neurochirurgia (Stuttg)* 1972;15(3):81–5.
10. Fox JL. *Intracranial Aneurysms*. New York: Springer-Verlag; 1983.
11. Miyazawa N, Akiyama I, Yamagata Z. Risk factors for growth of unruptured intracranial aneurysms: Follow-up study by serial 0.5-T magnetic resonance angiography. *Neurosurgery* 2006;58(6):1047–53.
12. González-Darder JM, Feliu R, Pseudo JV, et al. Surgical management of posterior communicating artery aneurysms based on computed tomographic angiography with three-dimensional reconstruction and without preoperative angiography. [Article in Spanish]. *Neurocirurgia (Astur)* 2003;14(3):207–15.

\*\*\*\*\*

## Author Contributions

Pedro Nogarotto Cembraneli – Conception of the work, Design of the work, Acquisition of data, Analysis of data, Interpretation of data, Drafting the work, Revising the work critically for important intellectual content, Final approval of the version to be published, Agree to be accountable for all aspects of the work in ensuring that questions related to the accuracy or integrity of any part of the work are appropriately investigated and resolved

Italo Nogarotto Cembraneli – Conception of the work, Design of the work, Acquisition of data, Analysis of data, Interpretation of data, Drafting the work, Revising the work critically for important intellectual content, Final



approval of the version to be published, Agree to be accountable for all aspects of the work in ensuring that questions related to the accuracy or integrity of any part of the work are appropriately investigated and resolved

Renata Brasileiro de Faria Cavalcante – Conception of the work, Design of the work, Acquisition of data, Analysis of data, Interpretation of data, Drafting the work, Revising the work critically for important intellectual content, Final approval of the version to be published, Agree to be accountable for all aspects of the work in ensuring that questions related to the accuracy or integrity of any part of the work are appropriately investigated and resolved

Volmer Fernandes Valente Junior – Conception of the work, Design of the work, Acquisition of data, Analysis of data, Interpretation of data, Drafting the work, Revising the work critically for important intellectual content, Final approval of the version to be published, Agree to be accountable for all aspects of the work in ensuring that questions related to the accuracy or integrity of any part of the work are appropriately investigated and resolved

José Edison da Silva Cavalcante – Conception of the work, Design of the work, Acquisition of data, Analysis of data, Interpretation of data, Drafting the work, Revising the work critically for important intellectual content, Final approval of the version to be published, Agree to be accountable for all aspects of the work in ensuring that questions related to the accuracy or integrity of any part of the work are appropriately investigated and resolved

Rherold Santana – Conception of the work, Design of the work, Acquisition of data, Analysis of data, Interpretation of data, Drafting the work, Revising the work critically for important intellectual content, Final approval of the version to be published, Agree to be accountable for all aspects of the work in ensuring that questions related to the accuracy or integrity of any part of the work are appropriately investigated and resolved

Julia Brasileiro de Faria Cavalcante – Conception of the work, Design of the work, Acquisition of data, Analysis of data, Interpretation of data, Drafting the work, Revising the work critically for important intellectual content, Final approval of the version to be published, Agree to be accountable for all aspects of the work in ensuring that questions related to the accuracy or integrity of any part of the work are appropriately investigated and resolved

### **Guarantor of Submission**

The corresponding author is the guarantor of submission.

### **Source of Support**

None.

### **Consent Statement**

Written informed consent was obtained from the patient for publication of this article.

### **Conflict of Interest**

Authors declare no conflict of interest.

### **Data Availability**

All relevant data are within the paper and its Supporting Information files.

### **Copyright**

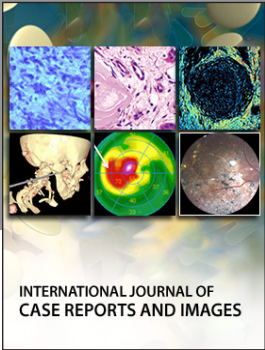
© 2020 Pedro Nogarotto Cembraneli et al. This article is distributed under the terms of Creative Commons Attribution License which permits unrestricted use, distribution and reproduction in any medium provided the original author(s) and original publisher are properly credited. Please see the copyright policy on the journal website for more information.

Access full text article on  
other devices



Access PDF of article on  
other devices





Submit your manuscripts at  
[www.edoriumjournals.com](http://www.edoriumjournals.com)

