

Heterotopic ossification at the level of a laparotomy scar

Suzanne Rita Aubin Igombe, Wais Amarkak Abdillahi,
Ghita El Adioui, Rachida Latib

CASE REPORT

We report the cases of two patients referred to our radiology department for a thoracoabdominal computed tomography (CT) scan as part of their routine postoperative follow-up as both the patients were asymptomatic.

The first patient is a 60-year-old female who underwent a laparotomy for gastric gastrointestinal stromal tumor (GIST) 11 months ago, and checked into our radiology department for a thoracoabdominal CT scan as part of her follow-up assessment. The patient had no complaints.

The CT scan revealed a 7 cm long vertical linear calcified lesion in the anterior abdominal wall at the anterior aspect of the xiphoid process corresponding to a heterotopic ossification of the laparotomy scar (Figure 1).

The second patient is a 33-year-old male who had undergone laparotomy for total gastrectomy one month earlier due to a gastric adenocarcinoma. The patient was received in our department for his first check-up after surgery and concomitant radiochemotherapy. Furthermore, the patient presented no complaints. The thoracoabdominal CT scan performed revealed a vertical calcified lesion at the level of the laparotomy scar extending about 11 cm from the xiphoid region to about 5 cm above the umbilicus, also corresponding to a heterotopic ossification of the laparotomy scar (Figure 2).

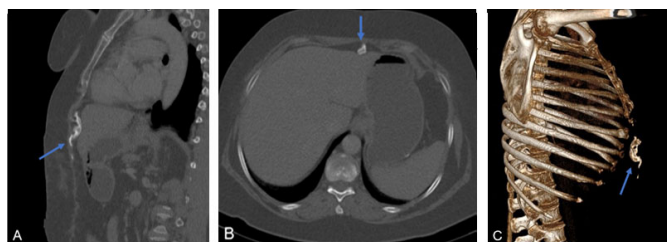


Figure 1: (A) CT scan thoracoabdominal, bone window sagittal. (B) CT scan thoracoabdominal, bone window axial. (C) 3D reconstruction, vertical linear calcified lesion in the anterior abdominal wall in front of the small xiphoid region (blue arrow): heterotopic ossification.

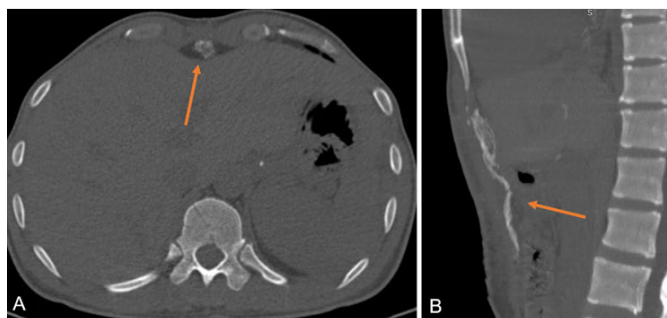


Figure 2: (A) CT scan thoracoabdominal, bone window axial. (B) CT scan thoracoabdominal, bone window sagittal heterotopic ossification at level of laparotomy scar (orange arrow) one month after laparotomy for total gastrectomy after gastric adenocarcinoma.

DISCUSSION

Heterotopic ossification is the formation of bone outside the skeletal system, which can occur in all kinds of soft tissue. It can range from a minimal deposit without clinical sign to a clinically palpable massive deposit.

It is a common complication in patients who had a laparotomy. In a study, Wang et al. found an incidence of heterotopic ossification up to 53% of patients [1].

There is currently no consensus on the etiopathogeny of this affection [2]. However, mainly two theories are discussed [3]: The first one refers to the grafting of particles from the periosteum of the xiphoid process or the pubic symphysis to the operative wound during the surgical procedure leading to bone formation.

Suzanne Rita Aubin Igombe¹, Wais Amarkak Abdillahi¹, Ghita El Adioui¹, Rachida Latib²

Affiliations: ¹MD, Resident in Radiology, Department of Radiology, Oncology National Institute, UHC Ibn Sina, Rabat, Morocco; ²Professor in Radiology, Department of Radiology, Oncology National Institute, UHC Ibn Sina, Rabat, Morocco.

Corresponding Author: Suzanne Rita Aubin Igombe, Imm 156 appartement N°6 Hay El Fath, 10050 Rabat Yacoub El Mansour, Morocco; Email: Sueaubin1986@gmail.com

Received: 22 August 2020

Accepted: 01 October 2020

Published: 29 October 2020

The second one suggests that pluripotent mesenchymal cells can differentiate into osteoblasts in response to local lesion. Generally, ectopic bone formation at the mid-incision scars takes place within a few months and almost always within the first year after surgery [4].

For our second patient, heterotopic ossification was discovered just one month after surgery, which is a surprise according to literature data discussed above, thus, making this report a special one. A phospho-calcic metabolism disorder or an infection of the scar wound could have explained this outcome but the patient developed none of that. So, we found no evident theory which can fully explain this outcome. In addition, Kim et al. [4] also reported in their study a rather short delay of two months in their patients.

High variability in size is found in the literature; however, Wang et al. [1] reported that 42% of patients had developed heterotopic ossification measuring 10 cm in length [1]. In our cases, this measurement was 7 cm and 11 cm.

Both of our patients were asymptomatic, and the discovery was incidental during their follow-up. This is the case for the majority of patients with heterotopic ossification although it can cause chronic abdominal pain or discomfort. Also, it is important to note that heterotopic ossification of the abdominal wall scar wound can potentially perforate the intestinal structures, leading to peritonitis [5, 6].

The main differential diagnoses of this lesion are other postoperative complications, such as abdominal wall infection, foreign body retention, or bone tumor of the xyphoid process.

On imaging, the heterotopic ossification of the laparotomy scar exhibits a typical pattern of calcified linear formation (bone-like density) at the level of the abdominal wall [5, 7].

Despite the benign nature of this condition, a malignant transformation into osteosarcoma has been described in a few cases [6, 8].

The majority of patients with heterotopic ossification are asymptomatic and do not need any treatment. If, however, patients present symptoms, excision of the lesion is recommended [4].

CONCLUSION

Heterotopic ossification at the level of the laparatomic scar is becoming more and more frequent. Radiologically, it appears as a linear bone-like dense structure in the abdominal wall, which occurs within a few months after laparotomy. It is a benign entity which generally does not need any treatment, and this must be known in order to minimize invasive procedures.

Keywords: Computed tomography, Heterotopic ossification, Laparotomy scar

How to cite this article

Aubin Igombe SR, Abdillahi WA, El Adioui G, Latib R. Heterotopic ossification at the level of a laparotomy scar. *Int J Case Rep Images* 2020;11:101172Z01SI2020.

Article ID: 101172Z01SI2020

doi: 10.5348/101172Z01SI2020CI

REFERENCES

1. Wang Y, Stanek A, Grushka J, Fata P, et al. Incidence and factors associated with development of heterotopic ossification after damage control laparotomy. *Injury* 2018;49(1):51–5.
2. Ferreira C, Gomes C, Melo A, et al. Heterotopic mesenteric and abdominal wall ossification – two case reports in one institution. *Int J Surg Case Rep* 2017;37:22–5.
3. Reardon MJ, Tillou A, Mody DR, Reardon PR. Heterotopic calcification in abdominal wounds. *Am J Surg* 1997;173(2):145–7.
4. Kim H. Heterotopic ossification in the abdominal wall after exploratory laparotomy. *J Trauma Inj* 2018;31(3):177–80.
5. Moss JB, Koestner TY, Dart BW. Traumatic bowel perforation from heterotopic ossification. *Am Surg* 2020;3134820945280.
6. Lao VV, Lao OB, Figueredo E. Postoperative bowel perforation due to heterotopic ossification (Myositis ossificans traumatica): A case report and review of the literature. *Case Rep Gastrointest Med* 2011;2011:908514.
7. Koolen PGL, Schreinemacher MHF, Peppelenbosch AG. Heterotopic ossifications in midline abdominal scars: A critical review of the literature. *Eur J Vasc Endovasc Surg* 2010;40(2):155–9.
8. Konishi E, Kusuzaki K, Murata H, Tsuchihashi Y, Beabout JW, Unni KK. Extraskeletal osteosarcoma arising in myositis ossificans. *Skeletal Radiol* 2001;30(1):39–43.

Author Contributions

Suzanne Rita Aubin Igombe – Conception of the work, Design of the work, Acquisition of data, Analysis of data, Interpretation of data, Drafting the work, Revising the work critically for important intellectual content, Final approval of the version to be published, Agree to be accountable for all aspects of the work in ensuring that questions related to the accuracy or integrity of any part of the work are appropriately investigated and resolved

Wais Amarkak Abdillahi – Conception of the work, Design of the work, Acquisition of data, Analysis of data, Interpretation of data, Drafting the work, Final approval of the version to be published, Agree to be accountable for all aspects of the work in ensuring that questions related to the accuracy or integrity of any part of the work are appropriately investigated and resolved

Ghita El Adioui – Conception of the work, Design of the work, Acquisition of data, Analysis of data, Interpretation of data, Drafting the work, Final approval of the version to be published, Agree to be accountable for all aspects of the work in ensuring that questions related to the accuracy or integrity of any part of the work are appropriately investigated and resolved

Rachida Latib – Conception of the work, Design of the work, Acquisition of data, Analysis of data, Interpretation of data, Drafting the work, Revising the work critically for important intellectual content, Final approval of the version to be published, Agree to be accountable for all aspects of the work in ensuring that questions related to the accuracy or integrity of any part of the work are appropriately investigated and resolved

Guarantor of Submission

The corresponding author is the guarantor of submission.

Source of Support

None.

Consent Statement

Written informed consent was obtained from the patient for publication of this article.

Conflict of Interest

Authors declare no conflict of interest.

Data Availability

All relevant data are within the paper and its Supporting Information files.

Copyright

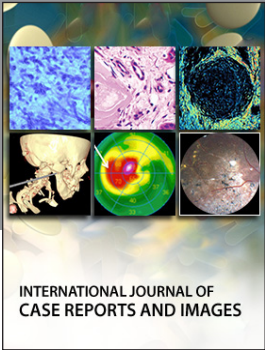
© 2020 Suzanne Rita Aubin Igombe et al. This article is distributed under the terms of Creative Commons Attribution License which permits unrestricted use, distribution and reproduction in any medium provided the original author(s) and original publisher are properly credited. Please see the copyright policy on the journal website for more information.

Access full text article on
other devices



Access PDF of article on
other devices





Submit your manuscripts at
www.edoriumjournals.com

