EDORIUM Journals

Int J Case Rep Images 2020;11:101170Z01AA2020.
www.ijcasereportsandimages.com



CLINICAL IMAGE PEER REVIEWED | OPEN ACCESS

# Cognitive bias in diagnosis in the Covid-19 era

Avinash Aujayeb

## CASE REPORT

A 31-year-old female patient presented with a 3-day history of worsening cough, dyspnoea, and feeling feverish. She was fit and well and took no regular medications. Her oxygen saturation on air was 88%. Her chest radiograph (Figure 1A) showed widespread bilateral interstitial infiltrates. She was swabbed for Covid-19, isolated, started on 2 L of oxygen (which maintained her saturation at 94%) and consented for Covid-19 specific randomized controlled trials. Her white blood cell count including lymphocyte and eosinophil counts was normal, C-reactive protein was 45 mg/L (<5). When the Covid-19 swab came back negative, it was felt that the clinical picture did not fit with Covid-19. A further targeted history revealed increasing breathlessness and cough over the last eight months, with no diurnal variation. She admitted to owning two budgerigars for the last three years. She kept them in living room and regularly cleaned the cages with no respiratory protection. A high-resolution computer tomogram (HRCT) was ordered. Figure 1B shows extensive centrilobular ground glass shadowing with evidence of air trapping and in keeping with a hypersensitivity pneumonitis, also known as extrinsic allergic alveolitis (EAA), presumedly due to her budgerigars.

She was started on 40 mg once daily of prednisolone with marked clinical improvement and was discharged the next day with outpatient follow-up organized. Precipitins for serum budgerigar was positive (+++), budgerigar fecal extract precipitins were positive (++++), and avian antibodies via indirect fluorescent testing were positive at titers of 1/320. The patient has been advised to not have any more contact with the birds.

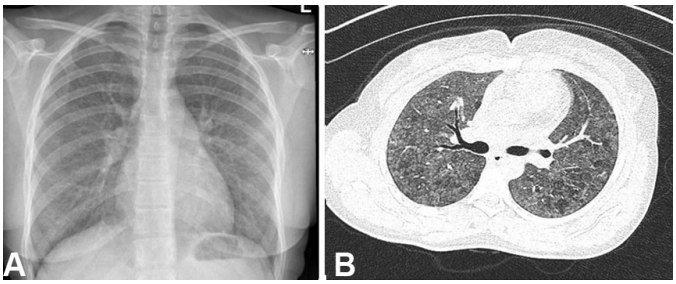


Figure 1: (A) Chest radiograph showing bilateral interstitial shadowing. (B) CT scan showing extensive centrilobular ground glass shadowing with evidence of air trapping and in keeping with a hypersensitivity pneumonitis.

Avinash Aujayeb

Affiliation: Consultant in Acute and Respiratory Medicine, Northumbria HealthCare NHS Foundation Trust, Care of Tracy Groom, Northumbria Way, Cramlington, Northumberland, NE23 6NZ, UK.

Corresponding Author: Dr. Avinash Aujayeb, Consultant in Acute and Respiratory Medicine, Northumbria HealthCare NHS Foundation Trust, Care of Tracy Groom, Northumbria Way, Cramlington, Northumberland, NE23 6NZ, UK; Email: avinash.aujayeb@nhct.nhs.uk

Received: 27 July 2020
Accepted: 02 September 2020
Published: 30 September 2020

## DISCUSSION

Cognitive error is ubiquitous in medicine and can lead to medical errors. Errors in cognition have been identified in all diagnostic steps such information gathering, association triggering, context formulation, processing, and verification. Confirmation bias is a type of cognitive bias where one analyzes information in a way that confirms or strengthens one's prior hypotheses, for example, suspecting that a patient has an infection and a raised white blood cell count proves this [1]. On reflection, this was definitely applied here where it was thought that the patient could only have Covid-19 due to her presenting with respiratory symptoms in the current outbreak. There was also availability bias which is the human tendency to think and judge that the likelihood of an event or frequency of an event is determined by the ease and frequency of examples coming readily to mind [1]. These two biases hampered the initial diagnostic reasoning, which was also helped the next day by the swab being negative. In hindsight, her chest radiograph did not show the classic peripheral consolidatory changes associated with Covid-19.

In the United Kingdom, it is estimated that one million homes have a pet bird. 3.4% of budgie fanciers and 8% of pigeon fanciers develop EAA but EAA due to birds comprises 61% of all cases. Extrinsic allergic alveolitis is an immune-mediated lung disease characterized by

granulomatous inflammation in the distal bronchioles and alveoli of susceptible people. The acute phase causes breathlessness, cough, fevers, malaise, and flu-like symptoms. High-resolution computer tomogram features such as homogenous ground glass opacification, centrilobular nodules, and air trapping causing mosaicism are typical. Treatment comprises of antigen avoidance and steroids in the first instance [2].

At the time of writing, the Covid-19 pandemic is ongoing and second waves are being described across the world [3]. Global cases are just under 23 million with approximately 800,000 deaths recorded. The most common presenting symptoms of Covid-19 are cough and dyspnoea, with the latter being more common in patients admitted to intensive care. Clinical characteristics include bilateral infiltrates with subpleural consolidatory changes, as well as raised inflammatory markers, D-dimer values, and lymphopenia on blood tests. Mortality is increased in males with high body mass indices with comorbidities such as heart disease and diabetes, and in those of black and ethnic minority origin [4, 5].

## CONCLUSION

Physicians need to be aware of any cognitive biases in the Covid-19 era. Extrinsic allergic alveolitis is associated with clear changes on high resolution computed tomography (CT) scan.

*********

**Keywords:** Alveolitis, Cognitive bias, Covid-19

How to cite this article

Aujayeb A. Cognitive bias in diagnosis in the Covid-19 era. Int J Case Rep Images 2020;11:101170Z01AA2020.

Article ID: 101170Z01AA2020

*********

doi: 10.5348/101170Z01AA2020CR

## REFERENCES

1. O'Sullivan ED, Schofield SJ. Cognitive bias in clinical medicine. J R Coll Physicians Edinb 2018;48(3):225–32.
2. https://www.uptodate.com/contents/hypersensitivity-pneumonitis-extrinsic-allergic-alveolitis-clinical-manifestations-and-diagnosis
3. https://coronavirus.jhu.edu/map.html
4. Argenziano MG, Bruce SL, Slater CL, et al. Characterization and clinical course of 1000 patients with coronavirus disease 2019 in New York: Retrospective case series. BMJ 2020;369:m1996.
5. https://www.bsti.org.uk/media/resources/files/BSTI_COVID-19_Radiology_Guidance_version_2_16.03.20.pdf.

*********

### Author Contributions

Avinash Aujayeb – Conception of the work, Design of the work, Acquisition of data, Analysis of data, Interpretation of data, Drafting the work, Final approval of the version to be published, Agree to be accountable for all aspects of the work in ensuring that questions related to the accuracy or integrity of any part of the work are appropriately investigated and resolved

### Guarantor of Submission

The corresponding author is the guarantor of submission.

### Source of Support

None.

### Consent Statement

Written consent was obtained for the use of images and clinical data for the preparation of this manuscript.

### Conflict of Interest

Authors declare no conflict of interest.

### Data Availability

All relevant data are within the paper and its Supporting Information files.

### Copyright

© 2020 Avinash Aujayeb. This article is distributed under the terms of Creative Commons Attribution License which permits unrestricted use, distribution and reproduction in any medium provided the original author(s) and original publisher are properly credited. Please see the copyright policy on the journal website for more information.

Access full text article on other devices

Access PDF of article on other devices



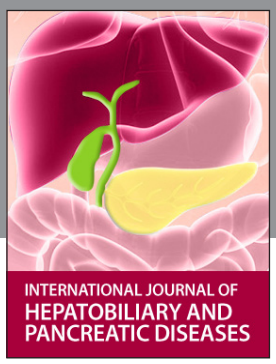

**Submit your manuscripts at**
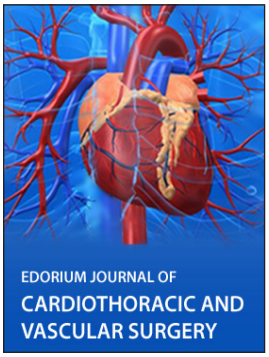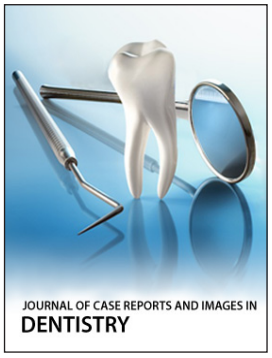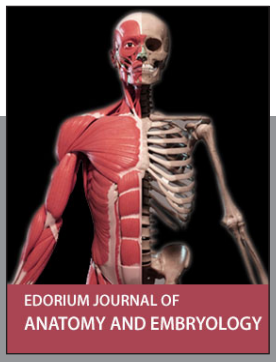
www.edoriumjournals.com