

A giant occipital malignant peripheral nerve sheath tumor in non-neurofibromatosis person: A rare case and review of literature

JKC Emejulu, SPU Nkwerem, OC Ekweogwu,
IV Okpalike, RC Nwosu, CL Okwunze

ABSTRACT

Introduction: Malignant peripheral nerve sheath tumor (MPNST) is an aggressive tumor which is often associated with neurofibromatosis type-1 (NF-1). This rare tumor is often associated with nerve roots and bundles in the extremities. Occipital MPNST is rare. Giant size occipital scalp MPNST is extremely rare in literature. The size of tumor often becomes difficult to treat. We present one of the most gigantic occipital MPNSTs (14 × 27 × 44 cm) published in the literature. **Case Report:** A 27-year-old lady who presented with a huge occipital mass and a history suggestive of bilateral pathological fracture of the tibia. At presentation her occipital mass measured 14 × 27 × 44 cm. Cranial computed tomography (CT) showed evidence of calvarial erosion. She had subtotal tumor resection with histology suggestive of MPNST while immunohistochemistry was positive for S-100. She was referred to the oncology unit for chemoradiation. **Conclusion:** Huge occipital MPNST presents management challenges because treatment is difficult. This giant MPNST has been added to the body of knowledge while the search for the ultimate solution continues.

Keywords: Giant, Malignant peripheral sheath tumor, Non-neurofibromatosis 1, Occipital

How to cite this article

Emejulu JKC, Nkwerem SPU, Ekweogwu OC, Okpalike IV, Nwosu RC, Okwunze CL. A giant occipital malignant peripheral nerve sheath tumor in non-neurofibromatosis person: A rare case and review of literature. Int J Case Rep Images 2020;11:101157Z01JE2020.

Article ID: 101157Z01JE2020

doi: 10.5348/101157Z01JE2020CR

INTRODUCTION

The malignant peripheral nerve sheath tumor (MPNST) is a rare aggressive tumor of the connective tissues surrounding the nerves. This tumor, occasionally referred to as malignant schwannoma, malignant neurilemmoma, neurofibrosarcoma, and neurogenic sarcoma, constitutes 5–10% of all sarcomas in adults [1, 2]. It is found in 50% of neurofibromatosis type-1 (NF-1), an autosomal dominant disorder, while the others are sporadic in occurrence or radiation induced [1]. This rare tumor is often associated with nerve roots and bundles in extremities and pelvis. Malignant peripheral nerve sheath tumors are uncommon in the head [3]. An early presentation may make a wide local excision curative; other treatment modalities include chemotherapy and radiotherapy [4].

We present a case of a giant, grotesque occipital malignant nerve sheath tumor which was recently managed in our service (Figure 1) and also review the literature.

JKC Emejulu¹, SPU Nkwerem², OC Ekweogwu², IV Okpalike³, RC Nwosu³, CL Okwunze⁴

Affiliation: ¹Professor, Department of Surgery, Nnamdi Azikiwe University, Awka, Nigeria; ²Lecturer, Department of Surgery, Nnamdi Azikiwe University, Awka, Nigeria; ³Senior Resident, Department of Surgery, Nnamdi Azikiwe University Teaching Hospital, Nnewi, Anambra State, Nigeria; ⁴Resident, Department of Surgery, Nnamdi Azikiwe University Teaching Hospital, Nnewi, Anambra State, Nigeria.

Corresponding Author: Professor JKC Emejulu, Department of Surgery, Nnamdi Azikiwe University, Awka, Nigeria; Email: judekenny2003@yahoo.com

Received: 13 May 2020

Accepted: 01 July 2020

Published: 20 August 2020

CASE REPORT

A 27-year-old right handed woman with a posterior scalp swelling of six months duration, which was insidious in onset and progressively increasing in size, associated with intermittent dull pains. There was no associated irrational talk, seizure, altered level of consciousness, visual impairment, double vision, or hemi-body weakness. There was neither associated café-au-lait spots nor skin lesions. About five months following the onset of symptoms, she developed bilateral closed tibial fractures following a minor fall. There was no history of fever or preceding trauma before the onset of symptoms. She had no history suggestive of anorexia or weight loss. There was a history of herbal medication initially but, because of the progression of the mass, she sought orthodox treatment.

At presentation, she was fully conscious and alert, and was not in any obvious distress. She was slightly overweight, otherwise, her general clinical condition was unremarkable. There was a huge, tense, cystic soft tissue, left paramedian occipital mass, extending to the middle. The mass was 14 × 27 × 44 cm in dimension (Figure 1), and slightly tender. It did not transilluminate and there was no associated skin nodules or pigmented skin patches. She had normal bilateral visual acuity. There was bilateral lower extremity edema and deformities with splints and crepe bandage in situ. X-ray images showed a left upper-third tibial fracture and right lower-third femoral fracture.

Cranial computed tomography showed a left parietal extra-axial mass with an underlying calvarial defect (barely short of the sagittal suture), with a mixed density extracranial component (hypodense-isodense) that was heterogeneously contrast enhancing (Figure 2). There was an unremarkable metastatic work-up.

A diagnosis of left occipital scalp mass with intracranial extension was made. The plastic surgery was also invited to review. She was subsequently worked up and had craniectomy and subtotal gross tumor excision through a midline scalp incision (Figure 3). The tumor capsule was peeled off the overlying redundant skin. The adjoining periosteum was completely excised, edges of bony defect nibbled till healthy bone was encountered (see arrow in Figure 4) and residual tumor which was adherent to the dura coagulated and the infiltrated dura excised. Dural defect was repaired with a harvested occipital fascia. The redundant and denuded skin was trimmed to size (Figure 5). Tumor specimen and postoperative cranial computed tomography are shown in Figures 6 and 7, respectively. Histology report was diagnostic of a MPNST, while immunohistochemistry was positive for S-100, but negative for epithelial membrane antigen (EMA) and desmin. She was, subsequently, referred to the radio-oncology. Cranioplasty was planned as a second-stage procedure. She had radiotherapy and two courses of ifosfamide and epirubicin before she was lost to follow up.

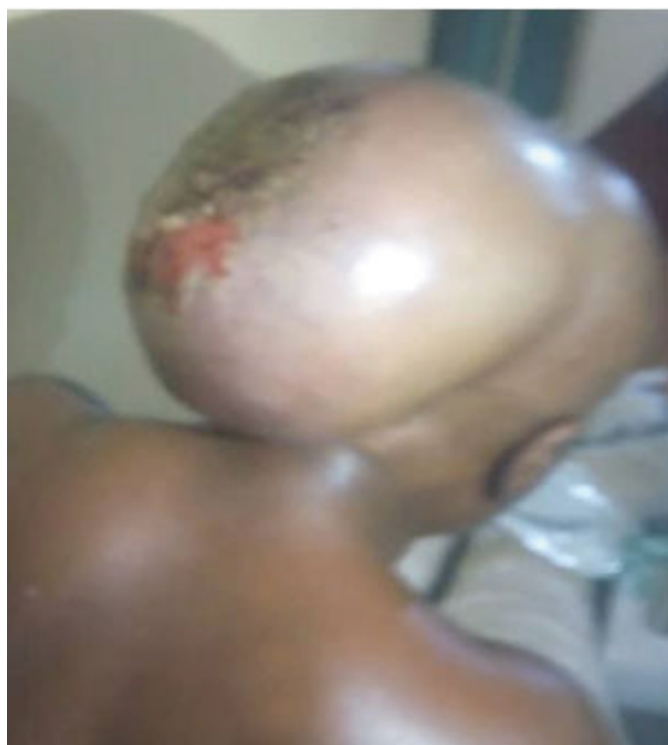

Figure 1: The huge occipital mass.

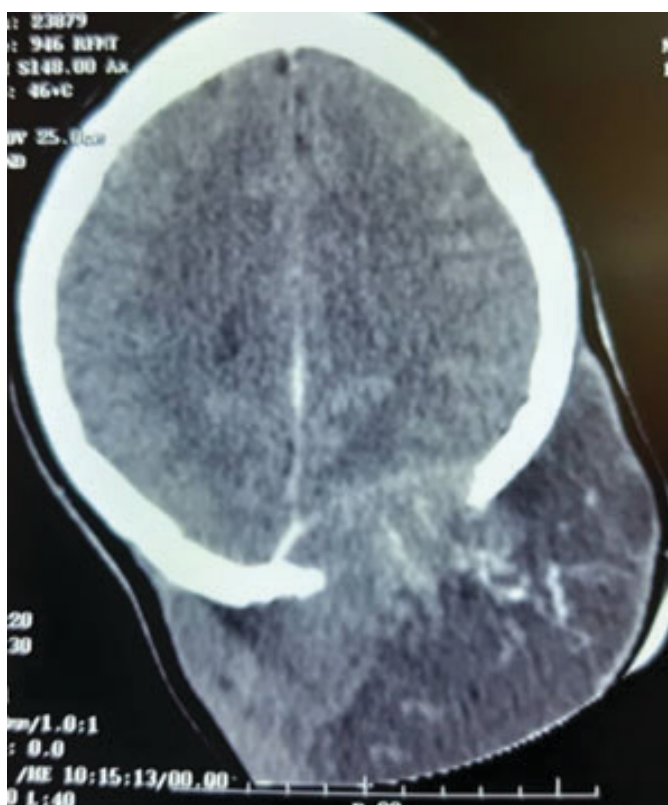


Figure 2: Contrast cranial CT of the lesion showing bony erosion.

DISCUSSION

Malignant peripheral nerve sheath tumor is a rare tumor constituting about 2–6% of all sarcomas [5, 6]. It has no gender predilection, and tends to affect adults aged

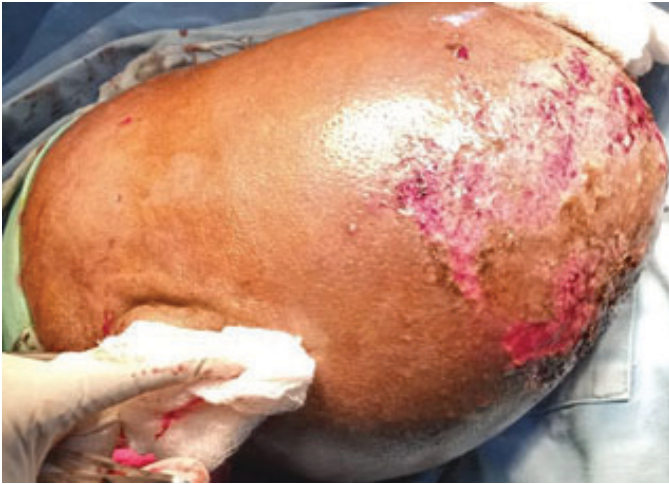

Figure 3: The midline incision.



Figure 6: The excised tumor bits.

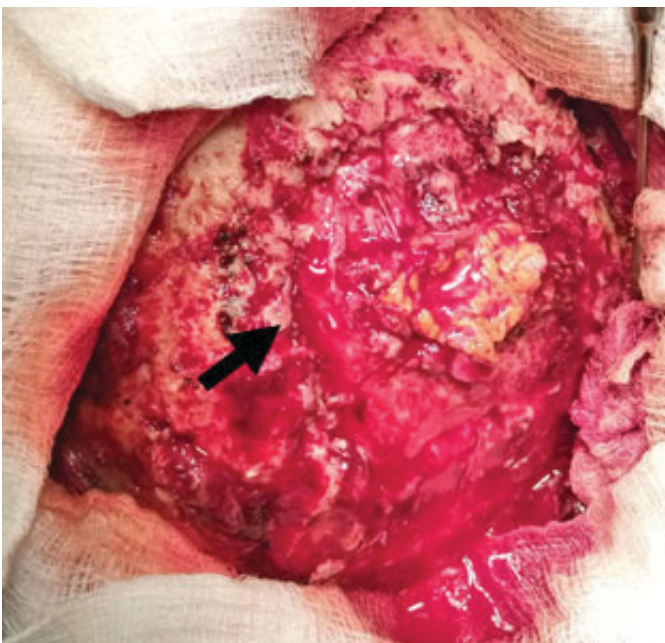


Figure 4: Black arrow showing edge of bony defect exposed.

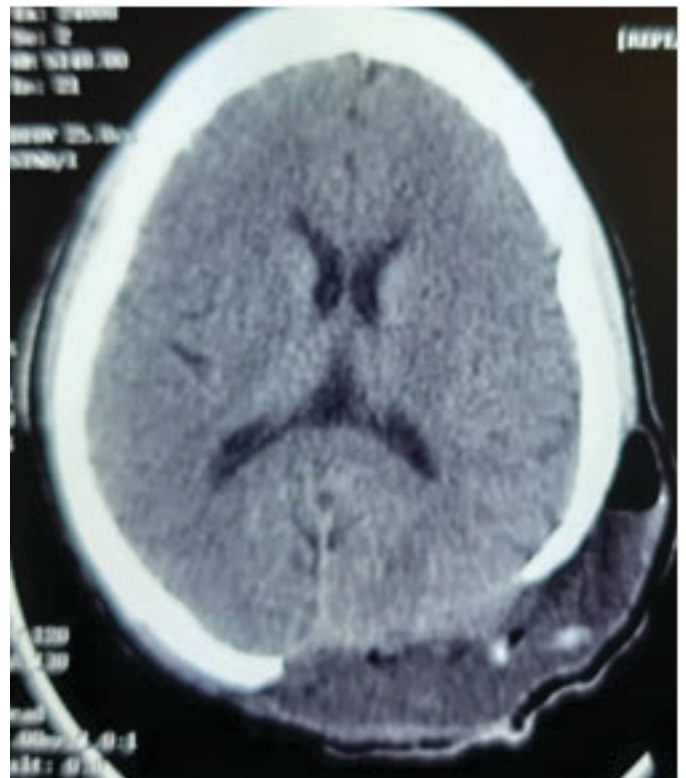


Figure 7: Immediate postoperative cranial CT.

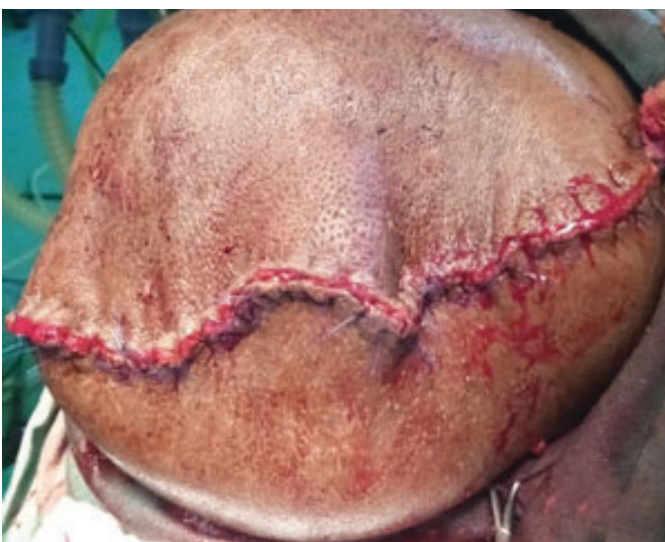

Figure 5: Immediate post-tumor excision showing the redundant skin trimmed to size.

between 20 and 50 years [7]. The tumor can affect any part of the body especially the trunk and extremities, and the sciatic nerve, brachial plexus, and sacral plexus are the most common locations [8]. Occipital scalp MPNST is extremely rare (Table 1) [1, 9–25].

The etiology of MPNST has remained largely unknown, however, there are some genetic mutations so far identified with MPNST, and they include NF-1 and TP53. Both therapeutic and environmental radiation exposures have also been associated with this rare tumor [26, 27]. The NF-1 which is located on chromosome 17q11 codes for neurofibromin is known to take part, ultimately, in the inhibition of the p21ras signaling pathway. The loss of this regulatory pathway has been observed in transformation of the NF-1 to MPNST. Other genetic mutations observed

include the T53 point mutation or deletion, deletion of the CDKN2A, RB1 tumor suppression gene [28, 29]. Yuan et al. have also noted excessive expression of some biomarkers, particularly S-100 and Ki67 in MPNSTs patients [30]. The biomarkers help in easy distinction between benign nerve sheath tumor and the malignant variety.

The MPNSTs are highly invasive and readily metastatic, the index case presented with bilateral pathological femoral fractures and obvious calvarial erosion in 6-month history, making complete cure a difficult task.

Complete surgical resection with margin ≥ 2 cm is important for complete resection. Radical resection with adjuvant radiotherapy is the mainstay of treatment [31]. Generally, in MPNSTs that are high grade, large (>5 cm), surgically inaccessible, or metastatic, complete resection

is often difficult, hence subtotal resection may be what is achievable [29, 31].

Adjuvant radiotherapy is recommended for patient with large high grade tumor (>5 cm) or with microscopically (R1) or macroscopically (R2) positive resected tumor margins as a postoperative measure to reduce local recurrence and control pains [29]. Grotesque tumor size (14 × 27 × 44 cm) with calvarial erosion and dura infiltration, as well as distant metastasis, precludes cure. Late presentation to health care services may account for this tumor size which is one of the largest scalp MPNST in non-neurofibromatosis case published.

Chemotherapy and immunotherapy may also be useful therapeutic strategies [14, 25]. The use of chemotherapy in MPNST has not be very rewarding [1].

The index case had subtotal gross total tumor resection followed by chemoradiation.

Table 1: Published cases of malignant peripheral nerve sheath tumor of the scalp [1]

Study	Sex/age	Tumor location	Neurofibromatosis	Bone infiltration	Immunohisto-chemistry	Treatment
Wang et al. [1]	M/35	Occipital	No	Yes	–	Exc +RT
Wang et al. [1]	F/72	Occipital	NA	Yes	+	Exc +RT
George et al. [9]	F/56	Occipital	No	NA	+	Exc +RT
George et al. [9]	M/50	Temporal	Yes	NA	+	Exc +RT
Dabski et al. [10]	NA/NA	Scalp	No	NA	NA	Exc
Kikuchi et al. [11]	M/59	Frontal	No	NA	+	Exc
Demir and Tokyol [12]	M/80	Parietal	No	No	+	Exc + RT
Garg et al. [13]	M/50	Occipital	NA	Yes	+	Exc +RT
Williams et al. [14]	F/75	Scalp	No	NA	+	CT + Exc
Fukushima et al. [15]	M/38	Occipital	No	NA	+	Exc
Kumar et al. [16]	M/36	Occipital	No	Yes	+	Exc + RT
Ge et al. [17]	M/52	Parietal	Yes	Yes	+	Exc
Hasturk et al. [18]	M/44	Occipital	NA	No	+	Exc
Shintaku et al. [19]	F/59	Scalp	Yes	NA	–	Exc
Voth et al. [20]	M/89	Parietal	Yes	NA	+	Exc +RT
Jhawar et al. [21]	F/43	Parietal	NA	Yes	NA	Exc
Bouhafa et al. [22]	M/15	Occipital	NA	Yes	+	Exc
Firdaus et al. [23]	M/45	Frontal	Yes	Yes	NA	Exc + RT
Firdaus et al. [23]	M/49	Frontal	No	Yes	Yes	Exc + RT
Gupta et al. [24]	M/70	Occipital	No	Yes	Yes	Exc + RT
Liu et al. [25]	M/52	Frontal	NA	Yes	Yes	Exc + CT
Present case	F/27	Occipital	No	Yes	Yes	Exc + RT

NA: Not available, Exc: Excision, RT: Radiotherapy.

Local recurrence rate and metastasis are at 40–65% and 40–68%, respectively [32]. In NF-1 patients, MPNST is the most common cause of mortality.

CONCLUSION

Management of a giant occipital MPNST remains a daunting task. Late presentation of patient with tumor makes treatment a difficult task. We believe that this case report will also add to the body of knowledge and data available for MPNST while the search for the ultimate cure for huge occipital MPNST continues.

REFERENCES

1. Wang J, Ou SW, Guo ZZ, Wang YJ, Xing DG. Microsurgical management of giant malignant peripheral nerve sheath tumor of the scalp: Two case reports and a literature review. *World J Surg Oncol* 2013;11:269.
2. Farid M, Demicco EG, Garcia R, et al. Malignant peripheral nerve sheath tumors. *Oncologist* 2014;19(2):193–201.
3. Pourtsidis A, Doganis D, Baka M, et al. Malignant peripheral nerve sheath tumors in children with neurofibromatosis type 1. *Case Rep Oncol Med* 2014;2014:843749.
4. Owosho AA, Estilo CL, Huryn JM, Chi P, Antonescu CR. A clinicopathologic study of head and neck malignant peripheral nerve sheath tumors. *Head Neck Pathol* 2018;12(2):151–9.
5. Scaife CL, Pisters PW. Combined-modality treatment of localized soft tissue sarcomas of the extremities. *Surg Oncol Clin N Am* 2003;12(2):355–68.
6. Ng VY, Scharschmidt TJ, Mayerson JL, Fisher JL. Incidence and survival in sarcoma in the United States: A focus on musculoskeletal lesions. *Anticancer Res* 2013;33(6):2597–604.
7. Doyle LA. Sarcoma classification: An update based on the 2013 World Health Organization Classification of Tumors of Soft Tissue and Bone. *Cancer* 2014;120(12):1763–74.
8. Kchouk M, Rabet AM, Ghedas K, et al. Extensive malignant schwannoma of the sciatic nerve. Contribution of imaging techniques. [Article in French]. *J Radiol* 1993;74(12):641–4.
9. George E, Swanson PE, Wick MR. Malignant peripheral nerve sheath tumors of the skin. *Am J Dermatopathol* 1989;11(3):213–21.
10. Dabski C, Reiman HM Jr, Muller SA. Neurofibrosarcoma of skin and subcutaneous tissues. *Mayo Clin Proc* 1990;65(2):164–72.
11. Kikuchi A, Akiyama M, Han-Yaku H, Shimizu H, Naka W, Nishikawa T. Solitary cutaneous malignant schwannoma. Immunohistochemical and ultrastructural studies. *Am J Dermatopathol* 1993;15(1):15–9.
12. Demir Y, Tokyol C. Superficial malignant schwannoma of the scalp. *Dermatol Surg* 2003;29(8):879–81.
13. Garg A, Gupta V, Gaikwad SB, et al. Scalp malignant peripheral nerve sheath tumor (MPNST) with bony involvement and new bone formation: Case report. *Clin Neurol Neurosurg* 2004;106(4):340–4.
14. Williams SB, Szlyk GR, Manyak MJ. Malignant peripheral nerve sheath tumor of the kidney. *Int J Urol* 2006;13(1):74–5.
15. Fukushima S, Kageshita T, Wakasugi S, et al. Giant malignant peripheral nerve sheath tumor of the scalp. *J Dermatol* 2006;33(12):865–8.
16. Kumar P, Jaiswal S, Agrawal T, Verma A, Datta NR. Malignant peripheral nerve sheath tumor of the occipital region: Case report. *Neurosurgery* 2007;61(6):E1334–5.
17. Ge P, Fu S, Lu L, Zhong Y, Qi B, Luo Y. Diffuse scalp malignant peripheral nerve sheath tumor with intracranial extension in a patient with neurofibromatosis type 1. *J Clin Neurosci* 2010;17(11):1443–4.
18. Hasturk AE, Basmaci M, Bayram C, Bozdogan N. Surgical management of recurrent malignant schwannoma of the scalp. *J Craniofac Surg* 2011;22(3):1120–2.
19. Shintaku M, Wada K, Wakasa T, Ueda M. Malignant peripheral nerve sheath tumor with fibroblastic differentiation in a patient with neurofibromatosis type 1: Imprint cytological findings. *Acta Cytol* 2011;55(5):467–72.
20. Voth H, Nakai N, Wardelmann E, et al. Malignant peripheral nerve sheath tumor of the scalp: Case report and review of the literature. *Dermatol Surg* 2011;37(11):1684–8.
21. Jhawar SS, Mahore A, Goel N, Goel A. Malignant peripheral nerve sheath tumour of scalp with extradural extension: Case report. *Turk Neurosurg* 2012;22(2):254–6.
22. Bouhafa T, Elmazghi A, Baissel H, Fatmi HE, Amarti A, Hassouni K. Malignant peripheral nerve sheath tumours of the scalp: Case report and review of literature. *International Journal of Clinical Medicine* 2014;5(15):916–20.
23. Firdaus M, Gill AS, Mukarramah DA, et al. Malignant peripheral nerve sheath tumor of the scalp: Two rare case reports. *Surg Neurol Int* 2018;9:102.
24. Gupta A, Kumar R, Ojha BK, Chandra A. Giant malignant peripheral nerve sheath tumor of scalp in non-neurofibromatosis person: A rare case report. *Indian J Neurosurg* 2018;7:54–7.
25. Liu X, Li W, Yuan H, Gu W, Chen D. Surgical treatment of rare giant malignant tumors of the scalp: A report of 3 cases with different tumor types. *Oncol Lett* 2016;12(5):3411–16.
26. Dunn GP, Spiliopoulos K, Plotkin SR, et al. Role of resection of malignant peripheral nerve sheath tumors in patients with neurofibromatosis type 1. *J Neurosurg* 2013;118(1):142–8.
27. Zou C, Smith KD, Liu J, et al. Clinical, pathological, and molecular variables predictive of malignant peripheral nerve sheath tumor outcome. *Ann Surg* 2009;249(6):1014–22.
28. Jouhilahti EM, Peltonen S, Heape AM, Juha Peltonen J. The pathoetiology of neurofibromatosis 1. *Am J Pathol* 2011;178(5):1932–9.
29. Wu LMN, Lu QR. Therapeutic targets for malignant peripheral nerve sheath tumors. *Future Neurol* 2019;14(1).

30. Yuan Z, Xu L, Zhao Z, et al. Clinicopathological features and prognosis of malignant peripheral nerve sheath tumor: A retrospective study of 159 cases from 1999 to 2016. *Oncotarget* 2017;8(62):104785–95.
31. Ziadi A, Saliba I. Malignant peripheral nerve sheath tumor of intracranial nerve: A case series review. *Auris Nasus Larynx* 2010;37(5):539–45.
32. Gousias K, Boström J, Kovacs A, Niehusmann P, Wagner I, Kristof R. Factors of influence upon overall survival in the treatment of intracranial MPNSTs. Review of the literature and report of a case. *Radiat Oncol* 2010;5:114.

Author Contributions

JKC Emejulu – Conception of the work, Design of the work, Acquisition of data, Analysis of data, Interpretation of data, Drafting the work, Revising the work critically for important intellectual content, Final approval of the version to be published, Agree to be accountable for all aspects of the work in ensuring that questions related to the accuracy or integrity of any part of the work are appropriately investigated and resolved

SPU Nkwerem – Conception of the work, Design of the work, Acquisition of data, Analysis of data, Interpretation of data, Drafting the work, Revising the work critically for important intellectual content, Final approval of the version to be published, Agree to be accountable for all aspects of the work in ensuring that questions related to the accuracy or integrity of any part of the work are appropriately investigated and resolved

OC Ekweogwu – Conception of the work, Design of the work, Acquisition of data, Analysis of data, Interpretation of data, Revising the work critically for important intellectual content, Final approval of the version to be published, Agree to be accountable for all aspects of the work in ensuring that questions related to the accuracy or integrity of any part of the work are appropriately investigated and resolved

IV Okpalike – Acquisition of data, Analysis of data, Interpretation of data, Revising the work critically for important intellectual content, Final approval of the version to be published, Agree to be accountable for all

aspects of the work in ensuring that questions related to the accuracy or integrity of any part of the work are appropriately investigated and resolved

RC Nwosu – Acquisition of data, Analysis of data, Interpretation of data, Revising the work critically for important intellectual content, Final approval of the version to be published, Agree to be accountable for all aspects of the work in ensuring that questions related to the accuracy or integrity of any part of the work are appropriately investigated and resolved

CL Okwunze – Acquisition of data, Analysis of data, Interpretation of data, Revising the work critically for important intellectual content, Final approval of the version to be published, Agree to be accountable for all aspects of the work in ensuring that questions related to the accuracy or integrity of any part of the work are appropriately investigated and resolved

Guarantor of Submission

The corresponding author is the guarantor of submission.

Source of Support

None.

Consent Statement

Written informed consent was obtained from the patient for publication of this article.

Conflict of Interest

Authors declare no conflict of interest.

Data Availability

All relevant data are within the paper and its Supporting Information files.

Copyright

© 2020 JKC Emejulu et al. This article is distributed under the terms of Creative Commons Attribution License which permits unrestricted use, distribution and reproduction in any medium provided the original author(s) and original publisher are properly credited. Please see the copyright policy on the journal website for more information.

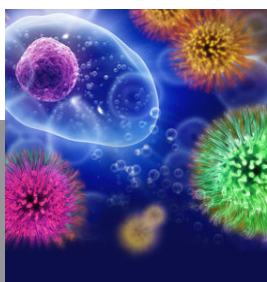
Access full text article on other devices



Access PDF of article on other devices



Submit your manuscripts at
www.edoriumjournals.com



JOURNAL OF CASE REPORTS AND
IMAGES IN INFECTIOUS DISEASES