

A case of hypereosinophilic syndrome with eosinophilic myocarditis secondary to nabumetone

Andrew Vissing, Shivi Jain, Charlotte Bai, Nicholas Ward

ABSTRACT

Introduction: Hypereosinophilic syndromes are a group of disorders defined by an absolute eosinophil count greater than $1.5 \times 10^9/L$ that leads to eosinophil-mediated end-organ damage. Cardiac involvement can range from asymptomatic inflammation of the myocardium to endomyocardial fibrosis and irreversible constrictive cardiomyopathy.

Case Report: We present the case of a patient who presented with confusion and was found to have an absolute eosinophil count of $8.08 \times 10^9/L$ as well as clinical findings consistent with eosinophilic myocarditis. It was determined that her clinical presentation was due to a new medication she had taken, nabumetone. Other causes of hypereosinophilia were ruled out. She improved with two days of pulse dose methylprednisolone and subsequent prednisone taper with complete resolution of her cardiomyopathy and normalization of her absolute eosinophil count.

Conclusion: While there are no guidelines available for the treatment of eosinophilic myocarditis, corticosteroids should be considered in patients with evidence of cardiomyopathy in the setting of hypereosinophilia. Hypereosinophilic syndrome is an uncommonly recognized adverse event of non-steroidal anti-inflammatory drug (NSAID) therapy.

Keywords: Eosinophilic myocarditis, Hypereosinophilic syndrome, Nabumetone

How to cite this article

Vissing A, Jain S, Bai C, Ward N. A case of hypereosinophilic syndrome with eosinophilic myocarditis secondary to nabumetone. Int J Case Rep Images 2020;11:101151Z01AV2020.

Article ID: 101151Z01AV2020

doi: 10.5348/101151Z01AV2020CR

INTRODUCTION

Hypereosinophilic syndromes (HESs) are a rare group of disorders characterized by eosinophil overproduction leading to eosinophil-mediated multi-organ injury. Hypereosinophilic syndrome is defined by an absolute eosinophil count (AEC) above $1.5 \times 10^9/L$ for at least six months that leads to eosinophil-mediated end-organ damage. Cardiac involvement is common in HES, often presenting as eosinophilic myocarditis or endomyocardial fibrosis [1]. Hypereosinophilic syndrome can result from neoplastic processes such as clonal myeloid disorders that lead to eosinophilic proliferation or can result as a reaction to another cause, for example, a parasitic infection or an adverse reaction from a medication [2]. It is important, albeit difficult, to determine the underlying etiology of HES in order to provide the correct therapeutic treatment. Below we present a case of HES with cardiac involvement resulting from a severe drug reaction.

CASE REPORT

A 70-year-old female presented to the emergency department with new onset confusion, memory loss, and increased falls for one week. She had previously been in her normal state of health. Her medical history was significant for rheumatoid arthritis, which was managed with prednisone 10 mg daily and sulfasalazine, both of which she had taken for many years without complications.

Andrew Vissing¹, Shivi Jain², Charlotte Bai², Nicholas Ward³

Affiliations: ¹Resident Physician, Department of Internal Medicine and Pediatrics, Rush University Medical Center, Chicago, IL, USA; ²Assistant Professor, Department of Internal Medicine, Rush University Medical Center, Chicago, IL, USA; ³Assistant Professor, Department of Pathology, Rush University Medical Center, Chicago, IL, USA.

Corresponding Author: Andrew Vissing, 1645 W. Jackson Blvd, Suite 215, Chicago, IL, USA; Email: Andrew_R_Vissing@rush.edu

Received: 13 May 2020

Accepted: 14 July 2020

Published: 05 August 2020

Prior to the onset of symptoms, she started taking a new medication, nabumetone, an NSAID, for her rheumatoid arthritis. The new medication was self-discontinued after two days of therapy for unknown reasons. The patient was not taking other medications or supplements and had not recently traveled outside of Chicago.

On physical exam, the patient was confused but otherwise well appearing. Her blood pressure was 153/83 mmHg, heart rate (HR) 114 bpm. No heart murmurs were auscultated and skin exam revealed no rash. The initial work-up was significant for an elevated troponin of 1.23 ng/mL; the electrocardiogram (EKG) showed sinus tachycardia with premature ventricular complexes and ST segment depression in the inferior and anterior leads (Figure 1). Serum aspartate aminotransferase (AST) and alanine aminotransferase (ALT) were elevated to 76 and 48 U/L, respectively. Her white blood cell (WBC) count was $13.9 \times 10^9/L$ with eosinophilic predominance, AEC of $8.08 \times 10^9/L$ (previous eosinophil count was $0.03 \times 10^9/L$ one year prior to presentation). Immunoglobulin E (IgE) was 3905 kU/L. Head computed tomography (CT) was unremarkable for any acute process. She was given 325 mg aspirin and 1 L of isotonic saline and was admitted to the general medical floor. A repeat troponin was 1.62 ng/mL and EKG was similar to prior. She was started on a heparin drip due to concern for acute coronary syndrome.

The patient subsequently developed worsening encephalopathy a few hours after arrival to the general floor. She underwent repeat head CT imaging, which revealed acute ischemic multi-territory infarcts consistent with embolic strokes. The heparin drip was discontinued to prevent hemorrhagic conversion of the ischemic strokes. There was no evidence of atrial fibrillation while she was on cardiac monitoring. Carotid ultrasound was unremarkable. Echocardiogram showed an estimated ejection fraction of 40% as well as hypokinesis of the anterolateral, the basal-midinferior and the midinferolateral myocardium. There was no thrombus visualized on echocardiogram. Her troponin peaked at 5.70 ng/mL on day 3 of hospitalization and the EKG was without ischemic changes. The patient was deemed too unstable to undergo cardiac magnetic resonance imaging (MRI) and anticoagulation for prevention of cardiac thrombus formation was deferred due to her recent stroke. She underwent a bone marrow biopsy on day 4 and was subsequently started on pulse dose steroids [intravenous (IV) methylprednisolone 500 mg twice daily] due to concern for eosinophilic myocarditis. The AEC decreased to $0 \times 10^9/L$ after two days of pulse dose steroids. The patient was transitioned to prednisone 60 mg daily.

A bone marrow biopsy revealed hypercellular bone marrow (70–80%) featuring eosinophilia (37% by aspirate differential) (Figure 2) with unremarkable cytology. Bone marrow and peripheral blood flow cytometry showed no evidence of hematolymphoid neoplasm. JAK2 V617F mutation was not detected. Genomic testing (Tempus xT) of the bone marrow did not reveal

any pathogenic variant or clonal process. Fluorescence in situ hybridization (FISH) analysis did not detect the involvement of platelet-derived growth factor receptor A (PDGFR-A), PDGFR-B, or fibroblast growth factor receptor 1 (FGFR1). Computed tomography imaging of the chest, abdomen, and pelvis did not show any evidence of lymphadenopathy. An antinuclear antibody screen was negative. A rheumatologic work-up was consistent with known rheumatoid arthritis. Strongyloides IgG antibody was not detected and no ova or parasites were seen in the stool.

Over the course of the next few days, the patient's clinical status improved and prednisone was tapered slowly based on AEC. A repeat echocardiogram showed normal heart function (ejection fraction of 50–55% with no wall motion abnormalities). The patient's mental status improved and her transaminitis resolved. She continued to have upper extremity motor deficits and was eventually transferred to inpatient rehabilitation

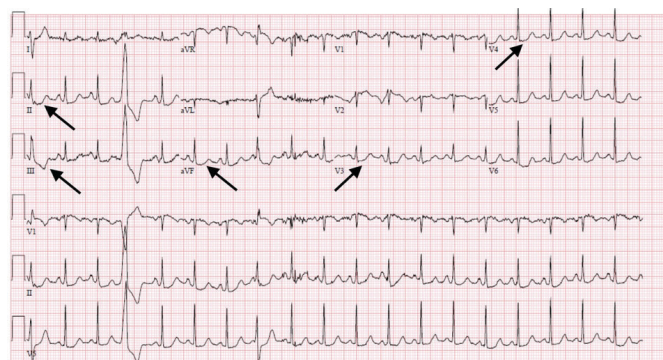


Figure 1: EKG with sinus tachycardia with premature ventricular complexes and ST segment depression in the inferior and anterior leads.

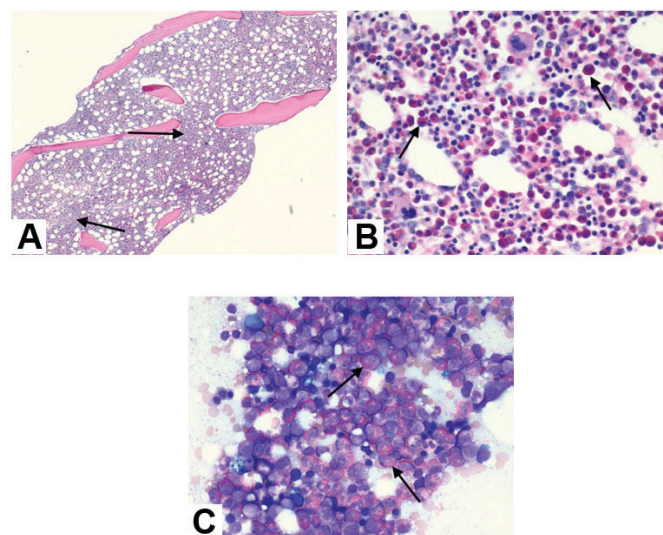


Figure 2: (A) Bone marrow core biopsy demonstrating a hypercellular marrow (H&E, $\times 40$). (B) Bone marrow core biopsy featuring marked increase in eosinophils in a background of trilineage hematopoiesis (H&E, $\times 80$). (C) Bone marrow aspirate smear revealing copious numbers of predominately mature appearing eosinophils (Wright-Giemsa, $\times 1000$).

for further therapy. She has since been discharged home and continues to work to regain motor function. She has returned to her baseline mental status and remains on 10 mg prednisone daily.

DISCUSSION

The features required for the diagnosis of HES are an AEC over $1.5 \times 10^9/L$ on a peripheral blood sample that persists for six months with signs, symptoms, or pathologic evidence of eosinophil-mediated end-organ damage. Our patient presented with significant eosinophilia after a new medication, nabumetone. She had an absolute eosinophil count $>1.5 \times 10^9/L$, however, had not met the six-month time frame required for the official diagnosis of HES. We use the term "HES" in a more broad sense to include all cases with clinical manifestations attributable to hypereosinophilia (AEC $> 1.5 \times 10^9/L$). There was no biopsy proven eosinophil-mediated end-organ damage in our patient's case. Nevertheless, she had clinical manifestations consistent with eosinophilic myocarditis, transaminitis, and encephalopathy, all three of which resolved after 48 hours of pulse dose steroids and subsequent prednisone taper. Other primary and secondary causes of eosinophilia were ruled out including bone marrow biopsy with cytology and genomic studies. Hence, we conclude that her hypereosinophilic syndrome was attributed to a severe reaction to nabumetone.

The diagnosis of HES secondary to medications is challenging. In our patient's case, symptoms started acutely after initiation of nabumetone therapy, an NSAID she had been prescribed for her rheumatoid arthritis. Detailed literature review revealed a similar case report of another patient who presented with HES after nabumetone therapy in which case the patient presented with chronic symptoms after having been on nabumetone for many months. The patient's absolute eosinophil count was similar to our patient's (peaked around $8 \times 10^9/L$) and she also presented with cardiac involvement. However, in that case, her disease had already progressed to endomyocardial fibrosis and discontinuation of the medication and initiation of high-dose corticosteroids did not improve her cardiac dysfunction [3]. Other NSAIDs have also been shown to cause hypereosinophilia. One case report showed eosinophilic pneumonia in the setting of oral diclofenac. Naproxen, ibuprofen, and fenbufen have also been associated with similar findings. In all cases, removal of the offending agent and a course of corticosteroids led to recovery [4].

Generally, cardiac involvement from hypereosinophilia is classified into three stages. The first stage is generally asymptomatic and is called the early necrotic stage with involvement of the endomyocardium. Echocardiogram findings are usually normal during this stage but occasionally show wall thickening due to inflammation of the myocardium. The second stage is characterized by thrombus formation in the damaged endocardium,

generally in the apices of both ventricles. This may result in embolic events. The third stage is endomyocardial fibrosis, which is characterized by irreversible damage often leading to a restrictive cardiomyopathy [1, 5]. Our patient likely only progressed to the first (necrotic) stage. Her cardiac function returned to normal after a few days of pulse dose steroids and there was no evidence of thrombosis on transthoracic echocardiogram. Nevertheless, she did have multiple acute strokes consistent with possible embolic events, so it is possible our patient had progressed to the second stage, although her echocardiogram findings were not supportive of this.

There are currently no official recommendations for corticosteroid dosing in the setting of eosinophilic myocarditis. Abayazeed et al. describe a patient who had Loeffler endocarditis in the setting of HES, whose course was complicated by thromboembolic events. Their patient was started on a course of pulse dose steroids with dexamethasone 16 mg for three days then 8 mg for five days followed by prednisone 60 mg daily. Eosinophil count decreased to normal range and repeat echocardiogram showed return of normal cardiac function after one month of corticosteroid therapy. Steroid taper was initiated after two months of therapy [6]. Our patient only required two days of pulse dose corticosteroids (IV methylprednisolone 500 mg twice a day) and then was transitioned to oral prednisone and subsequent taper. The eosinophil count was used to guide the steroid taper and our patient did not experience any relapse of hypereosinophilia.

CONCLUSION

Hypereosinophilic syndrome is a rare entity that requires prompt diagnosis and work-up to ensure proper therapy as it can lead to significant end-organ damage including venous thromboembolisms, pulmonary fibrosis, peripheral neuropathy, and encephalopathy. Non-steroidal anti-inflammatory drugs are an under-recognized cause of hypereosinophilic syndrome despite their widespread use in medicine. Cardiac manifestations can range from asymptomatic inflammation of myocardium to endomyocardial fibrosis leading to an irreversible constrictive cardiomyopathy. There are currently no guidelines for corticosteroid use in cardiac disease related to hypereosinophilia; however, our patient showed significant improvement of cardiac function with pulse dose corticosteroids. Even without classic echocardiogram findings, pulse dose corticosteroids should be considered in patients with evidence of cardiomyopathy in the setting of hypereosinophilia. Nevertheless, if not detected in a timely manner, late initiation of corticosteroids will not reverse endomyocardial fibrosis, hence the need for a high index of suspicion for cardiac involvement in patients with hypereosinophilia.

REFERENCES

1. Mankad R, Bonnicksen C, Mankad S. Hypereosinophilic syndrome: Cardiac diagnosis and management. *Heart* 2016;102(2):100–6.
2. Klion AD. How I treat hypereosinophilic syndromes. *Blood* 2015;126(9):1069–77.
3. Pitt M, Davies MK, Brady AJ. Hypereosinophilic syndrome: Endomyocardial fibrosis. *Heart* 1996;76(4):377–8.
4. Krabansky F, Azzouz B, Biya J, Taam MA, Morel A, Trenque T. Eosinophilic pneumonia induced by non-steroidal anti-inflammatory drugs: An underestimated risk. *Therapie* 2018;73(6):473–82.
5. Gleich GJ, Leiferman KM. The hypereosinophilic syndromes: Current concepts and treatments. *Br J Haematol* 2009;145(3):271–85.
6. Abayazeed RM, Abdel-Hay MA, Elfawal S, Hssanein M. A case report of Löffler endocarditis in idiopathic hypereosinophilic syndrome: Recovery is possible. *Eur Heart J Case Rep* 2018;2(2):yty030.

Author Contributions

Andrew Vissing – Conception of the work, Design of the work, Drafting the work, Revising the work critically for important intellectual content, Final approval of the version to be published, Agree to be accountable for all aspects of the work in ensuring that questions related to the accuracy or integrity of any part of the work are appropriately investigated and resolved

Shivi Jain – Conception of the work, Revising the work critically for important intellectual content, Final approval of the version to be published, Agree to be accountable for all aspects of the work in ensuring that questions related to the accuracy or integrity of any part of the work are appropriately investigated and resolved

Charlotte Bai – Design of the work, Revising the work critically for important intellectual content, Final approval

of the version to be published, Agree to be accountable for all aspects of the work in ensuring that questions related to the accuracy or integrity of any part of the work are appropriately investigated and resolved

Nicholas Ward – Design of the work, Acquisition of data, Revising the work critically for important intellectual content, Final approval of the version to be published, Agree to be accountable for all aspects of the work in ensuring that questions related to the accuracy or integrity of any part of the work are appropriately investigated and resolved

Guarantor of Submission

The corresponding author is the guarantor of submission.

Source of Support

None.

Consent Statement

Written informed consent was obtained from the patient for publication of this article.

Conflict of Interest

Authors declare no conflict of interest.

Data Availability

All relevant data are within the paper and its Supporting Information files.

Copyright

© 2020 Andrew Vissing et al. This article is distributed under the terms of Creative Commons Attribution License which permits unrestricted use, distribution and reproduction in any medium provided the original author(s) and original publisher are properly credited. Please see the copyright policy on the journal website for more information.

Access full text article on other devices



Access PDF of article on other devices

