

Nontuberculous mycobacterium presenting with high-attenuation mucus on chest computed tomography

Yasuyuki Taooka, Junya Inata, Hiroki Yoke, Yutaro Takata

CASE REPORT

A 76-year-old female during the treatment of nontuberculous mycobacterium (NTM) (*Mycobacterium avium* complex infection) was admitted to our hospital complained of bloody sputum and low-grade fever for last six days. She had a past history of mitral valve replacement operation, and warfarin and low dose of aspirin were administrated as anti-coagulant therapy. In addition, clarithromycin, ethambutol, and rifampicin were also administrated for the treatment of NTM. Three days before consulting our outpatient clinic, she consulted her primary care physician and was treated with clavulanic acid/amoxicillin for 3 days. However, her bloody sputum was continued, and she consulted our outpatient clinic. Chest computed tomography (CT) imaging showed tree-in-bud appearance (bronchiolitis) with right upper lobe and consolidative shadow with left upper lobe (Figure 1A). Computed tomography showed consolidation in left upper lobe (Figure 1A). In left main bronchus, high-density plugged sputum was observed [high-attenuation mucus (HAM)] (Figure 1B and C). Sputum bacterial culture test utilizing matrix assisted laser desorption/ionization time-of-flight mass spectrometer showed *Aspergillus fumigatus*. *Mycobacterium avium* complex was also confirmed. Sputum cytological examination showed *Aspergillus hyphae*. Blood examination showed as following: white blood cell count was 4980/ μ L (eosinophil 8.0%, lymphocyte 35.1%, and neutrophil 57.5%), hemoglobin 13.8 g/dL, platelet count 179,000/ μ L, C-reactive protein 0.37 mg/dL, immunoglobulin E radioallergosorbent testing (IgE RAST) 440 IU/mL,

aspergillus RAST 2.59 (class 2), anti-aspergillus antigen 0.1, β -D glucan 7.1 pg/mL. As long as we confirmed, she did not have a past history of bronchial asthma. Bronchofiberscopic examination was performed and aspirated viscous purulent sputum from left lower trunk bronchus (Figure 2). Sputum bacterial culture test showed *A. fumigatus*. The diagnosis of allergic

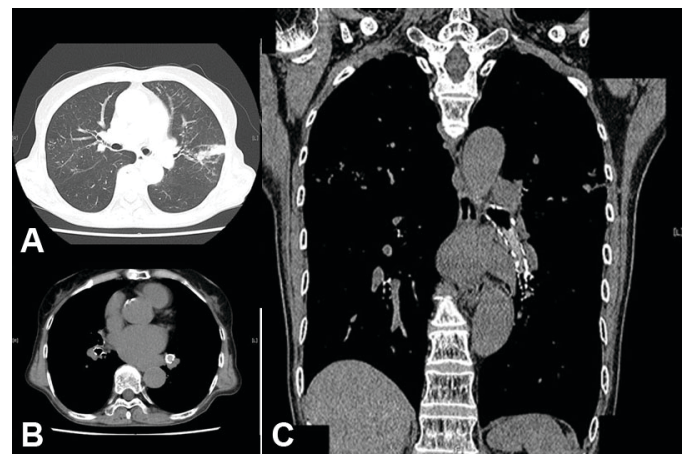


Figure 1: Thoracic CT: Consolidation was observed on left lingual lobe (A). Material within the left main bronchus is purulent on CT [(B) axial and (C) coronal view (C)].

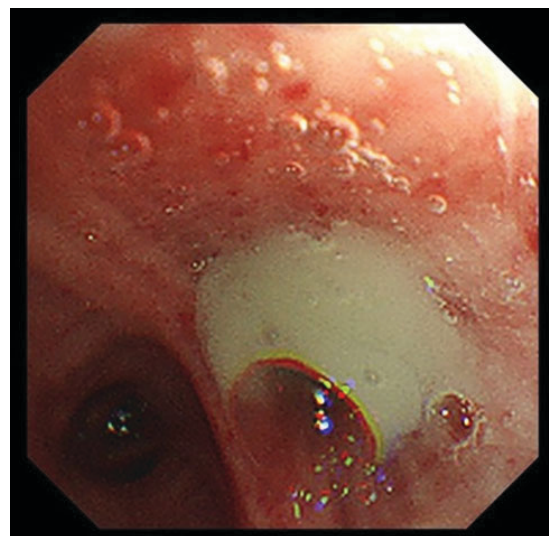


Figure 2: Bronchofiberscopic view: Purulent sputum was observed in left lower trunk bronchus.

Yasuyuki Taooka¹, Junya Inata¹, Hiroki Yoke¹, Yutaro Takata¹

Affiliation: ¹Department of Respiratory Medicine, Medical Corporation JR Hiroshima Hospital, Hiroshima, Japan.

Corresponding Author: Yasuyuki Taooka, Department of Respiratory Medicine, Medical Corporation JR Hiroshima Hospital, 3-1-36, Futabano-sato, Higashi-ku, Hiroshima 732-0057, Japan; Email: taooka-alg@umin.ac.jp

Received: 12 April 2020

Accepted: 29 May 2020

Published: 08 July 2020

bronchopulmonary aspergillosis (ABPA) was performed, and administration of 0.5 mg/kg/day of prednisolone was started. Eosinophilia, high IgE-titer, and her symptoms were gradually improved.

- Agarwal R, Gupta D, Aggarwal AN, Saxena AK, Chakrabarti A, Jindal SK. Clinical significance of hyperattenuating mucoid impaction in allergic bronchopulmonary aspergillosis: An analysis of 155 patients. *Chest* 2007;132(4):1183–90.

DISCUSSION

Allergic bronchopulmonary aspergillosis is known as lower respiratory tract inflammation derived from type I and III/IV allergic reaction against *A. fumigatus* [1]. Allergic bronchopulmonary aspergillosis complicated with bronchial asthma or cystic fibrosis, but NTM is also reported as complication ABPA [1]. Since irreversible fibrotic change and severe bronchiectasis were progressed in advance case, diagnosis of ABPA in earlier stage is important. But it is difficult in case of without bronchial asthma like this case. From 20% to 30% of ABPA case, HAM with chest CT was confirmed, and that is realized for specific findings with ABPA [1, 2]. High-attenuation mucus is realized as sputum plug showing higher CT intensity than that of skeletal muscle. Components of iron and calcium are the cause of higher intensity of sputum plug ABPA [2].

CONCLUSION

A rare case of ABPA with NTM was reported. HAM was useful for the diagnosis. As the cause of bloody sputum with NTM, possibility of ABPA should be considered as the differential diagnosis.

Keywords: Allergic bronchopulmonary aspergillosis, High-attenuation mucus, Nontuberculous mycobacterium

How to cite this article

Taooka Y, Inata J, Yoke H, Takata Y. Nontuberculous mycobacterium presenting with high-attenuation mucus on chest computed tomography. *Int J Case Rep Images* 2020;11:101142Z01YT2020.

Article ID: 101142Z01YT2020

doi: 10.5348/101142Z01YT2020CI

REFERENCES

- Agarwal R, Khan A, Garg M, Aggarwal AN, Gupta D. Chest radiographic and computed tomographic manifestations in allergic bronchopulmonary aspergillosis. *World J Radio* 2012;4(4):141–50.

Author Contributions

Yasuyuki Taooka – Conception of the work, Design of the work, Acquisition of data, Analysis of data, Interpretation of data, Drafting the work, Revising the work critically for important intellectual content, Final approval of the version to be published, Agree to be accountable for all aspects of the work in ensuring that questions related to the accuracy or integrity of any part of the work are appropriately investigated and resolved

Junya Inata – Acquisition of data, Analysis of data, Interpretation of data, Revising the work critically for important intellectual content, Final approval of the version to be published, Agree to be accountable for all aspects of the work in ensuring that questions related to the accuracy or integrity of any part of the work are appropriately investigated and resolved

Hiroki Yoke – Analysis of data, Interpretation of data, Revising the work critically for important intellectual content, Final approval of the version to be published, Agree to be accountable for all aspects of the work in ensuring that questions related to the accuracy or integrity of any part of the work are appropriately investigated and resolved

Yutaro Takata – Acquisition of data, Analysis of data, Interpretation of data, Revising the work critically for important intellectual content, Final approval of the version to be published, Agree to be accountable for all aspects of the work in ensuring that questions related to the accuracy or integrity of any part of the work are appropriately investigated and resolved

Guarantor of Submission

The corresponding author is the guarantor of submission.

Source of Support

None.

Consent Statement

Written informed consent was obtained from the patient for publication of this article.

Conflict of Interest

Authors declare no conflict of interest.

Data Availability

All relevant data are within the paper and its Supporting Information files.

Copyright

© 2020 Yasuyuki Taooka et al. This article is distributed under the terms of Creative Commons Attribution License which permits unrestricted use, distribution


and reproduction in any medium provided the original author(s) and original publisher are properly credited. Please see the copyright policy on the journal website for more information.

Access full text article on other devices



Access PDF of article on other devices





Submit your manuscripts at
www.edoriumjournals.com

