

Acute mucosal appendicitis and epiploic appendagitis in an adult: A rare case report

Quoc (Ryan) Tran, Hamish Raniga, Yasser Arafat,
Ryo Mizumoto, Tarana Lucky, Sujith Ratnayake

ABSTRACT

Introduction: Concurrent presence of two distinct pathologies, such as acute mucosal appendicitis with epiploic appendagitis, is unusual and can often lead to a management dilemma for surgeons. Here, we present a case description of this clinical rarity and reviewed the available literature in managing this rather uncommon but potentially life-threatening clinical condition. **Case Report:** A 44-year-old male presented to the emergency department with a one-day history of nonmigratory acute right iliac fossa pain. Clinical examination revealed right iliac fossa tenderness with positive rebound sign. Biochemical tests were generally insignificant. Abdominal computed tomography (CT) showed features suggestive of acute appendicitis (diameter of appendix was 7 mm and inflammatory changes noted in the mid part). Based on these findings, a laparoscopy was performed. Intraoperatively, there was a macroscopically normal appearing appendix and an anticlockwise rotation of necrotic epiploic appendage. The necrotic tissue was transected followed by a planned appendectomy. The histology confirmed the presence of both epiploic appendagitis and

mucosal appendicitis. Overall, the patient had an uneventful postoperative recovery and was discharged on postoperative day one. **Conclusion:** Due to the benign and self-limiting nature of epiploic appendagitis, the need for emergent laparoscopy is generally not required in most cases. However, in the context of co-existing acute appendicitis, definitive management with laparoscopic removal of inflammatory/necrotic tissues followed by appendectomy appears to be an acceptable management option.

Keywords: Appendicitis, Appendagitis, Management, Mucosal

How to cite this article

Tran QR, Raniga H, Arafat Y, Mizumoto R, Lucky T, Ratnayake S. Acute mucosal appendicitis and epiploic appendagitis in an adult: A rare case report. Int J Case Rep Images 2020;11:101093Z01QT2020.

Article ID: 101093Z01QT2020

doi: 10.5348/101093Z01QT2020CR

Quoc (Ryan) Tran^{1,2}, Hamish Raniga³, Yasser Arafat^{1,2}, Ryo Mizumoto², Tarana Lucky^{1,4}, Sujith Ratnayake³

Affiliations: ¹Department of Surgery, Toowoomba Hospital, Toowoomba, Australia; ²School of Medicine, The University of Queensland, St Lucia, Queensland, Australia; ³Department of Surgery, Caboolture Hospital, Caboolture, Queensland, Australia; ⁴School of Medicine, Griffith University, Queensland, Australia.

Corresponding Author: Quoc (Ryan) Tran, Toowoomba Hospital, Pechey St, South Toowoomba, Queensland 4350, Australia; Email: ryantran1001@gmail.com

Received: 04 December 2019

Accepted: 02 January 2020

Published: 27 January 2020

INTRODUCTION

Acute appendicitis is a common condition characterized by an inflammation of the vermiform appendix. Acute mucosal appendicitis is the inflammation of appendiceal mucosa in a macroscopically normal appearing appendix [1]. Usually, appendiceal inflammation is caused by a blockage of the lumen; commonly by a fecalith or expanded lymphoid tissue during a viral illness. It is one of the most common causes of an acute abdomen that leads to emergent surgical intervention. However, there are multiple other causes of acute abdominal pain which may masquerade as acute

appendicitis [2]. One of those causes is an acute torsion of an epiploic appendage of the colon.

Epiploic appendages are normal pedunculated adipose tissue protruding from the colonic surface and appear as projections into the peritoneal cavity [3]. Although the physiological role of epiploic appendages is not well described, it has been hypothesized that they may have a role in colonic absorption as well as some protective or defensive roles comparable to that of the greater omentum. In addition, a role in providing a cushion for colonic vessels during peristalsis has also been described [4]. By adulthood, most epiploic appendages are 1–2 cm thick and 2–5 cm in length. Acute torsion and subsequent ischemic infarction of these structures are rare occurrences, and often referred to as epiploic appendicitis. Epiploic appendicitis can mimic an acute abdomen; however, it is a benign self-limiting condition which can usually be managed conservatively without surgical intervention.

This case report discusses the rare concurrent presence of acute mucosal appendicitis and epiploic appendicitis in a 44-year-old gentleman with acute abdominal pain requiring emergent laparoscopy. Although distinct pathologies, the presence of a macroscopically normal appendix as in mucosal appendicitis, and epiploic appendicitis can lead to a management dilemma. The combination of both conditions is uncommon and has not been well documented in the literature [5].

CASE REPORT

A 44-year-old male presented to Accident & Emergency Department with a one-day history of nonmigratory right iliac fossa pain, associated with anorexia. On abdominal examination, he had right iliac fossa tenderness with positive rebound, however, Rovsing's sign was negative. His inflammatory markers were normal (white cell count of 8.5). His urine dipstick had traces of leukocytes and negative nitrites; formal urine microscopy showed a leukocyte count of 60 but culture was negative. Further investigations included an abdominal CT which revealed the diameter of appendix to be 7 mm with inflammatory changes in the mid part of the appendix (Figure 1). The official radiology report suggested acute appendicitis. Based on examination and CT confirmation, a decision was made to undergo definitive laparoscopy in the following morning with overnight intravenous antibiotics while waiting on the emergency board. Intraoperatively, the appendix had a normal macroscopic appearance. However, an anticlockwise rotation of a necrotic epiploic appendage was noted (Figure 2). The necrotic tissue was transected and endoloop was applied. A planned appendectomy followed in consideration of the clinical suspicion of appendicitis and the associated positive CT finding. The patient had an uneventful postoperative recovery and was discharged on postoperative day one. The histology confirmed the presence of both epiploic appendicitis and mucosal appendicitis. The patient had

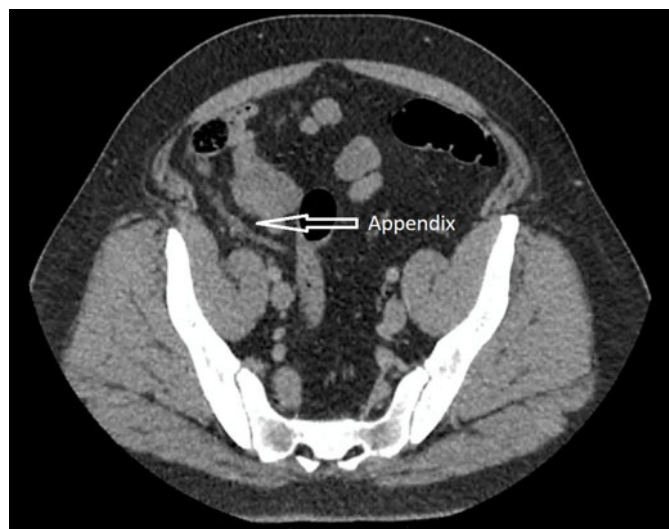

Figure 1: Axial view of computed tomography (CT) showing some inflammation of the appendix.

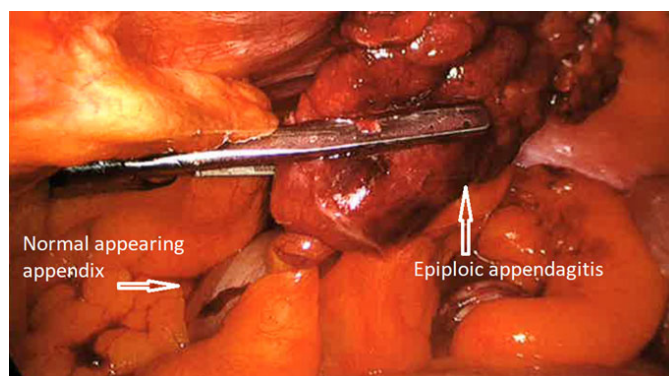


Figure 2: Laparoscopic view showing a macroscopically normal appendix and epiploic appendicitis.

a full recovery with no complication at two weeks after review in the outpatient clinic.

DISCUSSION

Epiploic appendages are small fatty projections on the external surface of the colon. Each appendage usually encloses a circular artery and vein. Epiploic appendagitis is caused by acute ischemic infarction of the epiploic appendage, which often results from spontaneous torsion or thrombosis of the enclosed central draining vein [6, 7]. Although, first described by Lynn et al. in 1956, only recently that this entity received wide recognition [6]. This condition tends to occur four times more often in males than in females, and typically presents during the second to fifth decade of life. Obesity and recent sudden weight loss have also been cited as risk factors for reasons which are unclear [7].

The true incidence of epiploic appendagitis is not well known. However, according to Schnedl et al. about 2–7% of patients with initial clinical diagnosis of acute

diverticulitis and about 1% of patients suspected of having acute appendicitis were reported to have epiploic appendagitis [8, 9]. Literature evidence is lacking in regard to the incidence of concurrent presence of both epiploic appendagitis and acute appendicitis.

Like appendicitis or diverticulitis, epiploic appendagitis also presents with acute or subacute lower abdominal pain. Similar to our case, patients will often describe the pain as dull, constant, and nonradiating. Clinically, patients usually do not appear significantly ill and are usually afebrile. Biochemical markers including white cell counts and C-reactive protein (CRP) tend to be unremarkable but may be mildly elevated in some cases. Abdominal CT scan may show an oval shaped paracolic mass with fat stranding but may be normal in the absence of actively inflamed epiploic appendage [10]. In our case, abdomen CT scan demonstrated signs consistent with acute appendicitis but failed to show evidence of epiploic appendagitis. Hence, acute abdominal pain and CT-proven appendicitis ultimately led to emergent laparoscopy. During laparoscopy, an incidental epiploic appendagitis was demonstrated which may have been the contributing cause of pain.

Current literature and clinical practice recommend that surgical management of epiploic appendagitis is generally not necessary. It is usually a benign and self-limiting condition and recurrence rates are extremely low. With conservative and supportive care, epiploic appendagitis will generally resolve within 3–14 days [11]. In rare instances, inflamed epiploic appendages have been known to adhere to the abdominal wall or viscera and pose a risk for intestinal obstruction or volvulus. In addition, infarcted appendages may detach and have been cited as one of the most common causes of intraperitoneal foreign bodies. These foreign bodies can be confused with neoplastic processes leading to further investigation, intervention, and anxiety [12]. Contrary to most of the case studies involving epiploic appendagitis or acute appendicitis, the finding of both conditions in the same individual as in our patient appears fairly uncommon and is not well documented in the literature. Therefore, there is a lack of best practice evidence in managing this rather unusual presentation. In the case described here, the decision to remove both structures operatively was mainly based on the clinical situation and proved to be an acceptable management option in this case.

In addition, it is important to note that controversy currently exists in defining the true nature and clinical significance of mucosal appendicitis. Many authors have argued that mucosal appendicitis is not a true appendicitis and currently considered as a coincidental secondary pathology [2, 13–15]. On the other hand, some studies have explored clinical consequences of mucosal appendicitis and reconfirmed validity of mucosal appendicitis. In a retrospective review of clinical and radiological parameters, some authors concluded that mucosal appendicitis was indeed associated with

significant clinical findings which improved subsequent to definitive surgical management. However, despite the controversy, it is imperative to recognize that in our case, alike the study population reported by Mizumoto et al. [1], clinical feature that is strongly suggestive of appendicitis and confirmed by imaging mostly would require definite management, such as laparoscopy.

CONCLUSION

Epiploic appendagitis remains a diagnostic challenge to surgeons, particularly if it coexists with acute appendicitis. Due to the benign and self-limiting nature of epiploic appendagitis, the need for emergent laparoscopy is generally not required in most cases. However, in the case of acute appendicitis requiring laparoscopic appendectomy and concurrent epiploic appendagitis, the removal of both inflamed structures may be an acceptable management option in view of the rare but potential associated risk of complication.

REFERENCES

1. Mizumoto R, Cristaudo AT, Lai NK, Premaratne G, Hendaheva R. Dilemma of mucosal appendicitis: A clinico-pathological entity? A retrospective cohort study. *ANZ J Surg* 2018;88(4):E284–8.
2. Bhangu A, Søreide K, Di Saverio S, Assarsson JH, Drake FT. Acute appendicitis: Modern understanding of pathogenesis, diagnosis, and management. *Lancet* 2015;386(10000):1278–87.
3. Li A, Lau S, Loke TKL, Chan JCS. Primary epiploic appendagitis. *J HK Coll Radiol* 2004;7:81–3.
4. Violago FC, Thorlakson RH. Torsion of the appendices epiploicae. *Can Med Assoc J* 1969;100(6):291–4.
5. Savage L, Gosling J, Suliman I, Klein M. Epiploic appendagitis with acute appendicitis. *BMJ Case Rep* 2013;2013. pii: bcr2013010333.
6. Dockerty MB, Lynn TE, Waugh JM. A clinicopathologic study of the epiploic appendages. *Surg Gynecol Obstet* 1956;103(4):423–33.
7. Almeida AT, Melão L, Viamonte B, Cunha R, Pereira JM. Epiploic appendagitis: An entity frequently unknown to clinicians—diagnostic imaging, pitfalls, and look-alikes. *AJR Am J Roentgenol* 2009;193(5):1243–51.
8. Schnedl WJ, Krause R, Tafait E, Tillich M, Lipp RW, Wallner-Liebmann SJ. Insights into epiploic appendagitis. *Nat Rev Gastroenterol Hepatol* 2011;8(1):45–9.
9. McGeer PL, McKenzie AD. Strangulation of the appendix epiploica: A series of 11 cases. *Can J Surg* 1960;3:252.
10. Rao PM, Wittenberg J, Lawrason JN. Primary epiploic appendagitis: Evolutionary changes in CT appearance. *Radiology* 1997;204(3):713–7.
11. Rioux M, Langis P. Primary epiploic appendagitis: Clinical, US, and CT findings in 14 cases. *Radiology* 1994;191(2):523–6.

12. Ross JA, McQueen A. Peritoneal loose bodies. *Br J Surg* 1948;35(139):313–7.
13. Carr NJ. The pathology of acute appendicitis. *Ann Diagn Pathol* 2000;4(1):46–58.
14. Lamps LW. Beyond acute inflammation: A review of appendicitis and infections of the appendix. *Diagn Histopathol* 2008;14(2):6877.
15. Pieper R, Kager L, Näsman P. Clinical significance of mucosal inflammation of the vermiform appendix. *Ann Surg* 1983;197(3):368–74.

Author Contributions

Quoc (Ryan) Tran – Conception of the work, Drafting the work, Final approval of the version to be published, Agree to be accountable for all aspects of the work in ensuring that questions related to the accuracy or integrity of any part of the work are appropriately investigated and resolved

Hamish Raniga – Acquisition of data, Revising the work critically for important intellectual content, Final approval of the version to be published, Agree to be accountable for all aspects of the work in ensuring that questions related to the accuracy or integrity of any part of the work are appropriately investigated and resolved

Yasser Arafat – Design of the work, Revising the work critically for important intellectual content, Final approval of the version to be published, Agree to be accountable for all aspects of the work in ensuring that questions related to the accuracy or integrity of any part of the work are appropriately investigated and resolved

Ryo Mizumoto – Analysis of data, Interpretation of data, Revising the work critically for important intellectual content, Final approval of the version to be published, Agree to be accountable for all aspects of the work in ensuring that questions related to the accuracy or integrity of any part of the work are appropriately investigated and resolved

Tarana Lucky – Design of the work, Drafting the work, Final approval of the version to be published, Agree to be accountable for all aspects of the work in ensuring that questions related to the accuracy or integrity of any part of the work are appropriately investigated and resolved

Sujith Ratnayake – Interpretation of data, Revising the work critically for important intellectual content, Final approval of the version to be published, Agree to be accountable for all aspects of the work in ensuring that questions related to the accuracy or integrity of any part of the work are appropriately investigated and resolved

Guarantor of Submission

The corresponding author is the guarantor of submission.

Source of Support

None.

Consent Statement

Written informed consent was obtained from the patient for publication of this article.

Conflict of Interest

Authors declare no conflict of interest.

Data Availability

All relevant data are within the paper and its Supporting Information files.

Copyright

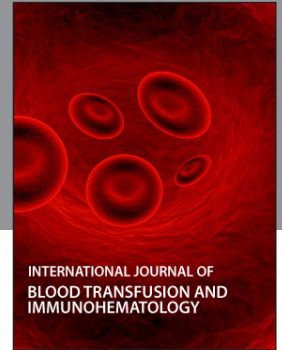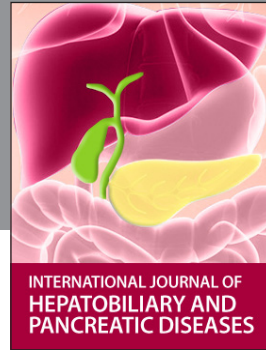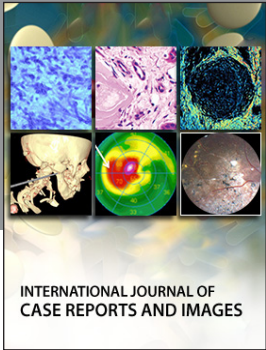
© 2020 Quoc (Ryan) Tran et al. This article is distributed under the terms of Creative Commons Attribution License which permits unrestricted use, distribution and reproduction in any medium provided the original author(s) and original publisher are properly credited. Please see the copyright policy on the journal website for more information.

Access full text article on other devices



Access PDF of article on other devices





Submit your manuscripts at
www.edoriumjournals.com

