

# Mineral and bone disorder leading to a hole in jaw in a patient on peritoneal dialysis

Gurwant Kaur, Ronald Miller, Navin Verma

## CASE REPORT

A 27-year-old man with end-stage renal disease (ESRD) due to prune belly syndrome has been maintained on peritoneal dialysis (PD) for eight years. He was on continuous cyclic peritoneal dialysis (CCPD). His PD prescription included 6 exchanges of 1.7 L fill volume/exchange. He used a mix of 2.5% and 4.25% dextrose solutions on PD. He had long standing history of noncompliance with medications.

On one of his monthly visits to PD clinic; a mass like bony lesion was noticed and it was protruding through his left jaw. This was preceded by tooth pain of variable duration (given poor historian). His routine psychosocial evaluations were negative for homicidal or suicidal thoughts.

His computed tomography (CT) panorex without contrast showed diffusely increased density of bones with multiple expansile lytic lesions; largest lesion of 0.3 × 3.4 × 3.4 cm involved mandible (Figure 1) corresponding to the protruding mass (Figure 2).

Over the last two years, his parathyroid hormone (PTH) had been highest at 3232 pg/mL (Figure 3); it had been difficult to keep under control due to his compliance issues. Intact PTH was now slowly trending down to 1277 pg/mL with improving but still variable compliance with medications. But PTH was still far above goal of 150–600 in ESRD patients. His serum alkaline phosphatase had

been 700–900 units/L; 25-hydroxy vitamin D had been between 6 and 9 ng/mL. His serum phosphorus had been between 5 and 6 mg/dL and recently appeared to be around 4 mg/dL (Figure 4). His serum total calcium had been as lowest as 5.6 mg/dL and had been now between 7 and 8 mg/dL; serum albumin had been improving from 3.5 to 4.5 g/dL.

He was deemed to be not a good candidate for segmental mandibulectomy with reconstruction due to high risk of iatrogenic fracture given poor bone integrity in presence of his severe ESRD-related mineral and bone disorder.

Parathyroidectomy had been difficult to schedule due to his noncompliance with taking calcium or any other medications. He had also been deemed not to be a suitable candidate for transplant due to aforementioned reasons.

In the interval time, he had a left knee patellar fracture after falling from a standing height; and had undergone open reduction and internal fixation.

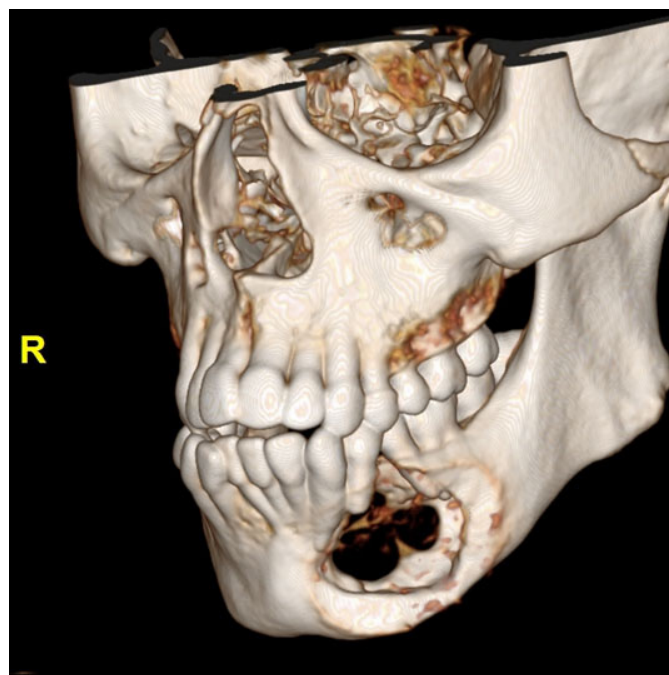


Figure 1: Computed tomography panorex without contrast showed diffusely increased density of bones with multiple expansile lytic lesions; largest lesion of 0.3 × 3.4 × 3.4 cm involved mandible.

Gurwant Kaur<sup>1</sup>, Ronald Miller<sup>2</sup>, Navin Verma<sup>2</sup>

**Affiliations:** <sup>1</sup>Assistant Professor of Medicine, Department of Medicine (Nephrology), Penn State Milton S. Hershey Medical Centre, 500 University Drive, Hershey, Pennsylvania, USA; <sup>2</sup>Associate Professor of Medicine, Department of Medicine (Nephrology), Penn State Milton S. Hershey Medical Centre, 500 University Drive, Hershey, Pennsylvania, USA.

**Corresponding Author:** Dr. Gurwant Kaur, Department of Medicine (Nephrology), Penn State Milton S. Hershey Medical Centre, 500 University Drive, Hershey, Pennsylvania 17033, USA; Email: gkaur1@pennstatehealth.psu.edu

Received: 14 August 2019

Accepted: 11 December 2019

Published: 07 January 2020

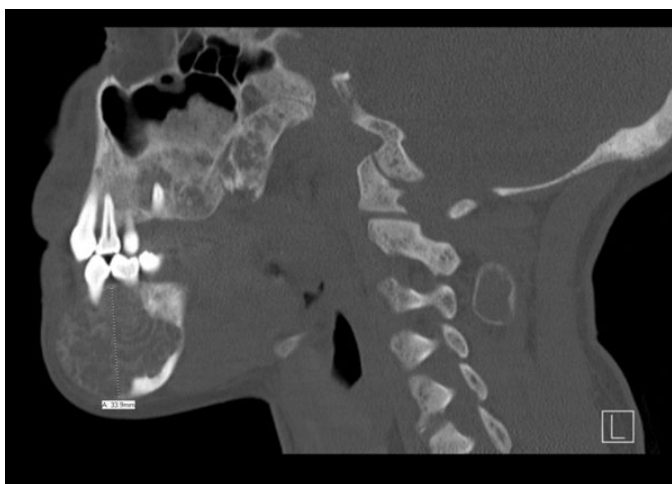

Figure 2: Computed tomography panorex without contrast showed protruding mass corresponding to the lytic lesion as shown in Figure 1.

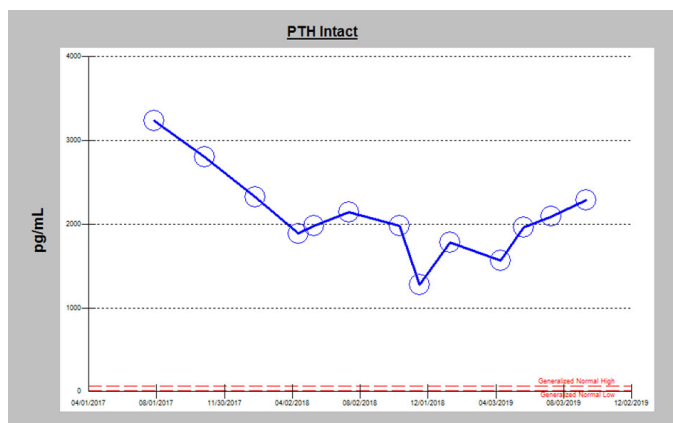


Figure 3: Graph showing trend of serum parathyroid hormone (PTH) levels in pg/mL.

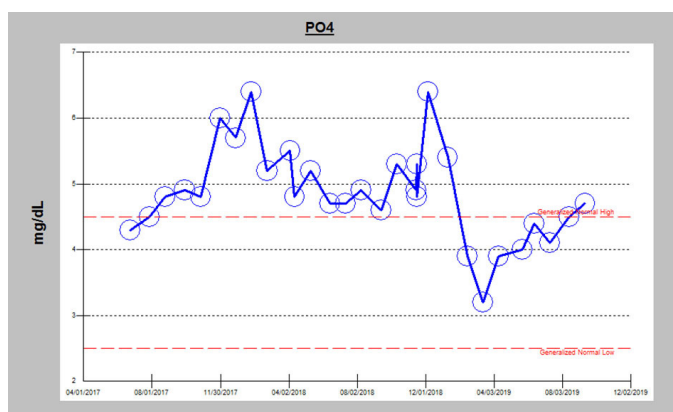


Figure 4: Graph showing trend of serum phosphorus (PO<sub>4</sub>) levels in mg/dL.

## DISCUSSION

As evident from his history, his laboratory findings including calcium, phosphorus, and PTH were very difficult to control and led to manifestations of bone changes. His lesions in mandible were consistent with

renal bone osteodystrophy in the presence of uncontrolled secondary hyperparathyroidism in setting of ESRD. When medical therapy fails or is unable to be successfully implemented as in our case, parathyroidectomy is indicated [1].

Clinical and physical examination along with laboratory data are suggestive of brown tumor; although we do not have a tissue diagnosis given the circumstances explained above. Cranio-facial involvement is relatively rare [2]. There are multiple case reports on this topic in the literature [3], but his bony involvement and images were unique and represent the severity of facial bone involvement.

Overall, ESRD creates a burden of chronicity on patient's life; careful and close monitoring is required in a team-based approach for such patients. His clinical manifestations of mineral and bone disorder were contributed to his noncompliance with medical treatment. However, it is extremely important to explore reasons behind noncompliance. In his case, difficult psychosocial aspects along with chronic and complicated medical history since birth played a major role. He is continued to do PD and makes it to his monthly visits. Now he is starting to interact with our nephrology staff better than before. It involved a great input and close meetings between patient, his family members along with our social worker, dietician and our excellent PD nurses.

## CONCLUSION

End stage renal disease is overall a complex disease and its impact on regulation of mineral and bone health could be significant to have a detrimental impact on individual's ambulation and quality of life. Routine follow-up of PTH, calcium, and phosphorus is part of monthly visits to our PD patients. Team work and patient's involvement are crucial for managing this medically and surgically with parathyroidectomy when indicated.

**Keywords:** Brown tumor, End stage renal disease, Parathyroidectomy, Peritoneal dialysis, Secondary hyperparathyroidism

### How to cite this article

Kaur G, Miller R, Verma N. Mineral and bone disorder leading to a hole in jaw in a patient on peritoneal dialysis. Int J Case Rep Images 2020;11:101084Z01GK2020.

Article ID: 101084Z01GK2020

\*\*\*\*\*

doi: 10.5348/101084Z01GK2020CI

\*\*\*\*\*

**REFERENCES**

1. Pitt SC, Sippel RS, Chen H. Secondary and tertiary hyperparathyroidism, state of the art surgical management. *Surg Clin North Am* 2009;89(5):1227–39.
2. Soundarya N, Sharada P, Prakash N, Pradeep G. Bilateral maxillary brown tumors in a patient with primary hyperparathyroidism: Report of a rare entity and review of literature. *J Oral Maxillofac Pathol* 2011;15(1):56–9.
3. Eroglu E, Kontas ME, Kocyigit I, et al. Brown tumor of the thoracic spine presenting with paraplegia in a patient with peritoneal dialysis. *CEN Case Rep* 2019;8(4):227–32.

\*\*\*\*\*

**Author Contributions**

Gurwant Kaur – Conception of the work, Design of the work, Acquisition of data, Analysis of data, Interpretation of data, Drafting the work, Revising the work critically for important intellectual content, Final approval of the version to be published, Agree to be accountable for all aspects of the work in ensuring that questions related to the accuracy or integrity of any part of the work are appropriately investigated and resolved

Ronald Miller – Conception of the work, Design of the work, Acquisition of data, Analysis of data, Interpretation of data, Drafting the work, Revising the work critically for important intellectual content, Final approval of the version to be published, Agree to be accountable for all aspects of the work in ensuring that questions related to the accuracy or integrity of any part of the work are appropriately investigated and resolved

Navin Verma – Conception of the work, Design of the work, Acquisition of data, Analysis of data, Interpretation of data, Drafting the work, Revising the work critically for important intellectual content, Final approval of the version to be published, Agree to be accountable for all aspects of the work in ensuring that questions related to the accuracy or integrity of any part of the work are appropriately investigated and resolved

**Guarantor of Submission**

The corresponding author is the guarantor of submission.

**Source of Support**

None.

**Consent Statement**

Written informed consent was obtained from the patient for publication of this article.

**Conflict of Interest**

Authors declare no conflict of interest.

**Data Availability**

All relevant data are within the paper and its Supporting Information files.

**Copyright**


© 2020 Gurwant Kaur et al. This article is distributed under the terms of Creative Commons Attribution License which permits unrestricted use, distribution and reproduction in any medium provided the original author(s) and original publisher are properly credited. Please see the copyright policy on the journal website for more information.

Access full text article on other devices



Access PDF of article on other devices





INTERNATIONAL JOURNAL OF CASE REPORTS AND IMAGES



VIDEO JOURNAL OF CLINICAL RESEARCH



VIDEO JOURNAL OF BIOMEDICAL SCIENCE



INTERNATIONAL JOURNAL OF HEPATOBILIARY AND PANCREATIC DISEASES




INTERNATIONAL JOURNAL OF BLOOD TRANSFUSION AND IMMUNOHEMATOLOGY



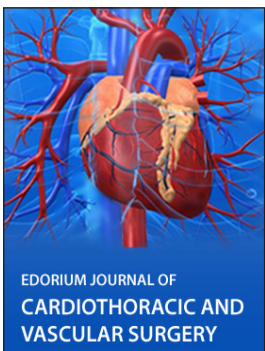EDORIUM JOURNAL OF OPHTHALMOLOGY



**Submit your manuscripts at**  
[www.edoriumjournals.com](http://www.edoriumjournals.com)



EDORIUM JOURNAL OF MEDICINE



EDORIUM JOURNAL OF CARDIOTHORACIC AND VASCULAR SURGERY



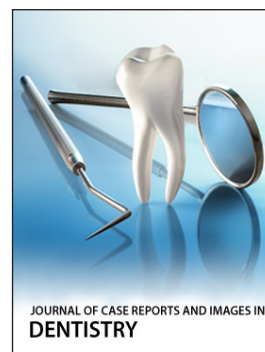JOURNAL OF CASE REPORTS AND IMAGES IN ORTHOPEDICS AND RHEUMATOLOGY



EDORIUM JOURNAL OF PSYCHOLOGY



EDORIUM JOURNAL OF CELL BIOLOGY



JOURNAL OF CASE REPORTS AND IMAGES IN DENTISTRY



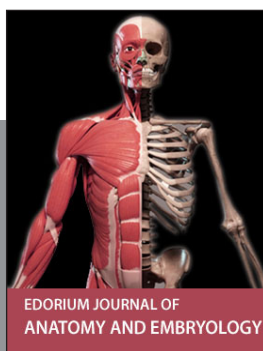EDORIUM JOURNAL OF CANCER



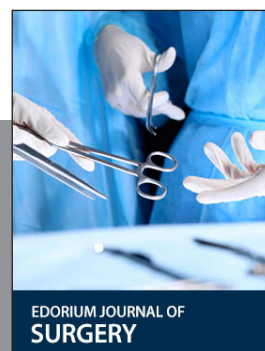
EDORIUM JOURNAL OF PSYCHIATRY



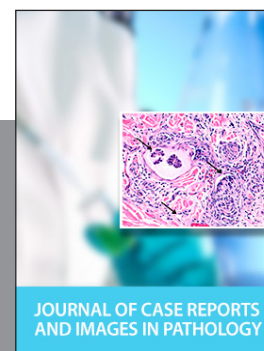JOURNAL OF CASE REPORTS AND IMAGES IN INFECTIOUS DISEASES




EDORIUM JOURNAL OF ANATOMY AND EMBRYOLOGY



EDORIUM JOURNAL OF SURGERY



JOURNAL OF CASE REPORTS AND IMAGES IN PATHOLOGY



EDORIUM JOURNAL OF ANESTHESIA