

CASE REPORT

PEER REVIEWED | OPEN ACCESS

A unique case of small bowel obstruction secondary to internal herniation due to a torted fallopian tube adherent to the sigmoid colon

Ho Nam Choi, Yasser Arafat, Tarana Lucky, Anoj Dharmawardhane

ABSTRACT

Introduction: Internal herniation is a rare cause of small bowel obstruction (SBO). An even less common in females, internal herniation can be secondary to abnormalities of the female reproductive organs in the pelvis. **Case Report:** A 76-year-old female patient presented with acute SBO which did not improve with initial conservative management. The patient was taken to the operating theatre for a laparoscopy revealing that the SBO was caused secondary to an internal herniation through a defect formed by a torted necrotic left fallopian tube adherent to the adjacent sigmoid colon. The patient was successfully treated with a laparoscopic left salingo-oophorectomy. **Conclusion:** Our case describes an unusual mechanism of internal herniation causing SBO in females. This case highlights the importance of considering a broad list of differential diagnoses in causes of SBO, as well as the importance of timely surgical intervention when indicated.

Keywords: Fallopian tube torsion, Internal hernia, Intestinal obstruction, Laparoscopic surgery

Ho Nam Choi¹, Yasser Arafat¹, Tarana Lucky², Anoj Dharmawardhane³

Affiliations: ¹MBBS, Department of Surgery, Toowoomba Hospital, Queensland, Australia; ²MBBS, PhD (Medicine, UNSW), MPH & MHM (UNSW), Lecturer, School of Medicine, Department of Obstetrics and Gynaecology, Toowoomba Hospital, Griffith University, Queensland, Australia; ³MBBS, MS, MMIS, FRACS, Senior Lecturer, Department of Surgery, Toowoomba Hospital, University of Queensland, Queensland, Australia.

Corresponding Author: Ho Nam Choi, Toowoomba Hospital, Pechey Street, Toowoomba, Queensland 4350, Australia; Email: choih@me.com

Received: 16 September 2019

Accepted: 15 October 2019

Published: 11 November 2019

How to cite this article

Choi HN, Arafat Y, Lucky T, Dharmawardhane A. A unique case of small bowel obstruction secondary to internal herniation due to a torted fallopian tube adherent to the sigmoid colon. Int J Case Rep Images 2019;10:101069Z01CN2019.

Article ID: 101069Z01CN2019

doi: 10.5348/101069Z01CN2019CR

INTRODUCTION

Small bowel obstruction is a common cause of surgical emergencies, especially one that requires an operation. In the United Kingdom, SBO was the most frequent indication for which emergency laparotomies were performed, accounting for 37.3% of all emergency laparotomies [1]. Accounting for 0.6–5.8% of cases of SBO, internal hernia is a relatively uncommon cause for this common presentation [2]. An internal hernia can be defined as the protrusion of viscus through a normal or abnormal peritoneal or mesenteric aperture within the confines of the abdominal cavity [3]. These openings may be related to congenital peritoneal defects, or they may be acquired through trauma, postinflammatory adhesions, or surgery [4]. Here, we present a unique case of SBO due to internal herniation of small bowel through a defect formed by a torted left fallopian tube which had become adherent to the sigmoid colon. To our knowledge, this is the first case in the literature to describe this mechanism of internal hernia formation leading to small bowel obstruction.

CASE REPORT

A 76-year-old female patient was brought in by the ambulance to the Emergency Department with a 12-hour

history of central colicky abdominal pain and multiple vomits. Her medical history included a previous ischemic stroke in 2006 with residual dysphagia and left-sided hemiparesis, type 2 diabetes, and dyslipidemia. Her surgical history consisted of previous open appendectomy and laparoscopic cholecystectomy.

On clinical assessment, she had a heart rate of 90 beats per minute, blood pressure of 134/84 mmHg, respiratory rate of 16 breaths per minute, oxygen saturation of 97% on room air, and a temperature of 36.8°C. She had a mildly distended abdomen with tenderness in her lower abdomen without features of peritonism.

Her laboratory investigations showed leukocytosis with a white cell count of $13.0 \times 10^9/L$ with an elevated neutrophil count of $10.3 \times 10^9/L$. She had a serum lactate level of 2.0 mmol/L. Her electrolytes, renal function, and liver function tests were unremarkable. Findings of computed tomography (CT) scan of her abdomen and pelvis were consistent with that of small bowel obstruction with a transition point in the left lower quadrant (Figure 1). There was no CT evidence of perforation, ischemic small bowel, intraperitoneal free fluid, or portal venous gas.

A diagnosis of SBO was made, and an adhesive etiology was thought to be most likely. A nasogastric tube was inserted, and the patient was admitted for a trial of conservative management. However, the patient did not show any signs of improvement over the next 36 hours, as there was ongoing high output from the nasogastric tube. A Gastrografin follow-through study also failed to demonstrate progress of contrast through to the large intestine after 24 hours of administration.

Hence, the patient was taken for a laparoscopy which revealed a loop of ileum that had been incarcerated through an internal hernia defect in the left pelvis created by a torted left fallopian tube which had become adherent to an epiploic appendage of the sigmoid colon. It appeared that an isolated torsion of the left fallopian tube led to its infarction and had subsequently become adherent to the adjacent sigmoid epiploic appendage (Figure 2). The incarcerated loop of ileum, which was still viable, was successfully reduced. A left salpingo-oophorectomy was performed, therefore eliminating the defect which had caused the internal herniation.

The patient made a good recovery postoperatively with a return of her bowel function, and was discharged from the hospital three days after surgery. Histopathologic findings of the left salpingo-oophorectomy specimen were consistent with hemorrhagic necrosis.

DISCUSSION

In females, a defect whereby an internal herniation may occur can be created by abnormalities of the female reproductive organs in the pelvis. These are rare occurrences, however, and examples of such cases

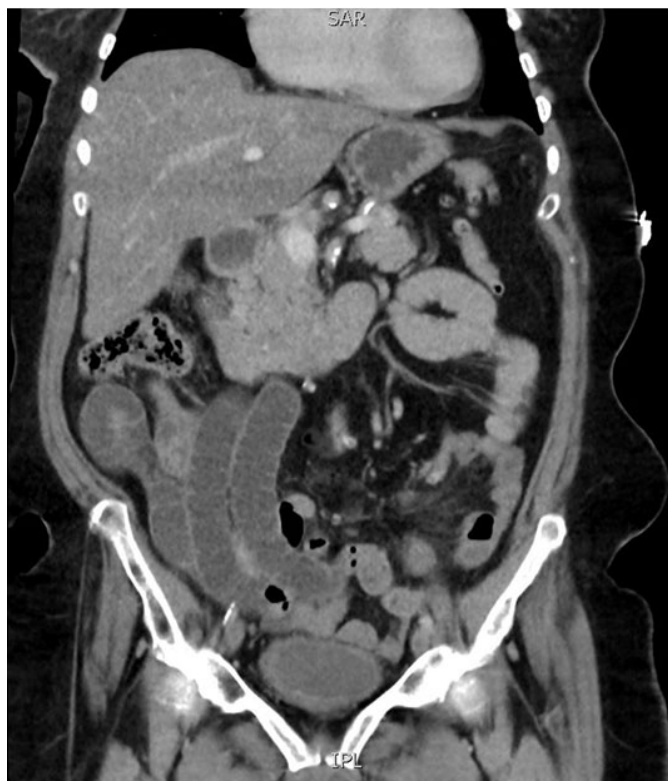

Figure 1: CT image of the abdomen demonstrating collapsed loop of small bowel in the left pelvis, and dilated small bowel in the right abdomen.

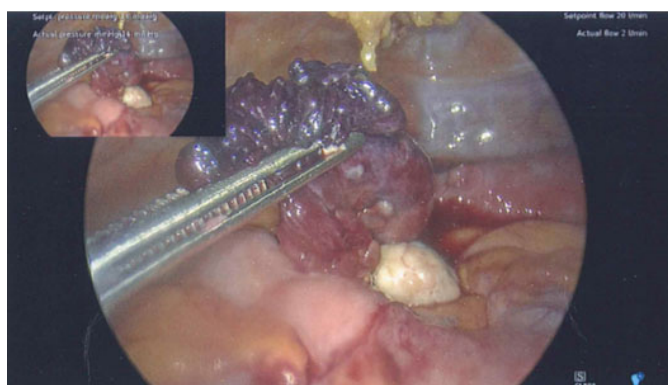


Figure 2: Intraoperative photo showing an ischemic left fallopian tube.

reported in the literature are sparse. They include cases of incarceration of small bowel through a defect in the broad ligament [5], strangulated small bowel caused by an ectopic fallopian tube [6], and a case of incarcerated cecum due to an abnormally elongated fallopian tube where the distal end of the abnormal fallopian tube had become adherent to the parietal peritoneum in the left lower abdominal quadrant [7]. Our case reported here describes another mechanism of internal herniation, which has not been previously described in the literature to the best of our knowledge, whereby a defect was created

by an isolated fallopian tube torsion followed by necrosis and subsequent formation of an inflammatory adhesion to the adjacent sigmoid colon.

Torsion of the fallopian tube is also a rare entity with a reported incidence of 1 in 1,500,000 women [8]. It most commonly affects women in the reproductive age [9], and the torsion is usually associated with an anatomical predisposition, such as ovarian cysts, paratubal cysts, unusually long mesosalpinx, hydrosalpinx, or previous pelvic surgery [10]. Another interesting observation about our case is that the fallopian tube torsion occurred in a postmenopausal patient in the absence of any obvious predisposing anatomical abnormality.

Computed tomography imaging plays a key role in the assessment of patients presenting with SBO, as CT scans can identify a transition point with dilatation of bowel proximally and collapsed bowel distally. It can also detect features of bowel ischemia, such as reduced bowel wall enhancement with intravenous contrast, bowel wall thickening, mesenteric venous congestion, mesenteric fluid, and unusual course of the mesenteric vasculature [11]. In our case, the CT scan correctly identified a transition point in the left lower quadrant without any features of bowel ischemia, although the presence of an internal hernia was not obviously apparent.

The Eastern Association for the Surgery of Trauma (EAST) guideline for evaluation of management of small bowel obstruction recommends early operative intervention for patients presenting with SBO together with features of bowel strangulation and ischemia [11]. Patients with bowel strangulation and ischemia may present with radiological features on CT as previously mentioned, as well as clinical signs which include tachycardia, fever, peritonitis, systemic inflammatory response syndrome (SIRS), leukocytosis, and metabolic acidosis. In the absence of clinical or radiological indicators of bowel ischemia, patients may be safely observed for a trial of nonoperative management, which can be successful in 65–80% of patients [11]. It should be stressed that if a decision for initial nonoperative management is elected, patients should be monitored closely with serial clinical examinations and laboratory investigations. Clinicians should have a low threshold to consider the need for an operation if the patient does not improve with nonoperative management or if they develop signs of bowel ischemia.

CONCLUSION

We present a case of SBO due to herniation of small bowel through an internal hernia defect created by torsion of the left fallopian tube, which had formed an inflammatory adhesion to the adjacent sigmoid colon. This case describes an uncommon etiology for a commonly encountered presenting problem. Our case highlights the importance of close monitoring and

considering the need to operate on those who fail to progress with initial nonoperative management. Our patient's intestinal obstruction would have been unlikely to resolve spontaneously due to the presence of an internal hernia, and further delays may have led to bowel strangulation, ischemia, and perforation.

REFERENCES

1. NELA Project Team. Fourth Patient Report of the National Emergency Laparotomy Audit (NELA). The Royal College of Anaesthetists London. 2018. [Available at: <https://www.hqip.org.uk/wp-content/uploads/2018/11/The-Fourth-Patient-Report-of-the-National-Emergency-Laparotomy-Audit-October-2018.pdf>]
2. Newsom BD, Kukora JS. Congenital and acquired internal hernias: Unusual causes of small bowel obstruction. *Am J Surg* 1986;152(3):279–85.
3. Martin LC, Merkle EM, Thompson WM. Review of internal hernias: Radiographic and clinical findings. *AJR Am J Roentgenol* 2006;186(3):703–17.
4. Mathieu D, Luciani A; GERMAD Group. Internal abdominal herniations. *AJR Am J Roentgenol* 2004;183(2):397–404.
5. Cameron M, Janakan G, Birch D, Nazir S. A closed loop obstruction caused by entrapment of the fallopian tube and herniation through the broad ligament. *Int J Surg Case Rep* 2015;12:57–9.
6. Bugmann P, Hanquinet S, Brundler MA, Birraux J, Genin B, Le Coultre C. Intestinal obstruction caused by an ectopic fallopian tube in a child: Case report and literature review. *J Pediatr Surg* 2001;36(3):508–10.
7. Forsythe CM, Sanchirico PJ, Pfeiffer DC. Internal hernia with incarceration of the cecum through a loop created by an elongated fallopian tube. *Radiol Case Rep* 2018;14(2):282–6.
8. Rajaram S, Nigam S, Goel N. Fallopian tube torsion: A rare emergency. *Journal of Gynecologic Surgery* 2011;27(1):41–2.
9. Hansen OH. Isolated torsion of the Fallopian tube. *Acta Obstet Gynecol Scand* 1970;49(1):3–6.
10. Dueholm M, Praest J. Isolated torsion of the normal fallopian tube. *Acta Obstet Gynecol Scand* 1987;66(1):89–90.
11. Maung AA, Johnson DC, Piper GL, et al. Evaluation and management of small-bowel obstruction: An Eastern Association for the Surgery of Trauma practice management guideline. *J Trauma Acute Care Surg* 2012;73(5 Suppl 4):S362–9.

Author Contributions

Ho Nam Choi – Conception of the work, Design of the work, Acquisition of data, Drafting the work, Final approval of the version to be published, Agree to be accountable for all aspects of the work in ensuring that questions related to the accuracy or integrity of any part of the work are appropriately investigated and resolved

Yasser Arafat – Conception of the work, Revising the work critically for important intellectual content, Final approval of the version to be published, Agree to be accountable for all aspects of the work in ensuring that questions related to the accuracy or integrity of any part of the work are appropriately investigated and resolved

Tarana Lucky – Interpretation of data, Revising the work critically for important intellectual content, Final approval of the version to be published, Agree to be accountable for all aspects of the work in ensuring that questions related to the accuracy or integrity of any part of the work are appropriately investigated and resolved

Anoj Dharmawardhane – Conception of the work, Design of the work, Acquisition of data, Analysis of data, Interpretation of data, Drafting the work, Revising the work critically for important intellectual content, Final approval of the version to be published, Agree to be accountable for all aspects of the work in ensuring that questions related to the accuracy or integrity of any part of the work are appropriately investigated and resolved

Guarantor of Submission

The corresponding author is the guarantor of submission.

Source of Support

None.

Consent Statement

Written informed consent was obtained from the patient for publication of this article.

Conflict of Interest

Authors declare no conflict of interest.

Data Availability

All relevant data are within the paper and its Supporting Information files.

Copyright

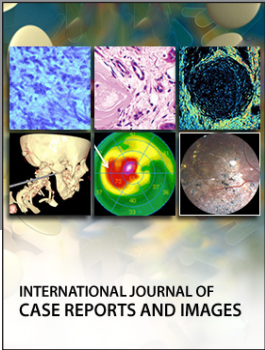
© 2019 Ho Nam Choi et al. This article is distributed under the terms of Creative Commons Attribution License which permits unrestricted use, distribution and reproduction in any medium provided the original author(s) and original publisher are properly credited. Please see the copyright policy on the journal website for more information.

Access full text article on
other devices



Access PDF of article on
other devices





Submit your manuscripts at
www.edoriumjournals.com

