

# Peritoneal pseudomyxoma of appendicular origin: A case report and review of the literature

Malika Amarir, Babahabib Moulay Abdellah,  
Meryam Edderai, Hassan Ennouali

## ABSTRACT

**Introduction:** Peritoneal pseudomyxoma (PPM) is a rare disease. The computerized tomography (CT) aspect is not only typical but also well known. In addition, the scalloping deformity of the hepatic and splenic contours by the mucinous substance is considered pathognomonic of the disease. **Case Report:** We report a case of a PPM, in which the initial diagnosis was made by an abdominal-pelvic magnetic resonance imaging (MRI). **Conclusion:** The CT appearance of the PPM is both usual and popular. Moreover, it is used for the diagnosis and the follow-up. The MRI aspect of these lesions is limited. Besides, it is carried out mainly in the follow-up of known PPM cases. However, in our case the initial diagnosis was established by the MRI.

**Keywords:** Abdominal pain, Appendicular mucocele, Magnetic resonance imaging, Peritoneal pseudomyxoma

Article ID: 101058Z01MA2019

\*\*\*\*\*

doi: 10.5348/101058Z01MA2019CR

## INTRODUCTION

The PPM is a rare disease. Furthermore, in every one million of persons one of them gets this disease or in every ten thousand of laparotomies two people of them can be affected by this illness [1]. The CT aspect is a really common type and is generally used for the diagnosis and the follow-up [2]. The MRI aspect of these lesions is limited to a few cases published in the literature [3, 4]. Moreover, the CT is usually practiced in the follow-up of the cases of the PPM. However, in our case the initial diagnosis was established by the MRI. We report a case where the initial positive and etiological diagnosis of PPM is made by the MRI.

## CASE REPORT

A 66-year-old menopausal diabetic woman was operated for umbilical hernia five years ago. She had pelvic pain without any other signs and for that she was sent to our radiology service by her gynecologist for a cystic mass of the right iliac fossa, with ascites, discovered on the ultrasound, whose gynecological or digestive origin was not evident. A pelvic MRI was realized on a 1.5 Tesla machine in a surface antenna, many sequences were made in the three planes of space, including T2-weighted single shot fast spin echo (SSFSE), sequences with and without fat-suppressed signal, sequences T1-weighted spoiled gradient-recalled acquisition in steady state (SPGR), with and without fat signal suppression, and sequences before and after intravenous injection of paramagnetic contrast. The diagnosis was established by the presence of a cystic formation at the right iliac fossa contiguous to the appendix with a thin wall enhanced after injection and open in the large peritoneal cavity (Figures 1 and 2) with moderate-abundant ascites in T2

### How to cite this article

Amarir M, Abdellah BM, Edderai M, Ennouali H. Peritoneal pseudomyxoma of appendicular origin: A case report and review of the literature. Int J Case Rep Images 2019;10:101058Z01MA2019.

Malika Amarir<sup>1</sup>, Babahabib Moulay Abdellah<sup>2</sup>, Meryam Edderai<sup>1</sup>, Hassan Ennouali<sup>1</sup>

**Affiliations:** <sup>1</sup>Radiology Department, Mohammed V Military Teaching Hospital, Faculty of Medicine, Mohammed V University, Rabat, Morocco; <sup>2</sup>Gynecology Obstetrics Service, Mohammed V Military Training Hospital, Faculty of Medicine, Mohammed V University, Rabat, Morocco.

**Corresponding Author:** Malika Amarir, Radiology Department, Mohammed V Military Teaching Hospital, Faculty of Medicine, Mohammed V University, Rabat, Morocco; Email: amarirma@gmail.com

Received: 31 July 2019

Accepted: 02 September 2019

Published: 09 October 2019

hyper signal (Figure 3) and T1 hyposignal. The substance that filled the peritoneal cavity pushed the intestine back to the center, the large epiploon was thickened and intensely enhanced after intravenous injection of contrast medium. Evoking a perforated mucocele (Figure 1), note that the ovaries were without abnormalities especially the right ovary (Figure 4). The patient underwent a radical tumor reduction surgery consisting of the excision of the maximum mucus of the appendix mucocele with omentectomy, localized peritonectomies, right partial hemicolectomy, and bilateral ovariectomy (Figure 5) with intraoperative chemohyperthermia. The pathological

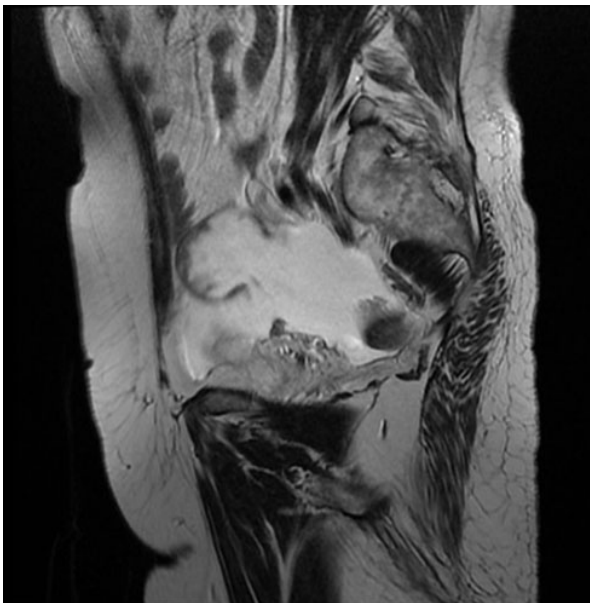


Figure 1: MRI T2-weighted sagittal cut showing cystic formation in the right iliac fossa with a hypointense thin-walled, open in the large peritoneal cavity with ascites of moderate abundance.

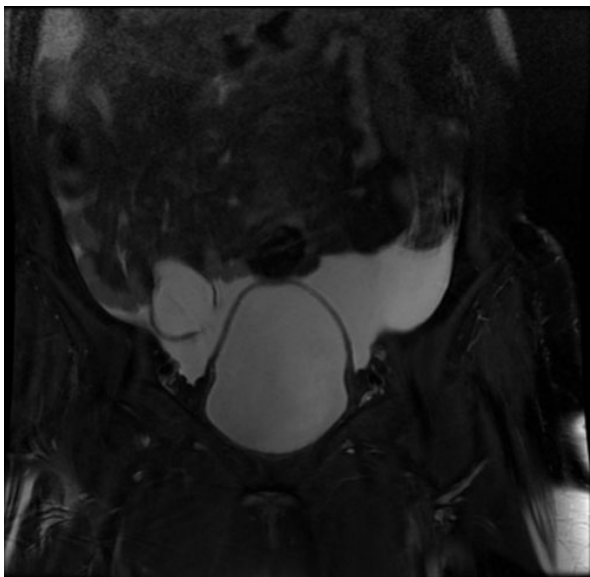


Figure 2: MRI T2-weighted coronal cut with fat suppression showing cystic formation in the right iliac fossa, contiguous to the appendix, thin-walled, and open in the large peritoneal cavity with ascites of moderate abundance.

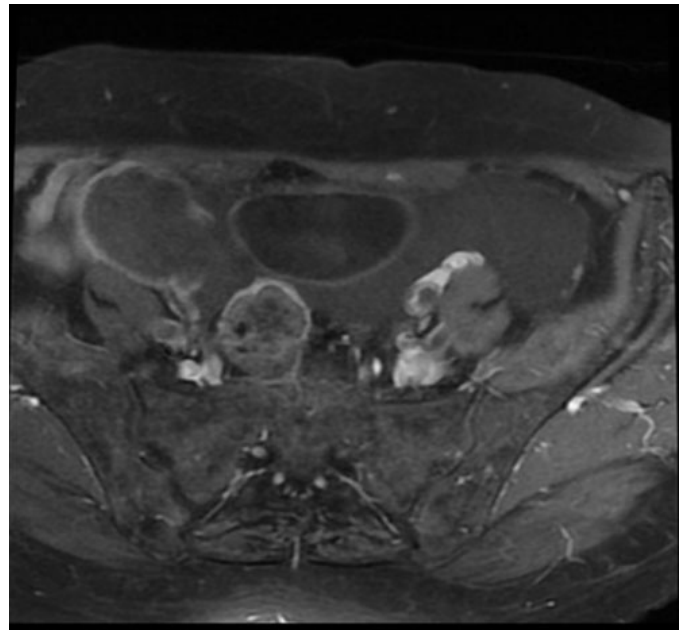


Figure 3: T1-weighted axial MRI after gadolinium injection, showing contrast enhancement of the cystic wall of the ruptured appendicular mucocele at the level of the right iliac fossa and open in the large peritoneal cavity with moderately abundant ascites.

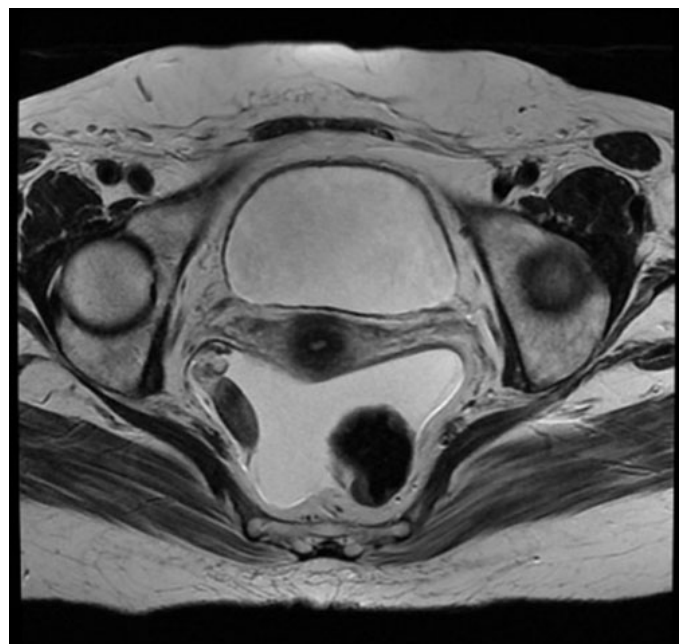


Figure 4: T2-weighted axial MRI showing the right ovary without abnormality.

examination confirmed the diagnosis of a perforated low-grade mucocele with a low risk of recurrence and extra-appendicular deposition of acellular mucins.

## DISCUSSION

The PPM is a really uncommon illness [1], it is found in the majority of cases from the dissemination in the

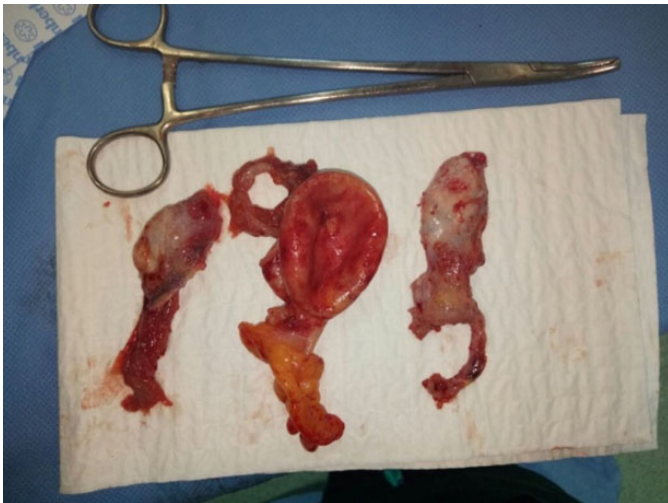

Figure 5: Operative piece of tumourectomy and ovariectomy.

peritoneum of a gelatinous substance, made of mucus, mucin, and epithelial cells [2], complicating a rupture of an appendicular mucocele which designates an appendix distended by hypersecretion of mucus. This hypersecretion is produced by: a retentive cyst, a benign mucinous tumor (cystadenoma), or a malignant tumor (cystadenocarcinoma) of the appendix. This substance continues to accumulate in the subdiaphragmatic and right subhepatic region, in the left parieto-colic gutter, the big epiploon and the pelvis [1, 3]. Uncomplicated mucocele is often silent and accidentally discovered during surgery. Its rupture can give a pain to the right iliac fossa that mimics the acute appendicitis but most often it is silent and fortuitous discovery. The clinical presentation of the PPM will therefore often be nonspecific [1]. Blood tests have no role for diagnosis.

In imaging the unprepared abdomen shot may show an opacity predominant on one side of the abdomen that is significant if it is associated with calcifications at the periphery of the opacity. Ultrasound reveals an ovoid mass of the right iliac fossa which contains fine linear echoes, peripheral calcifications are possible [5]. In CT scan the aspect is considered currently pathognomonic by most authors [2, 6], the deformation or scalloping of hepatic and splenic contours by the mucinous substance is considered pathognomonic of PPM. In its most malignant form, it can invade the small intestine and its mesentery. Some authors consider that the benign form can be differentiated on the CT of the malignant form by the absence or presence of peritoneal tissue nodules associated with the gelatinous substance [2, 7]. These signs are also [3] visible in MRI. Currently, MRI is becoming increasingly important in abdominal imaging. The appearance of an appendicular mucocele broken on MRI has already been described [8]. It appears as well on the T2 sequences as on the injected sequences as well as the site of the appendicular breach. There are essentially two main types of surgical management of PMP: debulking, progressive reduction surgery, and

cytoreduction surgery, currently recommended, with hyperthermal intraperitoneal chemotherapy followed or not by intraperitoneal chemotherapy [1, 9] immediate postoperative.

## CONCLUSION

The CT stills the most appropriate test for the diagnosis and the follow-up of patients with PPM. However, the MRI aspect of these lesions must be known because the radiologist may be confronted with an MRI done at first. In our case, we do not have a confrontation between the CT and the MRI but it is possible that the MRI provides more information than the CT in the mucocele with a high malignancy potential by showing microcystic images and wall's nodules, also the MRI can provide information about uterine invasion or possibly other organs. In addition, it can replace the CT in case of contraindication to the injection of iodine.

## REFERENCES

1. Loungnarath R, Causeret S, Brigand C, Gilly FN, Glehen O. Pseudomyxoma peritonei: New concept and new therapeutic approach. [Article in French]. *Ann Chir* 2005;130(2):63–9.
2. Buy JN, Malbec L, Ghossain MA, Guinet C, Ecoiffier J. Magnetic resonance imaging of pseudomyxoma peritonei. *Eur J Radiol* 1989;9(2):115–8.
3. Ronnett BM, Shmookler BM, Diener-West M, Sugarbaker PH, Kurman RJ. Immunohistochemical evidence supporting the appendiceal origin of pseudomyxoma peritonei in women. *Int J Gynecol Pathol* 1997;16(1):1–9.
4. Takeuchi M, Matsuzaki K, Yoshida S, Nishitani H, Uehara H. Imaging findings of urachal mucinous cystadenocarcinoma associated with pseudomyxoma peritonei. *Acta Radiol* 2004;45(3):348–50.
5. Derelle AL, Tissier S, Granger P, et al. Diagnostic précoce de pseudomyxome péritonéal localisé à la zone de rupture d'une mucocele appendiculaire: Imagerie et aspects anatomopathologiques. *J Radiol* 2007;88:289–95.
6. Stewart CJ, Tsukamoto T, Cooke B, Leung YC, Hammond IG. Ovarian mucinous tumour arising in mature cystic teratoma and associated with pseudomyxoma peritonei: Report of two cases and comparison with ovarian involvement by low-grade appendiceal mucinous tumour. *Pathology* 2006;38(6):534–8.
7. Szych C, Staebler A, Connolly DC, Wu R, Cho KR, Ronnett BM. Molecular genetic evidence supporting the clonality and appendiceal origin of Pseudomyxoma peritonei in women. *Am J Pathol* 1999;154(6):1849–55.
8. Ronnett BM, Zahn CM, Kurman RJ, Kass ME, Sugarbaker PH, Shmookler BM. Disseminated peritoneal adenomucinosis and peritoneal mucinous carcinomatosis. A clinicopathologic analysis of 109 cases with emphasis on distinguishing pathologic



features, site of origin, prognosis, and relationship to “pseudomyxoma peritonei”. Am J Surg Pathol 1995;19(12):1390–408.

9. O’Connell JT, Tomlinson JS, Roberts AA, McGonigle KF, Barsky SH. Pseudomyxoma peritonei is a disease of MUC2-expressing goblet cells. Am J Pathol 2002;161(12):551–64.

\*\*\*\*\*

**Author Contributions**

Malika Amarir – Acquisition of data, Drafting the work, Revising the work critically for important intellectual content, Final approval of the version to be published, Agree to be accountable for all aspects of the work in ensuring that questions related to the accuracy or integrity of any part of the work are appropriately investigated and resolved

Babahabib Moulay Abdellah – Acquisition of data, Drafting the work, Revising the work critically for important intellectual content, Final approval of the version to be published, Agree to be accountable for all aspects of the work in ensuring that questions related to the accuracy or integrity of any part of the work are appropriately investigated and resolved

Meryam Edderai – Acquisition of data, Drafting the work, Revising the work critically for important intellectual content, Final approval of the version to be published, Agree to be accountable for all aspects of the work in ensuring that questions related to the accuracy or integrity of any part of the work are appropriately investigated and resolved

Hassan Ennouali – Acquisition of data, Drafting the work, Revising the work critically for important intellectual content, Final approval of the version to be published, Agree to be accountable for all aspects of the work in ensuring that questions related to the accuracy or integrity of any part of the work are appropriately investigated and resolved

**Guarantor of Submission**

The corresponding author is the guarantor of submission.

**Source of Support**

None.

**Consent Statement**

Written informed consent was obtained from the patient for publication of this article.

**Conflict of Interest**

Authors declare no conflict of interest.

**Data Availability**

All relevant data are within the paper and its Supporting Information files.

**Copyright**



© 2019 Malika Amarir et al. This article is distributed under the terms of Creative Commons Attribution License which permits unrestricted use, distribution and reproduction in any medium provided the original author(s) and original publisher are properly credited. Please see the copyright policy on the journal website for more information.

Access full text article on other devices



Access PDF of article on other devices





**Submit your manuscripts at**  
[www.edoriumjournals.com](http://www.edoriumjournals.com)

