

# Respiratory failure concealing an esotracheal fistula in a 27-year-old patient followed for Hodgkin's lymphoma, at an advanced stage, having received radiochemotherapy: A case report and review of the literature

Yassine Smiti, Oussama Sounni, Achraf Mouden, Ghannam Abdelilah, Brahim El Ahmadi, Zakaria Belkhadir, Lamyae Kallouch, Omor Youssef, Latib Rachida

## ABSTRACT

**Introduction:** Esotracheal fistulas in adults are rare (fewer than 30 cases in the literature) and few cases have been reported in recent years. Hodgkin's disease with esotracheal fistula is extremely rare. The diagnosis can be established by esophageal and/or tracheal endoscopy. The diagnosis can also be corroborated by direct visualization of a fistulous pathway or oral contrast swallow associated with computed tomography (CT) imaging. **Case Report:** We present the case of a 27-year-old patient followed for Hodgkin's disease, admitted to the emergency room with respiratory failure. He did not respond to treatment by mechanical ventilation. His paraclinical investigations revealed an esotracheal fistula. **Conclusion:** Esotracheal or esobronchial fistula could be seen with any of the classical Hodgkin's lymphoma subtypes. It could also be a complication of either radiotherapy (RT) or chemotherapy for Hodgkin's lymphoma which is an extremely rare event. The majority of fistulas occurred in the upper two-thirds

of the esophagus, and 67% treated solely with chemotherapy and/or RT closed without surgical intervention. In the case of our patient, the rapidly degenerative evolution of respiratory state did not give us time to do esogastric fibroscopy and manage the fistula. If we had extracorporeal membrane oxygenation (ECMO) we could be more efficient for those patients.

**Keywords:** Esotracheal fistula, Hodgkin's lymphoma, Respiratory distress

### How to cite this article

Smiti Y, Sounni O, Mouden A, Abdelilah G, El Ahmadi B, Belkhadir Z, Kallouch L, Youssef O, Rachida L. Respiratory failure concealing an esotracheal fistula in a 27-year-old patient followed for Hodgkin's lymphoma, at an advanced stage, having received radiochemotherapy: A case report and review of the literature. Int J Case Rep Images 2019;10:101051Z01YS2019.

Yassine Smiti<sup>1</sup>, Oussama Sounni<sup>1</sup>, Achraf Mouden<sup>1</sup>, Ghannam Abdelilah<sup>1</sup>, Brahim El Ahmadi<sup>1</sup>, Zakaria Belkhadir<sup>1</sup>, Lamyae Kallouch<sup>2</sup>, Omor Youssef<sup>1</sup>, Latib Rachida<sup>1</sup>

**Affiliations:** <sup>1</sup>National Institute of Oncology, Anesthesiology and Resuscitation Department, Ibn Sina Hospital, Mohamed V University, Rabat, Morocco; <sup>2</sup>Department of Radiology, National Institute of Oncology, Morocco.

**Corresponding Author:** Yassine Smiti, National Institute of Oncology, Ibn Sina Hospital, Mohamed V University, Rabat, Morocco; Email: yassin.smiti@gmail.com

Received: 28 June 2019  
Accepted: 26 August 2019  
Published: 27 September 2019

Article ID: 101051Z01YS2019

\*\*\*\*\*

doi: 10.5348/101051Z01YS2019CR

## INTRODUCTION

Esotracheal fistulas in adults are rare (fewer than 30 cases in the literature) and few cases have been reported in recent years [1].

Hodgkin's disease with any sort of fistula formation is extremely rare. Esophageal fistulas have been reported

infrequently in the English literature since Vieta and Craver described three patients with advanced Hodgkin's disease seen at the Memorial Hospital from 1917 to 1940 with this finding [2]. We report the case of a young patient followed for Hodgkin's lymphoma associated to an esotracheal fistula.

## CASE REPORT

A 27-year-old patient, followed for stage IV Hodgkin's lymphoma, consulted in the emergency room for dyspnea, having as antecedent a Hodgkin's lymphoma diagnosed when he was 25 years old and having received two chemotherapy sessions, the last one dating back to one month before his symptomatology.

The physical examination showed the following:

- Respiratory rate: 36 cycle/min
- Pulsed oximetry: 80% under 6 L of oxygen
- Heart rate: 133 bpm
- Blood pressure: 64/34 mmHg
- Glasgow score: 6
- Fever: 39.5°C

His arterial blood gas test showed a severe metabolic acidosis pH: 7.1 with  $\text{HCO}_3^-$ : 14 mmol/L, hypoxemia  $\text{PaO}_2$  at 50 mmHg with hyperlactatemia 3.8 mmol/L and anemia at 6 g/dL.

The patient was admitted from the emergency room to the intensive care unit, where his ventilation was first ensured via an oxygen mask at high concentration. Then we took an arterial line for continuous monitoring of blood pressure and put in place a femoral vein cannulation to administer vasoactive drugs. The patient also received a blood transfusion and sodium bicarbonate in order to stabilize his blood pressure.

A nasogastric tube was put in place with aspiration of gastric content, then put in siphoning mode. We noticed the bag quickly inflating with air. An orotracheal intubation after stabilization of the blood pressure was performed with mechanical ventilation in controlled mode. The patient then received a thoracic CT scan which revealed a massive left pleural fluid effusion and a stomach full of air (Figure 1).

Then the patient had a chest drainage, which brought back 5 L of purulent fluid, with a control X-ray showing the drain in place and the lung returning to the chest wall, which was then confirmed by ultrasound (Figure 2).

Due to the persistence of desaturation, the need for increased noradrenaline doses, a bag of siphonage connected to the nasogastric tube full of air confirmed by imagery, it was decided to perform a bronchial fibroscopy, a nasogastric fibroscopy and to review the CT scan reconstruction sections (Figure 3).

The bronchial fibroscopy showed a left bronchus full of inflammatory granuloma while the right bronchus was unexplorable, probably because of the fistula confirmed by the CT scan which showed a right esobronchial fistula. Unfortunately, the patient died before we could conduct an esogastric fibroscopy. We could not achieve

any selective intubation because of the right esobronchial fistula and the destroyed left lung. One of the possible alternatives was the ECMO, which we did not have at our disposal.

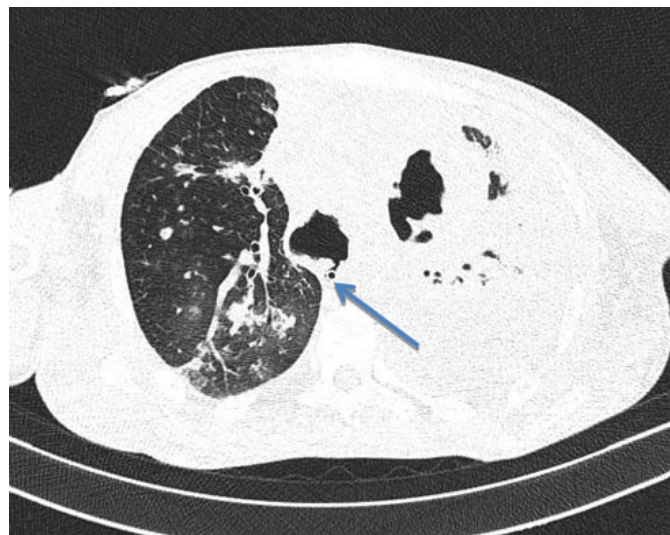

Figure 1: Pleural effusion of great abundance with mediastinal adenopathies.

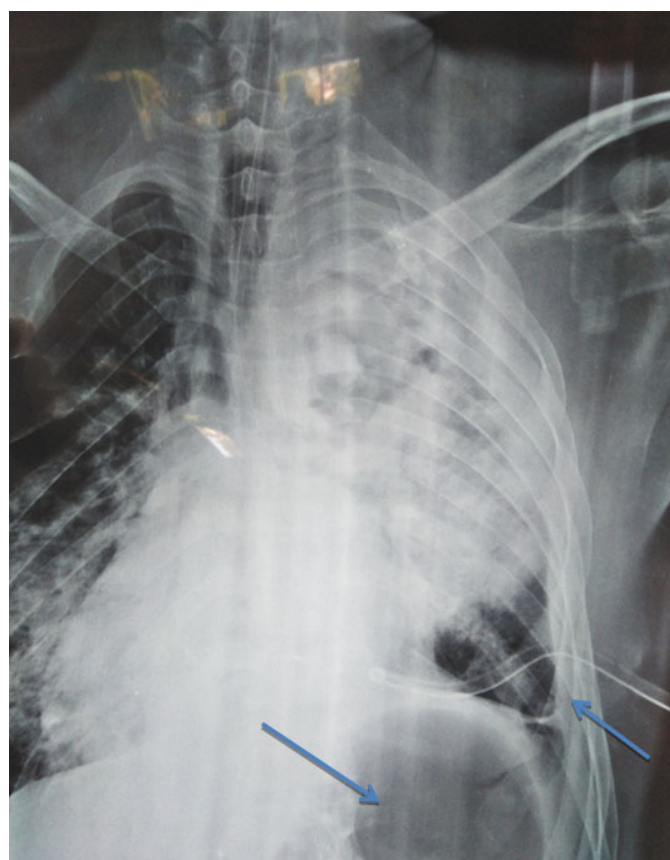

Figure 2: Chest X-ray showing a drain in place with lung returning to the chest wall and a stomach full of air.

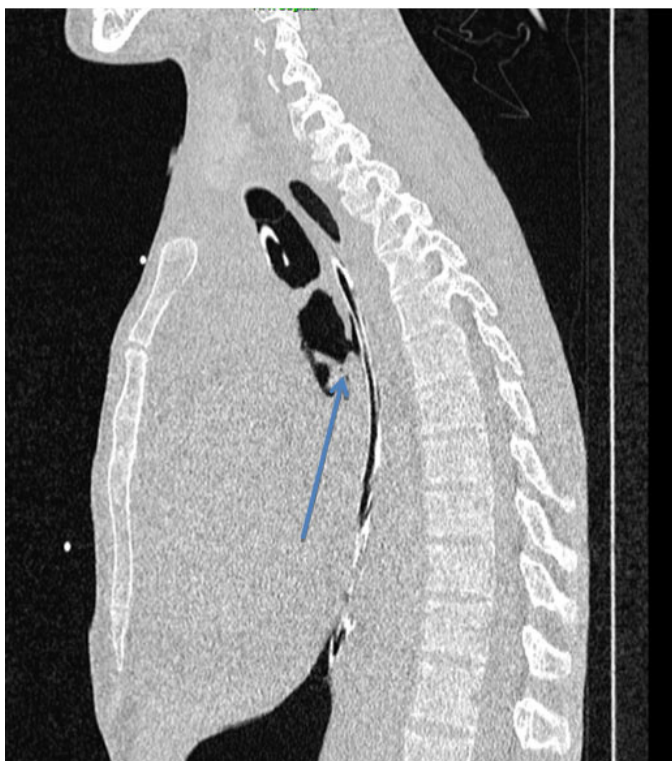


Figure 3: Esotracheal fistula on CT scan reconstruction sections.

## DISCUSSION

### Esotracheal fistulas and Hodgkin's lymphoma

- Hodgkin's disease with any sort of fistula formation is extremely rare. Esophageal fistulas have been reported infrequently in the English literature since Vieta and Craver described three patients with advanced Hodgkin's disease seen at the Memorial Hospital from 1917 to 1940 with this finding [2].
- A total of 22 patients with Hodgkin's disease causing esophageal fistula have been described previously in the English literature [2, 3].

Most patients had an advanced lymphoma with recurrence (eight patients) or a stage IIIB/IV lymphoma (five patients) when the fistula was diagnosed.

- Fistulas formed most often in the upper two-thirds of the esophagus, resulting most commonly in tracheoesophageal communications [4].
- Fistula formation as a complication of either RT or chemotherapy for Hodgkin's disease is an extremely rare event. Only two patients described in the literature had such an occurrence [5, 6].

In our case, the fistula was probably formed as a result of RT, it was responsible for the death of our patient since the other decompensation was managed, namely drainage of the pyothorax, disappearance of the fever

under antibiotherapy, improvement of its hemodynamic state by noradrenaline and blood transfusion.

- Malignant esotracheal fistulas are rare, they are commonly seen with esophageal or lung cancer, which are associated with a high mortality rate [7, 8].
- A literature review reported a total of 22 patients with Hodgkin's lymphoma and a tracheoesophageal fistula. It showed that the fistula could be seen with any of the classical Hodgkin's lymphoma subtypes. Usually, it is also associated with an active disease at the site of fistula [4].

However, esotracheal fistulas could be developed from rapid tumor necrosis during RT or chemotherapy. It could also be seen as a late complication of RT because of the erosion of scar tissue [9].

- Two-thirds of fistulas occurred in the upper two-thirds of the esophagus, and 67% of fistulas closed without surgical intervention, just with chemotherapy and/or RT [4, 10].

### Management and treatment

- The most important feature of management of tracheoesophageal fistulas is early identification and initiation of therapy. The recommended initial therapy is placement of a stent, either in the trachea or esophagus [11].
- Stenting prevents further damage to the respiratory tract and thus decreases the risk of pneumonia or respiratory compromise to allow for malignancy specific therapy. In addition, feeding via a gastrostomy tube further reduces the risk of pulmonary soilage, aspiration pneumonia, and mediastinitis.
- Extracorporeal membrane oxygenation can give the patient more chances, especially refractive hypoxemia. This technique uses a membrane gas exchanger. By extension, the ECMO has become a respiratory and cardiorespiratory assistance technique used in case of respiratory failure and/or cardiac failure while waiting for the restoration of a normal respiratory state or a possible transplantation.

Its use is easy, quick, and can be initiated in the bed of the patient.

Some thoracic surgery centers use it routinely as assistance to the realization of lung transplantation and also some intensive care unit teams use it for the treatment of acute respiratory distress syndrome [12].

In our case, the patient died because of the refractive hypoxemia even with 100% of FiO<sub>2</sub> in the mechanic ventilation, the ECMO would give us more time to treat the fistula and save our patient.



## Prognosis

Tracheal fistulas complicating Hodgkin's lymphoma are rare and have a much better prognosis than fistulas of other malignancies [8].

## CONCLUSION

Esotracheal or esobronchial fistula could be seen with any of the classical Hodgkin's lymphoma subtypes. It could also be a complication of either RT or chemotherapy for Hodgkin's lymphoma which is an extremely rare event. The majority of fistulas occurred in the upper two-thirds of the esophagus, and 67% treated solely with chemotherapy and/or RT closed without surgical intervention. In the case of our patient, the rapidly deteriorating evolution of his respiratory state did not give us the time to perform an esogastric endoscopy and manage the fistula. If we had ECMO we could have a better evolution.

## REFERENCES

1. Zacharias J, Genc O, Goldstraw P. Congenital tracheoesophageal fistulas presenting in adults: Presentation of two cases and a synopsis of the literature. *J Thorac Cardiovasc Surg* 2004;128(2):16–8.
2. Vieta JO, Craver LF. Intrathoracic manifestations of the lymphomatoid diseases. *Radiology* 1941;37(2):138–58.
3. Zenny JC, Grenier P, Favier H, Bernard JF, Nahum H. Hodgkin's disease revealed by an esophagotracheal fistula (author's transl). [Article in French]. *J Radiol* 1981;62(3):191–5.
4. Greven KM, Evans LS. The occurrence and management of esophageal fistulas resulting from Hodgkin's disease. *Cancer* 1992;69(4):1031–3.
5. Mellins RB. Acquired fistula between the esophagus and the respiratory tract; report of a case, review of the literature and discussion of the pathogenesis. *N Engl J Med* 1952;246(23):896–901.
6. Katin MJ, Brereton HD, Michaelis LL. Surgical repair of esophagobronchial fistula following successful treatment of Hodgkin's disease. *Cancer* 1979;44(3):1121–4.
7. Van de Water JM, Katz RI, Hughes RK. Management of patients with acquired malignant esophagorespiratory fistulas. *Am Surg* 1965;31(10):629–33.
8. Burt M, Diehl W, Martini N, et al. Malignant esophagorespiratory fistula: Management options and survival. *Ann Thorac Surg* 1991;52(6):1222–8; discussion 1228–9.
9. Ling D, Bushunow P. Tracheoesophageal fistula in a patient with recurrent Hodgkin's disease: A case for hope or despair. *Chest* 1996;109(3):850–1.
10. Munshi A, Pandey MB, Kumar L, Karak AK, Mohanti BK. A case of Hodgkin's disease presenting with recurrent laryngeal nerve palsy and tracheoesophageal fistula. *Med J Malaysia* 2006;61(1):97–9.

11. Burt M. Management of malignant esophagorespiratory fistula. *Chest Surg Clin N Am* 1996;6(4):765–76.
12. Falcoz PE, Capellier G. Principes et indications de l'ECMO en pathologie pulmonaire de l'adulte. *EMC - Techniques Chirurgicales - Thorax* 2009;4(2):1–14.

\*\*\*\*\*

## Author Contributions

Yassine Smiti – Conception of the work, Design of the work, Acquisition of data, Analysis of data, Drafting the work, Final approval of the version to be published, Agree to be accountable for all aspects of the work in ensuring that questions related to the accuracy or integrity of any part of the work are appropriately investigated and resolved

Oussama Sounni – Conception of the work, Design of the work, Acquisition of data, Drafting the work, Final approval of the version to be published, Agree to be accountable for all aspects of the work in ensuring that questions related to the accuracy or integrity of any part of the work are appropriately investigated and resolved

Achraf Mouden – Conception of the work, Design of the work, Acquisition of data, Analysis of data, Drafting the work, Final approval of the version to be published, Agree to be accountable for all aspects of the work in ensuring that questions related to the accuracy or integrity of any part of the work are appropriately investigated and resolved

Ghannam Abdelilah – Conception of the work, Design of the work, Acquisition of data, Analysis of data, Drafting the work, Final approval of the version to be published, Agree to be accountable for all aspects of the work in ensuring that questions related to the accuracy or integrity of any part of the work are appropriately investigated and resolved

Brahim El Ahmadi – Conception of the work, Design of the work, Acquisition of data, Analysis of data, Revising the work critically for important intellectual content, Final approval of the version to be published, Agree to be accountable for all aspects of the work in ensuring that questions related to the accuracy or integrity of any part of the work are appropriately investigated and resolved

Zakaria Belkhadir – Conception of the work, Design of the work, Acquisition of data, Analysis of data, Drafting the work, Final approval of the version to be published, Agree to be accountable for all aspects of the work in ensuring that questions related to the accuracy or integrity of any part of the work are appropriately investigated and resolved

Lamyae Kallouch – Conception of the work, Analysis of data, Drafting the work, Final approval of the version to be published, Agree to be accountable for all aspects of the work in ensuring that questions related to the accuracy or integrity of any part of the work are appropriately investigated and resolved

Omor Youssef – Conception of the work, Analysis of data, Drafting the work, Final approval of the version to be published, Agree to be accountable for all aspects of the work in ensuring that questions related to the accuracy or integrity of any part of the work are appropriately investigated and resolved

Latib Rachida – Conception of the work, Analysis of data, Drafting the work, Final approval of the version to be published, Agree to be accountable for all aspects of the work in ensuring that questions related to the accuracy or integrity of any part of the work are appropriately investigated and resolved

**Guarantor of Submission**

The corresponding author is the guarantor of submission.

**Source of Support**

None.

**Consent Statement**

Written informed consent was obtained from the patient for publication of this article.

**Conflict of Interest**

Authors declare no conflict of interest.

**Data Availability**


All relevant data are within the paper and its Supporting Information files.

**Copyright**


© 2019 Yassine Smiti et al. This article is distributed under the terms of Creative Commons Attribution License which permits unrestricted use, distribution and reproduction in any medium provided the original author(s) and original publisher are properly credited. Please see the copyright policy on the journal website for more information.

**ABOUT THE AUTHORS**


**Article citation:** Smiti Y, Sounni O, Mouden A, Abdelilah G, El Ahmadi B, Belkhadir Z, Kallouch L, Youssef O, Rachida L. Respiratory failure concealing an esotracheal fistula in a 27-year-old patient followed for Hodgkin’s lymphoma, at an advanced stage, having received radiochemotherapy: A case report and review of the literature. Int J Case Rep Images 2019;10:101051Z01YS2019.




**Yassine Smiti** is resident at Intensive Care and Anaesthesia Service/National Oncology Institute, Mohamed 5 University, Rabat, Morocco. He has earned the undergraduate degree (a doctorate in medicine) from Faculty of Medicine of Rabat/Mohamed 5 University, Rabat, Morocco. He has published (7 scientific articles) research papers in national and international academic journals and authored (0) books. His research interests include (emergency, anesthesia, and pharmacology). He intends to continue (write scientific papers and participate in the development of science - for doctorates) in the future.  
Email: Yassin.smit@gmail.com




**Oussama Sounni** is resident at Intensive Care and Anaesthesia Service/National Oncology Institute/Mohamed 5 University, Rabat, Morocco. He has earned the undergraduate degree (a doctorate in medicine) from Faculty of Medicine of Rabat/Mohamed 5 University, Rabat, Morocco.  
Email: ssounioussama@yahoo.fr




**Achraf Mouden** is Anesthesiologist at Intensive Care and Anaesthesia Service/National Oncology Institute/Mohamed 5 University, Rabat, Morocco.  
Email: moudenachrafrea@gmail.com




**Lamyae Kallouch** is resident at Radiology Service/National Oncology Institute/Mohamed 5 University, Rabat, Morocco. She has earned the undergraduate degree (a doctorate in medicine) from Faculty of Medicine of Rabat, Mohamed 5 University, Rabat, Morocco. Her research interests include (emergency, imagery, and resuscitation). She intends to continue (write scientific papers and participate in the development of science - for doctorates) in the future.



**Abdelilah Ghannam** is Anesthesiologist at Intensive Care and Anaesthesia Service/National Oncology Institute, Mohamed 5 University, Rabat, Morocco.  
Email: A.ghannam@ino.ma



**Brahim El Ahmadi** is Anesthesiologist at Intensive Care and Anaesthesia Service/National Oncology Institute, Mohamed 5 University, Rabat, Morocco.  
Email: brahimelahmadi@gmail.com



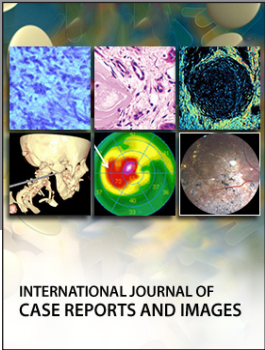
**Zakaria Belkhadir** is Anesthesiologist at Intensive Care and Anaesthesia Service/National Oncology Institute, Mohamed 5 University, Rabat, Morocco. Head of Service.  
Email: Zakaria.belkhadir@gmail.com

Access full text article on  
other devices



Access PDF of article on  
other devices





**Submit your manuscripts at**  
[www.edoriumjournals.com](http://www.edoriumjournals.com)

