

Failure of respiratory withdrawal in an infant revealing an agenesis of the corpus callosum: A case report

Othman Ayouche, Asaad El Bakkari, Latifa Chat, Nazik Allali, Yassine Smiti, Dahbi Youssef, Aziza Bentalha, Hasnaa Leghlimi, Alae El Koraichi, Salma Ech-Cherif El Kettani

ABSTRACT

Introduction: Corpus callosum is a cerebral commissure connecting the two hemispheres. It is the center of many pathological entities, among them, its agenesis, which is a common neurological anomaly usually, detected in antenatal sonography examinations. One in two patients has an associated intracerebral malformation. Imaging plays a major role in the antenatal detection as well as neonatal diagnosis of this entity. Sedation presents a difficult challenge especially in the case of severe neurological complications. **Case Report:** We expose the case of a respiratory failure with convulsive episodes resistant to therapy in a three months infant revealing a complete agenesis of the corpus callosum (ACC) with triventricular hydrocephalus due to aqueductal stenosis. **Conclusion:** The ACC is a congenital anomaly due to a direct insult to the corpus callosum in its developmental phase. It is usually asymptomatic, but has to be sought after systematically in a baby presenting neurological disorders, usually after

eliminating meningitis or metabolic disorders. These neurological disorders are predictive factors of difficulty of respiratory withdrawal, and have to be controlled before any intention of withdrawal.

Keywords: Complete, Corpus callosum agenesis, CT, Failure of respiratory withdrawal

How to cite this article

Ayouche O, El Bakkari A, Chat L, Allali N, Smiti Y, Youssef D, Bentalha A, Leghlimi H, El Koraichi A, El Kettani SEC. Failure of respiratory withdrawal in an infant revealing an agenesis of the corpus callosum: A case report. Int J Case Rep Images 2019;10:101050Z01OA2019.

Article ID: 101050Z01OA2019

doi: 10.5348/101050Z01OA2019CR

Othman Ayouche¹, Asaad El Bakkari¹, Latifa Chat¹, Nazik Allali¹, Yassine Smiti², Dahbi Youssef², Aziza Bentalha², Hasnaa Leghlimi², Alae El Koraichi², Salma Ech-Cherif El Kettani²

Affiliations: ¹Radiology Department, Children's Hospital, Ibn Sina Hospital, Mohamed V University, Rabat, Morocco; ²Anesthesiology and Resuscitation Department, Children's Hospital, Ibn Sina Hospital, Mohamed V University, Rabat, Morocco.

Corresponding Author: Othman Ayouche, Radiology Department, Children's Hospital, Ibn Sina Hospital, Mohamed V University, Rabat, Morocco; Email: Othman.ayouche@hotmail.com

Received: 16 June 2019

Accepted: 31 July 2019

Published: 16 September 2019

INTRODUCTION

Corpus callosum agenesis is a neurological malformation usually diagnosed in the antenatal period [1–3]. It is associated in 50% of the cases with other cerebral malformation, the most known among them is Aicardi syndrome [4]. Current imaging modalities have made it possible to detect this entity. With the evolution of this pathology and its association with other neurological conditions, sedation presents a difficult challenge [2, 3]. We expose the case of a newborn male admitted with respiratory failure as well as convulsive episodes resistant to therapy revealing a corpus callosum complete agenesis.

CASE REPORT

We describe the case of a three-month-old neonate without specific antecedents, from a well-attended pregnancy, vaginal delivery, the weight at birth was 2600 g, Apgar score 2 at 1 minute and 4 at 5 minutes. There was no history of familial disease nor genetic disorders. He was drowsy, hypotonic, hyporeflexic with no finger grasp. No investigation of dysmorphic syndrome was done. He had seizures, macrocephaly, and global development delay. Neurologic examination revealed a hypotonic infant with the inability to stand. He was using long-term multiple antiepileptic drugs.

In the intensive care unit (ICU), the patient was admitted in a respiratory distress context with installation of cyanosis and consciousness disorder.

Routine monitors were attached and intravenous (IV) access established with a 24 G cannula.

Sedation was accomplished and was put immediately in artificial mode ventilation for airway protection. Oxygen saturation was maintained between 97% and 100%. Body temperature, heart rate, noninvasive blood pressure, O₂ saturation, and end-tidal CO₂ were stable during his initial stay.

During his stay we observed three convulsion episodes making it difficult to stop respiratory assistance. Convulsions initially were partial and then became generalized. The patient was put under sodium valproate and phenobarbital, after management of airway and sedation with adjustment of doses of anticonvulsants as a function of dosing of barbitemia and depakinemia. The initial evolution was marked by the disappearance of crises.

A battery of tests was run in research of a metabolic etiology, among them hemoglobin (6 g/dL), serum sodium (140 meq/L), calcemia (2.2 mmol/L), gas analysis, cerebrospinal fluid analysis that have shown no anomalies. A cerebral computed tomography (CT) without contrast was in favor of a complete ACC (Figure 1), cavum septum pellucidum as well as a triventricular hydrocephalus due to aqueductal stenosis (Figure 2). Electroencephalogram (EEG) has shown brain damage signs.

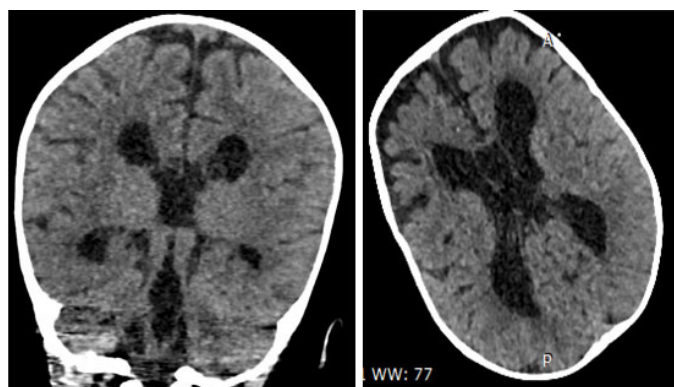


Figure 1: Axial view non-enhanced brain CT: Complete agenesis of corpus callosum, cavum septum pellucidum, triventricular hydrocephalus.

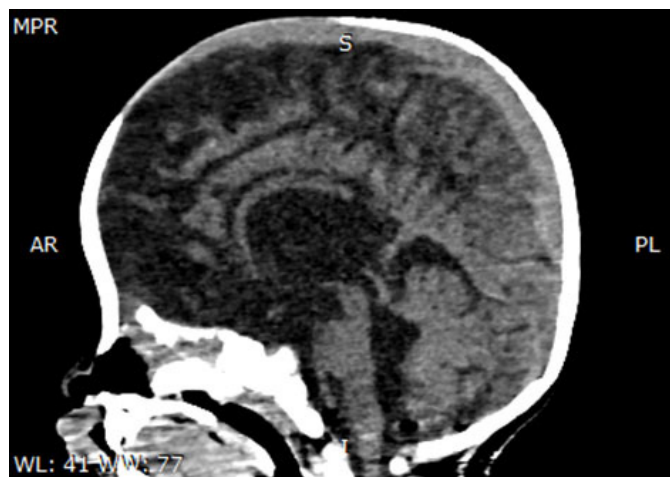

Figure 2: Axial view non-enhanced brain CT: Triventricular hydrocephalus due to aqueductal web.

There was a discussion with the surgical team for a ventricular derivation option to alleviate the hydrocephalus. However, due to the multiple convulsive episodes surgical intervention was prohibited.

The evolution was marked with the death of the patient following multiple failures of respiratory withdrawal complicated by a pneumonia associated with mechanical ventilation. The cause of death was attributed to a sepsis shock from a pneumonia associated with mechanical ventilation treated with an aminosides and cephalosporin association.

DISCUSSION

Corpus callosum is the main supratentorial cerebral commissure, and the largest white matter connective tissue. It allows interhemispheric integration of information. On one hand, it allows the independent functioning of the two hemispheres by inhibiting contralateral homotopic areas and on the other hand, it would allow the transmission of information between the two hemispheres [5]. It has a primary role in cognition. Dysgenesis leads to a decline in cognitive function [6]. It is comprised of four parts: The rostrum, the genu, the body and the splenium [7].

Embryonic development proceeds in an anterior–posterior gradient. A complete agenesis most likely occurs because of a direct insult that results in its complete absence. However, we usually attribute partial dysgenesis to an injury in a developing brain, which may explain why its rostrum is present with a discontinuity of corpus development [8].

Its absence may be partial or complete, congenital or acquired, isolated or associated with other neurological malformation of the posterior fossa, gyration disorder, and heterotopy of the gray substance, which worsens the neurological prognosis. Complete agenesis involves the corpus callosum, and fornix and often the anterior

white commissure. Partial agenesis usually concerns the splenium [1].

The mechanism leading to the isolated ACC is yet to be discovered. Its genetic distribution can be sporadic, autosomal dominant, or recessive X-linked chromosomal defect. There is no incidence reference reported between the sexes [9].

It may be symptomatic or asymptomatic. Our patient has an isolated and symptomatic form. Epilepsy is found in 50% of patients and generalized seizures are frequently seen. Most abnormalities are discovered at a late age among them behavior problems, emotional problems, and lack of attention [10]. The neonates with ACC are often recognized by facial or somatic anomalies. The common clinical presentation in children is development delay, seizures, and difficulty learning in school. Agenesis of the corpus callosum can be a part of many chromosomal and mental retardation syndromes [11]. Some syndromes include ACC are Aicardi syndrome, Andermann syndrome, Shapiro syndrome, and Mowat–Wilson syndrome [12].

Ultrasound is very efficient for this diagnosis and the semiology is very rich, available only for newborn [1]:

- Absence or partial ACC.
- Absence of cingulate gyrus with a radiated aspect of the parietal-frontal fissures.
- The interhemispheric fissure descends to the third ventricle.
- Ventriculomegaly marked at the expense of occipital horns “colpocephaly” with fine frontal horns.

On Doppler ultrasound: sinuous vertical path of the pericallosal artery.

However, its limited accessibility makes magnetic resonance imaging (MRI) the modality of choice for the exploration of corpus callosum agenesis as well as for antenatal diagnosis. Its main features includes: sulci and gyri along the medial surface of the cerebral hemispheres radiate directly toward the top of the third ventricle. Deformation of the lateral ventricle with third ventricle enlargement [2].

The figures underestimate the true incidence due to a proportion of asymptomatic patients who are not diagnosed prenatally. Epilepsy is present in 50% of cases in the form of partial and generalized seizures, being treated easily by drugs [7]. Patients with acute brain injury, especially in cases of persistent swallowing or consciousness disturbances, are at high risk of extubation failure with re-intubation rates of up to 38% [13].

Recommendations of French experts recommend administration of clonazepam or midazolam renewable in case of failure within 5–10 minutes. After the control of the status epilepticus (EME), a relay with a long-acting benzodiazepine at an early stage is preconized [14]. Ultrasound recommendations place valproate, phenytoin as second-line therapy line without specifying hierarchy [15]. The electroencephalogram

should be repeated to check the effectiveness of the treatment. Recourse to continuous recording of EEG is of interest, especially in cases of refractory non-convulsive status epilepticus, or in cases of difficulty in clinically detecting seizures [16, 17].

Sedation for the cerebrally impaired patient is particular since it interferes with the primary effector that is the brain and ventilatory control [18].

The clinical resultant of these congenital anomalies are numerous but its main denominator is cerebral ischemia. Therefore, the main aim of this sedation is to prevent cerebral hypoxemia and vasospasm, as well as to allow a neurological evaluation as soon as possible after the initial cerebral aggression especially in the case of convulsions, which would require sedation and deep analgesia.

Sedation windows allow us to set up a diagnostic and therapeutic strategy to implement stopping or continuation of sedation, continuation or not of hemodynamic support and mechanical ventilation, indication of further explorations.

So what would be the place of imaging in the window of sedation? In general, a discrepancy between the absence of visible lesions in imaging and the initial neurological state after brain suffering should lead to test the neurological function of the patient [19].

Then when can we stop sedation? Weaning is the moment when the patient's condition allows the decrease and then the cessation of the continuous administration of drugs to allow him to regain a respiratory autonomy, possibly concluded by tracheal extubation.

The unexplained prolongation of vigilance disorders when stopping sedation is by far the most frequent situation. The causes of this delay of awakening may be an accumulation of pharmacological agents, or correspond to neurological lesions gone unnoticed.

In case of waking delay, performing brain imaging should eliminate an undetected brain injury [20]. In the presence of an opioid withdrawal syndrome, the reintroduction of the morphine in question is sometimes the only effective solution. The use of methadone has been proposed in pediatric intensive care [21]. Tracheostomy is an accepted modality in adults for accelerating ventilator weaning in patients with severe neurological or respiratory sequelae, but also in sedation withdrawal failure [22]. However, its interest in infants has yet to be proved.

In our case, convulsive episodes prompted an exploration by imaging which resolved our initial problem of discovering their causality. However, the repetitive failure of respiratory withdrawal caused extensive cerebral damages as well as cardiac ischemia, leading to the death of the patient.

CONCLUSION

The ACC is a congenital anomaly due to a direct insult to the corpus callosum in its developmental phase.

It is usually asymptomatic, but have to be sought after systematically in a baby presenting neurological disorders, usually after eliminating meningitis or metabolic disorders. These neurological disorders are predictive factors of difficulty of respiratory withdrawal, and have to be controlled before any intention of withdrawal.

REFERENCES

1. Georgy BA, Hesselink JR, Jernigan TL. MR imaging of the corpus callosum. *AJR Am J Roentgenol* 1993;160(5):949–55.
2. Verstichel P, Degos JD. Syndromes de déconnexion interhémisphérique. *EMC - Neurologie* 2004;1(1):1–16.
3. Curnes JT, Laster DW, Koubek TD, Moody DM, Ball MR, Witcofski RL. MRI of corpus callosal syndromes. *AJNR Am J Neuroradiol* 1986;7(4):617–22.
4. Cook ND. Callosal inhibition: The key to the brain code. *Behav Sci* 1984;29(2):98–110.
5. Gelot A, Lewin F, Moraine C, Pompidou A. Agenesis of the corpus callosum. Neuropathologic study and physiopathologic hypotheses. [Article in French]. *Neurochirurgie* 1998;44(1 Suppl):74–84.
6. Carpenter MB. *Core Text of Neuroanatomy*. 3ed. Baltimore: Lippicott Williams and Wilkins; 1985.
7. Barkovich AJ, Norman D. Anomalies of the corpus callosum: Correlation with further anomalies of the brain. *AJR Am J Roentgenol* 1988;151(1):171–9.
8. Couture A, Veyrac C. *Transfontanellar Doppler imaging in neonates*. Berlin, Heidelberg: Springer-Verlag; 2001.
9. Thauvin-Robinet C, Cossée M, Cormier-Daire V, et al. Clinical, molecular, and genotype-phenotype correlation studies from 25 cases of oral-facial-digital syndrome type 1: A French and Belgian collaborative study. *J Med Genet* 2006;43(1):54–61.
10. Moutard ML, Kieffer V, Feingold J, et al. Agenesis of corpus callosum: Prenatal diagnosis and prognosis. *Childs Nerv Syst* 2003;19(7–8):471–6.
11. Taylor M, David AS. Agenesis of the corpus callosum: A United Kingdom series of 56 cases. *J Neurol Neurosurg Psychiatry* 1998;64(1):131–4.
12. Dupré N, Howard HC, Mathieu J, et al. Hereditary motor and sensory neuropathy with agenesis of the corpus callosum. *Ann Neurol* 2003;54(1):9–18.
13. Namen AM, Ely EW, Tatter SB, et al. Predictors of successful extubation in neurosurgical patients. *Am J Respir Crit Care Med* 2001;163(3 Pt 1):658–64.
14. Szurhaj W, Engrand N. Status epilepticus: Recent advances. [Article in French]. *Presse Med* 2018;47(3):266–77.
15. Glauser T, Shinnar S, Gloss D, et al. Evidence-based guideline: Treatment of convulsive status epilepticus in children and adults: Report of the guideline committee of the American epilepsy society. *Epilepsy Curr* 2016;16(1):48–61.
16. Kumar N. Sevoflurane in child with corpus callosum agenesis syndrome, a series of four cases. *Pediatr Anesth Crit Care J* 2014;2:48–51.
17. André-Obadia N, Parain D, Szurhaj W. Continuous EEG monitoring in adults in the intensive care unit (ICU). *Neurophysiol Clin* 2015;45(1):39–46.

18. Flögel CM, Ward DS, Wada DR, Ritter JW. The effects of large-dose flumazenil on midazolam-induced ventilatory depression. *Anesth Analg* 1993;77(6):1207–14.
19. Stocchetti N, Pagan F, Calappi E, et al. Inaccurate early assessment of neurological severity in head injury. *J Neurotrauma* 2004;21(9):1131–40.
20. McKenzie CA, McKinnon W, Naughton DP, et al. Differentiating midazolam over-sedation from neurological damage in the intensive care unit. *Crit Care* 2005;9(1):R32–6.
21. Koppert W, Ihmsen H, Körber N, et al. Different profiles of buprenorphine-induced analgesia and antihyperalgesia in a human pain model. *Pain* 2005;118(1–2):15–22.
22. Nieszowska A, Combes A, Luyt CE, et al. Impact of tracheotomy on sedative administration, sedation level, and comfort of mechanically ventilated intensive care unit patients. *Crit Care Med* 2005;33(11):2527–33.

Author Contributions

Othman Ayouche – Conception of the work, Design of the work, Acquisition of data, Analysis of data, Interpretation of data, Drafting the work, Revising the work critically for important intellectual content, Final approval of the version to be published, Agree to be accountable for all aspects of the work in ensuring that questions related to the accuracy or integrity of any part of the work are appropriately investigated and resolved

Asaad El Bakkari – Conception of the work, Design of the work, Acquisition of data, Analysis of data, Interpretation of data, Drafting the work, Revising the work critically for important intellectual content, Final approval of the version to be published, Agree to be accountable for all aspects of the work in ensuring that questions related to the accuracy or integrity of any part of the work are appropriately investigated and resolved

Latifa Chat – Conception of the work, Design of the work, Acquisition of data, Analysis of data, Interpretation of data, Drafting the work, Revising the work critically for important intellectual content, Final approval of the version to be published, Agree to be accountable for all aspects of the work in ensuring that questions related to the accuracy or integrity of any part of the work are appropriately investigated and resolved

Nazik Allali – Conception of the work, Design of the work, Acquisition of data, Analysis of data, Interpretation of data, Drafting the work, Revising the work critically for important intellectual content, Final approval of the version to be published, Agree to be accountable for all aspects of the work in ensuring that questions related to the accuracy or integrity of any part of the work are appropriately investigated and resolved

Yassine Smiiti – Conception of the work, Design of the work, Acquisition of data, Interpretation of data, Drafting the work, Revising the work critically for important

intellectual content, Final approval of the version to be published, Agree to be accountable for all aspects of the work in ensuring that questions related to the accuracy or integrity of any part of the work are appropriately investigated and resolved

Dahbi Youssef – Conception of the work, Design of the work, Acquisition of data, Analysis of data, Interpretation of data, Drafting the work, Revising the work critically for important intellectual content, Final approval of the version to be published, Agree to be accountable for all aspects of the work in ensuring that questions related to the accuracy or integrity of any part of the work are appropriately investigated and resolved

Aziza Bentalha – Conception of the work, Design of the work, Acquisition of data, Analysis of data, Interpretation of data, Drafting the work, Revising the work critically for important intellectual content, Final approval of the version to be published, Agree to be accountable for all aspects of the work in ensuring that questions related to the accuracy or integrity of any part of the work are appropriately investigated and resolved

Hasnaa Leghlimi – Conception of the work, Design of the work, Acquisition of data, Analysis of data, Interpretation of data, Drafting the work, Revising the work critically for important intellectual content, Final approval of the version to be published, Agree to be accountable for all aspects of the work in ensuring that questions related to the accuracy or integrity of any part of the work are appropriately investigated and resolved

Alae El Koraichi – Conception of the work, Design of the work, Acquisition of data, Analysis of data, Interpretation of data, Drafting the work, Revising the work critically for important intellectual content, Final approval of the version to be published, Agree to be accountable for all aspects of the work in ensuring that questions related

to the accuracy or integrity of any part of the work are appropriately investigated and resolved

Salma Ech-Cherif El Kettani – Conception of the work, Design of the work, Acquisition of data, Analysis of data, Interpretation of data, Drafting the work, Revising the work critically for important intellectual content, Final approval of the version to be published, Agree to be accountable for all aspects of the work in ensuring that questions related to the accuracy or integrity of any part of the work are appropriately investigated and resolved

Guarantor of Submission

The corresponding author is the guarantor of submission.

Source of Support

None.

Consent Statement

Written informed consent was obtained from the patient for publication of this article.

Conflict of Interest

Authors declare no conflict of interest.

Data Availability

All relevant data are within the paper and its Supporting Information files.

Copyright

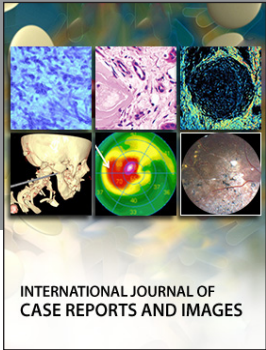
© 2019 Othman Ayouche et al. This article is distributed under the terms of Creative Commons Attribution License which permits unrestricted use, distribution and reproduction in any medium provided the original author(s) and original publisher are properly credited. Please see the copyright policy on the journal website for more information.

Access full text article on other devices



Access PDF of article on other devices





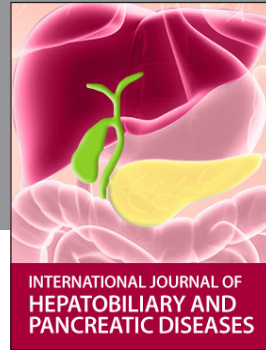INTERNATIONAL JOURNAL OF
CASE REPORTS AND IMAGES



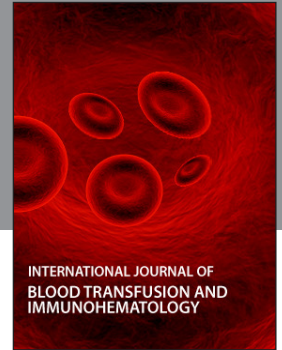VIDEO JOURNAL OF
CLINICAL RESEARCH



VIDEO JOURNAL OF
BIOMEDICAL SCIENCE



INTERNATIONAL JOURNAL OF
HEPATOBIILIARY AND
PANCREATIC DISEASES



INTERNATIONAL JOURNAL OF
BLOOD TRANSFUSION AND
IMMUNOHEMATOLOGY

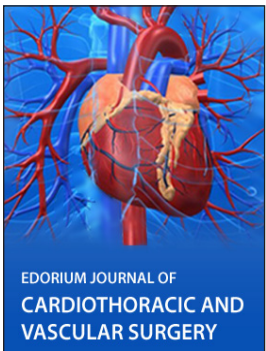


EDORIUM JOURNAL OF
OPHTHALMOLOGY

Submit your manuscripts at
www.edoriumjournals.com



EDORIUM JOURNAL OF
MEDICINE



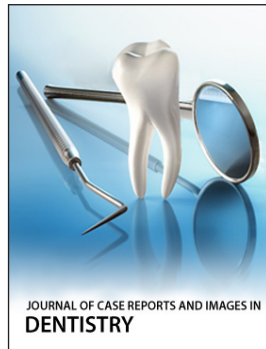
EDORIUM JOURNAL OF
CARDIOTHORACIC AND
VASCULAR SURGERY



EDORIUM JOURNAL OF
PSYCHOLOGY



EDORIUM JOURNAL OF
CELL BIOLOGY



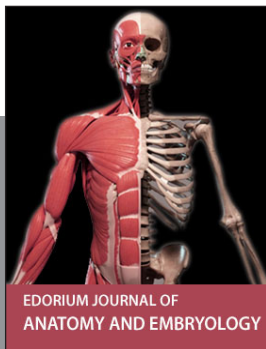
JOURNAL OF CASE REPORTS AND IMAGES IN
DENTISTRY




EDORIUM JOURNAL OF
CANCER



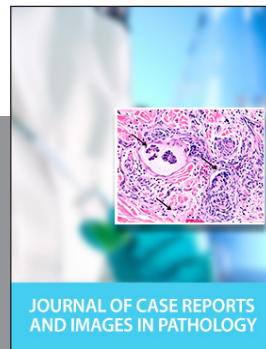JOURNAL OF CASE REPORTS AND
IMAGES IN INFECTIOUS DISEASES



EDORIUM JOURNAL OF
ANATOMY AND EMBRYOLOGY



EDORIUM JOURNAL OF
SURGERY



JOURNAL OF CASE REPORTS
AND IMAGES IN PATHOLOGY



EDORIUM JOURNAL OF
ANESTHESIA