

## CASE REPORT

## PEER REVIEWED | OPEN ACCESS

# A case of unilateral fenestration of the external jugular vein in a male cadaver with a review of existing literature

Matthew James Eskell, Robert Daniel Bickerton, Isabel Ann Guy, Benjamin Joseph Jefferies

## ABSTRACT

**Introduction:** Neck veins are increasingly used in autologous tissue transfers, diagnostic procedures, and intravenous therapies. Thus, knowledge of variation in their anatomy is of huge clinical importance in modern medicine. There have been several case reports of variation in the external jugular vein (EJV) anatomy, but fenestration remains one of the rarest anomalies reported. **Case Report:** During dissection of an embalmed 80-year-old male cadaver, unilateral (left-sided) fenestration of the EJV was noted. Shortly after the union of the retromandibular and posterior auricular veins, the EJV bifurcated, forming medial and lateral divisions. These descended superficially to sternocleidomastoid muscle before reuniting inferior to its posterior border in the posterior triangle of the neck and draining into the subclavian vein. No structures passed through the fenestration. A review of existing literature found five reports of unilateral EJV fenestration. Of note, ours is the only case where the anomaly has occurred in a male. **Conclusion:** Fenestration of the EJV is a rare anatomical anomaly. This case report contributes to the limited body of evidence regarding the true incidence of this variant. Further research will be beneficial in building a more comprehensive

evidence base regarding anatomical variants of the EJV.

**Keywords:** Anatomical variation, External jugular vein, Fenestration, Venous

### How to cite this article

Eskell MJ, Bickerton RD, Guy IA, Jefferies BJ. A case of unilateral fenestration of the external jugular vein in a male cadaver with a review of existing literature. Int J Case Rep Images 2019;10:101048Z01ME2019.

Article ID: 101048Z01ME2019

\*\*\*\*\*

doi: 10.5348/101048Z01ME2019CR

## INTRODUCTION

Knowledge of variation in the venous trees of the head and neck is important for both a clinician and anatomist, with neck veins being increasingly used as recipients of free autologous tissue transfers as well as in diagnostic procedures and intravenous therapies [1, 2]. There have been several case reports of variation in external jugular vein (EJV) anatomy [3–7] but no study has yet reported the anomaly in a male. Here, we report an incidental finding of unilateral fenestration of the EJV.

## CASE REPORT

During dissection of an embalmed 80-year-old male cadaver, cause of death reported as metastatic prostate cancer, as part of the Clinical Anatomy program at the University of Birmingham Medical School, unilateral (left-sided) fenestration of the EJV was noted (Figures 1 and 2). Dissection of the contralateral side revealed

Matthew James Eskell<sup>1</sup>, Robert Daniel Bickerton<sup>1</sup>, Isabel Ann Guy<sup>1</sup>, Benjamin Joseph Jefferies<sup>1</sup>

**Affiliation:** <sup>1</sup>Medical Student, University of Birmingham Medical School, University of Birmingham, Birmingham, West Midlands, United Kingdom.

**Corresponding Author:** Matthew James Eskell, City of Bristol, BS9 1BE, United Kingdom; Email: matthew.eskell@hotmail.co.uk

Received: 22 July 2019

Accepted: 16 August 2019

Published: 09 September 2019

normal anatomy: the retromandibular vein joined the posterior auricular vein adjacent to the parotid gland to form the EJV, which descended and drained into the subclavian vein without fenestration.

On the left side, the posterior division of the retromandibular vein and the posterior auricular vein emerged from the inferior border of the parotid gland. These anastomosed to form the EJV. Shortly after this union, the EJV bifurcated, forming medial and lateral divisions. Both divisions descended superficially to sternocleidomastoid muscle before reuniting in the posterior triangle approximately 60 mm below the point of division and draining into the subclavian vein. No structures passed through the fenestration.

Importantly, the cadaver had a large anterior mediastinal mass, seemingly pathological in nature, surrounding and encasing the great vessels. We suspect the cadaver suffered from superior vena cava syndrome as a result; the veins in the neck were engorged, particularly on the left, as can be seen in Figure 3. The EJV on the right had a smaller diameter than on the left. The veins on the right were also more muscular in appearance, likely a result of the high pressure caused by obstruction downstream.

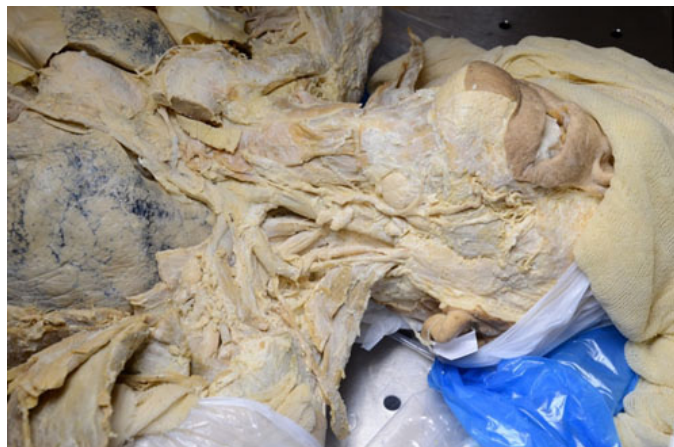

Figure 1: Color photograph showing superficial neck dissection. Consent for images to be taken was provided by the donor as part of the donor registration program at the University of Birmingham license number 12236.

## DISCUSSION

The prevalence of fenestration in the head and neck region is low. The Department of Oral and Maxillofacial Surgery at the Yokohama City University Graduate School of Medicine conducted 250 neck dissections for patients with oral cancer between January 2004 and September 2016 [7]. Fenestration of the EJV was present in only one of these cases, giving an incidence of 0.4%.

Moreover, existing literature frequently confuses “fenestration” and “duplication” when describing anatomical anomalies, thus literature reviews searching for further cases of this anatomical phenomenon can be difficult to conduct. In a review of case reports describing

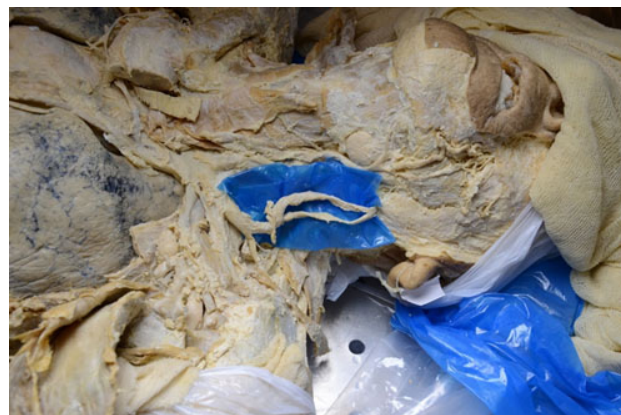

Figure 2: Color photograph showing superficial neck dissection, with external jugular vein fenestration highlighted. Consent for images to be taken was provided by the donor as part of the donor registration program at the University of Birmingham license number 12236.

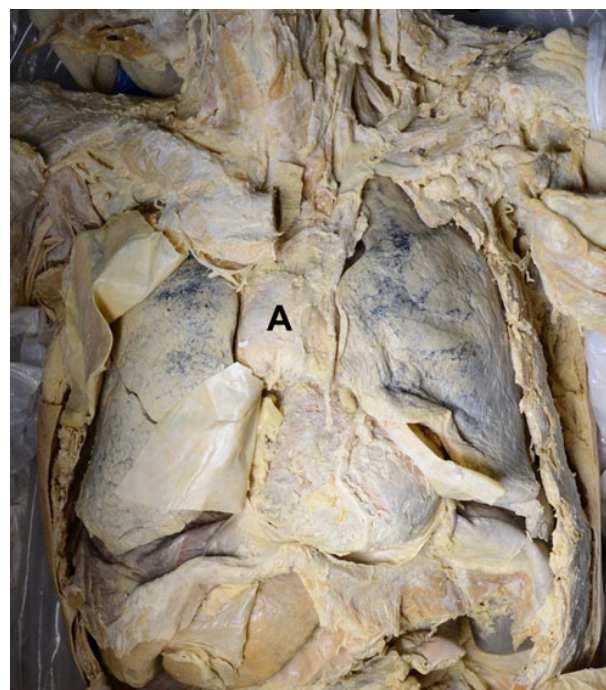


Figure 3: Color photograph showing anterior mediastinal mass (A) and its anatomical relations. Consent for images to be taken was provided by the donor as part of the donor registration program at the University of Birmingham license number 12236.

internal jugular vein anomalies, Downie et al. suggest “duplication” should be used for cases when vessels branch but do not reunite to form a single-lumened structure, and “fenestration” limited to cases in which branched vessels reunite [8]. As such, it is now commonly regarded within medical and anatomical literature that fenestration describes cases in which a branched vessel reunites into a single normal vessel with a single lumen [6].

A review of existing literature found five English language articles reporting EJV fenestration (Table 1). Of



Table 1: Summary of existing case reports of EJV fenestration

Author, Year	Age (years)	Sex*	Side**	Method identification	of Notes
Comert and Comert, 2009	47	F	R	Surgery	
Cvetko, 2013	75	F	L	Cadaveric dissection	Facial nerve passing through fenestration
Snoj and Cvetko, 2013	77	F	L	Cadaveric dissection	
Cvetko, 2015	75	F	R	Cadaveric dissection	EJV absent on left
Sugiyama et al., 2017	77	F	L	Surgery	Contralateral side not investigated
Present case	80	M	L	Cadaveric dissection	

Abbreviations: \*"F" signifies Female and "M" signifies Male.  
\*\*"R" signifies Right and "L" signifies Left.

note, ours is the only case where the variant has occurred in a male. Of these five reported cases, three occurred unilaterally on the left and two unilaterally on the right. As in this case, three reports [4–6] identified the anomaly during cadaveric dissection however, two reports [3, 7] identified this anomaly during surgical procedures. All previous studies report unilateral fenestration of the EJV; however, Sugiyama et al. do not specify whether the contralateral side was investigated [7]. No existing literature describes any of the cases having pathological symptoms and thus these are usually incidental findings.

The significance of this finding in a male is relevant from both anatomical and clinical perspectives. The EJV is increasingly being used as the recipient vein for head and neck tissue transfers [2]. Furthermore, the superficial veins of the neck are gathering popularity for purposes of cannulation to conduct diagnostic procedures and intravenous therapies [1]. Clinicians lacking understanding of this variant anatomy render patients vulnerable to accidental damage during surgery and diagnostic procedures. Thus, thorough knowledge of this variant anatomy is imperative before performing any clinical or radiological examination to avoid iatrogenic injury [9]. In incidences of the EJV being used to monitor central venous pressure, estimation of pressure at the fenestrated part of an EJV has been known to lead to pressure underestimations [6].

## CONCLUSION

Fenestration of the external jugular vein is an extremely rare anatomical anomaly, with a recent review of literature finding only five English language articles reporting cases. As such, this case report contributes to the existing yet limited body of evidence regarding the true incidence of this anatomical variant, which has significant ramifications for clinical practice. This case report has highlighted the paucity of literature on the topic, recognizing the need to build a more comprehensive evidence base for healthcare professionals to appreciate

possible anatomical variants, and encourage the development of clinical practice accordingly.

## REFERENCES

1. Vinayak AG, Levitt J, Gehlbach B, Pohlman AS, Hall JB, Kress JP. Usefulness of the external jugular vein examination in detecting abnormal central venous pressure in critically ill patients. *Arch Intern Med* 2006;166(19):2132–7.
2. Cheng HT, Lin FY, Chang SC. External or internal jugular vein? Recipient vein selection in head and neck free tissue transfer: An evidence-based systematic analysis. *Plast Reconstr Surg* 2012;129(4):730e–1.
3. Comert E, Comert A. External jugular vein duplication. *J Craniofac Surg* 2009;20(6):2173–4.
4. Cvetko E. A case of unilateral fenestration of the external jugular vein, through which the cervical branch of the facial nerve passes. *Anat Sci Int* 2013;88(3):151–2.
5. Snoj Z, Cvetko E. A case of unilateral fenestration and duplication of the external jugular vein. *Int J Morphol* 2013;31(1):107–9.
6. Cvetko E. A case of left-sided absence and right-sided fenestration of the external jugular vein and a review of the literature. *Surg Radiol Anat*
7. Sugiyama S, Iwai T, Tohnai I. Empty fenestration of the external jugular vein: A rare variant. *Journal of the Anatomical Society of India* 2017;66(2):S1–3.
8. Downie SA, Schalop L, Mazurek JN, Savitch G, Lelonek GJ, Olson TR. Bilateral duplicated internal jugular veins: Case study and literature review. *Clin Anat* 2007;20(3):260–6.
9. Chauhan NK, Rani A, Chopra J, Rani A, Srivastava AK, Kumar V. Anomalous formation of external jugular vein and its clinical implication. *Natl J Maxillofac Surg* 2011;2(1):51–3.

\*\*\*\*\*

## Acknowledgments

The authors would like to acknowledge the work of Miss Vicky Cottrell at the University of Birmingham for her

assistance during the dissection process as part of the BSc Clinical Anatomy program at the university. In addition, we would like to thank Mr Martin Jones of the University of Birmingham for his assistance in photographing the anatomical variation. We are grateful for the invaluable contributions of the Anatomy Department at the University of Birmingham led by the late Professor Joanne Wilton.

### Author Contributions

Matthew James Eskell – Conception of the work, Design of the work, Acquisition of data, Drafting the work, Revising the work critically for important intellectual content, Final approval of the version to be published, Agree to be accountable for all aspects of the work in ensuring that questions related to the accuracy or integrity of any part of the work are appropriately investigated and resolved

Robert Daniel Bickerton – Conception of the work, Design of the work, Acquisition of data, Drafting the work, Revising the work critically for important intellectual content, Final approval of the version to be published, Agree to be accountable for all aspects of the work in ensuring that questions related to the accuracy or integrity of any part of the work are appropriately investigated and resolved

Isabel Ann Guy – Conception of the work, Design of the work, Acquisition of data, Drafting the work, Revising the work critically for important intellectual content, Final approval of the version to be published, Agree to be accountable for all aspects of the work in ensuring that questions related to the accuracy or integrity of any part of the work are appropriately investigated and resolved

Benjamin Joseph Jefferies – Conception of the work, Design of the work, Acquisition of data, Drafting

the work, Revising the work critically for important intellectual content, Final approval of the version to be published, Agree to be accountable for all aspects of the work in ensuring that questions related to the accuracy or integrity of any part of the work are appropriately investigated and resolved

### Guarantor of Submission

The corresponding author is the guarantor of submission.

### Source of Support

None.

### Consent Statement

Written informed consent was obtained from the patient for publication of this article.

### Conflict of Interest

Authors declare no conflict of interest.

### Data Availability

All relevant data are within the paper and its Supporting Information files.

### Copyright

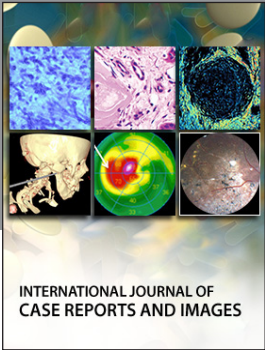
© 2019 Matthew James Eskell et al. This article is distributed under the terms of Creative Commons Attribution License which permits unrestricted use, distribution and reproduction in any medium provided the original author(s) and original publisher are properly credited. Please see the copyright policy on the journal website for more information.

Access full text article on  
other devices



Access PDF of article on  
other devices





**Submit your manuscripts at**  
[www.edoriumjournals.com](http://www.edoriumjournals.com)

