

Septic cerebral thrombosis in neonates: A case report and review of the literature

Yassine Smiti, Lemssiah Adib, Aziza Bentalha, Alae El Koraichi, Leghlimi Hasnaa, Salma Ech-Cherif El Kettani, Othman Ayouche, Asaad El Bakkari, Nazik Allali, Latifa Chat

ABSTRACT

Introduction: Septic dural-sinus thrombosis is rare; it is one of the most misdiagnosed conditions of our time. It is often associated with a high level of mortality. Especially in neonates who have an underdeveloped immune system and haphazard clinical manifestation. Septic sinus thrombosis frequently involves cavernous sinuses. The superior sagittal sinuses' involvement is exceptional as it is often associated with a fatal outcome. Studies demonstrate that heparin therapy in sagittal sinus septic thrombosis is unnecessary and that the focus of treatment shall be intravenous antibiotics and early surgical drainage of purulent collections who can be a source of widespread infections. **Case Report:** We report the case of a three months old boy, without pathological history, admitted in the intensive care unit (ICU) for febrile convulsion resistant to first line therapy. Cerebrospinal fluid analysis results were in favor of pneumococcus pathogens. Cerebral computed tomography (CT) has shown a superior longitudinal sinus thrombophlebitis complicating an encephalitis, with multiple venous infarcts. After which antibiotherapy was changed and anticoagulation

added. Six days later, the sedation was stopped to evaluate the neurological state. The patient has shown a persistence of the coma state. After a multidisciplinary discussion, a transcranial Doppler was realized only to confirm the brain death state. The evolution was marked by the death of the patient after three days. **Conclusion:** In general, cerebral venous thrombosis (CVT) is a disease with complex clinical manifestations, atypical in many patients. If an alteration of consciousness is the main symptom in a CVT patient, the prognosis can be bleak. Most patients with CVT have a good prognosis after early anticoagulant and antibiotherapy. Since cerebral hernia is the most common cause of death in CVT, intensive care should be given special attention to the detection and treatment of focal lesions occupying space.

Keywords: Cerebral thrombosis, CT, Encephalitis, Resuscitation, Sepsis

How to cite this article

Smiti Y, Adib L, Bentalha A, El Koraichi A, Hasnaa L, El Kettani SEC, Ayouche O, El Bakkari A, Allali N, Chat L. Septic cerebral thrombosis in neonates: A case report and review of the literature. Int J Case Rep Images 2019;10:101045Z01YS2019.

Article ID: 101045Z01YS2019

doi: 10.5348/101045Z01YS2019CR

Yassine Smiti¹, Lemssiah Adib¹, Aziza Bentalha¹, Alae El Koraichi¹, Leghlimi Hasnaa¹, Salma Ech-Cherif El Kettani¹, Othman Ayouche², Asaad El Bakkari², Nazik Allali², Latifa Chat²

Affiliations: ¹Children's Hospital, Anesthesiology and Resuscitation Department, Mohamed V University, Rabat, Morocco; ²Children's Hospital, Radiology Department, Mohamed V University, Rabat, Morocco.

Corresponding Author: Yassine Smiti, Children's Hospital, Mohamed V University, Rabat, Morocco; Email: yassin.smit@gmail.com

Received: 02 June 2019

Accepted: 04 July 2019

Published: 14 August 2019

INTRODUCTION

Septic dural-sinus thrombosis is rare; it is one of the most misdiagnosed conditions of our time [1]. It is often

associated with a high level of mortality. Especially in neonates who have an underdeveloped immune system and haphazard clinical manifestation [2]. Septic sinus thrombosis frequently involves cavernous sinuses. The superior sagittal sinuses' involvement is exceptional as it is often associated with a fatal outcomes [1, 3]. Studies demonstrate that heparin therapy in sagittal sinus septic thrombosis is unnecessary and that the focus of treatment shall be intravenous antibiotics and early surgical drainage of purulent collections who can be a source of widespread infections [1, 3, 4].

CASE REPORT

We report the case of a three months old boy, without pathological history. The beginning of the symptomatology goes back to five days of its admission, first the patient presented a lethargically state with hypotonia and a refusal of feeding, accompanied by hyperthermia, which quickly evolved toward a convulsive crisis.

The patient was admitted to the ICU, with a fever at 38.9°, blood pressure at 89/46 mmHg, heart rate at 190 beats/min, respiratory rate at 49 cycle/min, pulsed saturation at 97%, and a glycemia at 0.9 g/dL.

We take a peripheral venous route to begin the rehydration, and we place a high concentration mask for oxygenation. We realized a transfontanellar sonogram which detected no morphological anomalies.

Cerebrospinal fluid (CSF) analysis results: purulent fluid with a predominance of neutrophils 400 element/mm³, proteins: 6g/L, glucose: 0.3 g/dL, bacteriological analysis was in favor of a gram-positive cocci with positive pneumococcus soluble antigen.

Procalcitonin (PCT) was at 24 ng/mL and C-reactive protein (CRP) at 320 mg/L. We decided to administer ceftriaxone at meningeal dose with hydrocortisone hemisuccinate to prevent for Jared–Hexeimer reaction.

Subsequently, the patient presented a state of convulsive crisis resistant to first- and second-line therapy, which required an upper airways management.

We decided upon this symptomatology to realize a cerebral CT that objectified a superior longitudinal sinus thrombophlebitis complicating an encephalitis, with multiple venous infarcts (Figure 1).

Then we add vancomycin to ceftriaxone upon the bad evolution of the patient under ceftriaxone alone. Six days later, we decided to stop the sedation to evaluate the neurological state: which has shown a persistence of the coma state.

After a multidisciplinary discussion a transcranial Doppler sonogram was performed which has shown abolition of trunk reflexes, and a reverse flow in favor of a brain death state. A control with a cerebral CT was performed to research the damages and the extension, which showed an extensive ischemic cerebral infarct. The evolution was marked by the death of the patient after three days.

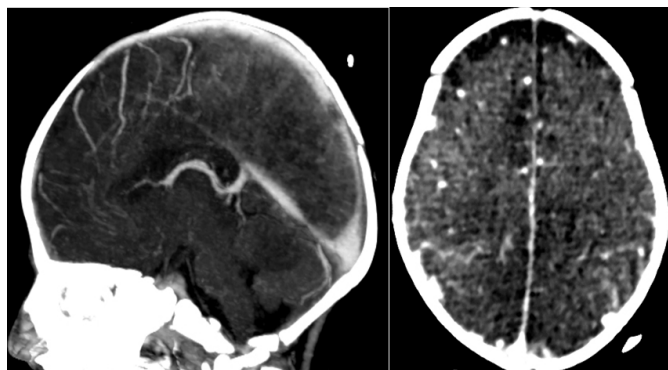


Figure 1: Cerebral CT scan showing diffuse ischemia with upper longitudinal sinus thrombosis.

DISCUSSION

Venous thromboembolism is increasingly recognized as a major cause of pediatric morbidity and mortality. The incidence is estimated at 0.07–0.49 per 10,000 children [5]. A predilection for thrombosis in neonatal period and adolescence has been identified [6]. A multitude of risk factors have been identified, including [5–7]:

- Congenital prothrombotic factors: antithrombin deficiency, in protein C or protein S.
- Immobility.
- Long ICU stay.
- Mechanical ventilation.
- Obesity: source of chronic inflammatory state, platelet activation, and endothelial dysfunction.
- Oral contraception: in adolescent population, increasing procoagulant proteins, decreasing the effect of protein S and antithrombin, which induces a state of resistance to C protein.
- Central venous catheters.
- Acquired factors: neoplasia, infections, surgical procedures (especially cardiac surgery and surgery orthopedic), trauma, nephrotic syndrome, lupus erythematosus, chemotherapy (L-asparaginase ++), which are problematic conditions to analyze, given their broad associations with other risk factors.

Considering its anatomical situation, the superior sagittal sinus is attached to the falx cerebri superiorly, to crista galli anteriorly, and tentorium posteriorly. It courses in the midline on the inner table of the cranium and grows larger as it continues posteriorly, and ends by becoming the right transverse sinus. Torcular herophili is a dilatation and considered the confluences of the sinuses [8, 9]. It receives venous blood from a variety of veins, including superficial cerebral veins draining blood from the cortical surface, meningeal veins draining blood from the meninges, diploic veins draining blood from channels located between the inner and outer tables of the calvaria, and multiple emissary veins, which link the venous sinuses and diploic veins with veins on the surface of the skull [8]. These channels do not have valves

and permit free communication between these venous systems and the venous sinuses [8]. This particularity has been considered one of the most repeated factor risk in the literature for the possible spread of infections from foci outside the cranium to the venous sinuses [1, 3, 8, 10]. Recently studies demonstrated a lymphatic drainage network for the meningeal system [11]. This lymphatic system is associated with the venous system as the lymphatic vessels are associated with sinuses [8, 12].

Physiopathology

The dural sinuses and cerebral veins lack valves. This particularity makes the blood flow pressure dependent, and blood can flow in either direction depending on the pressure gradient [3, 10]. The emergent theory of a link between the lymphatic drainage and the venous intracranial system may modify our thinking about cerebral venous septic thrombosis. Nevertheless, as of now, the exact mechanism of septic thrombosis remains unclear. There are few hypothesis, some authors think that infection may trigger thrombosis directly by causing septic thrombosis or indirectly by precipitating thrombosis in risk-patients due to predisposing thrombophilia [3, 4, 13].

The infection may spread within veins or as septic emboli that get trapped within the trabeculations of cavernous sinuses [3, 4, 13].

Bacteria are potent inducers of thrombosis and thrombus in turn is a great growth medium for bacteria [4, 13]. Bacteria trapped in the deeper layers of thrombus may be protected from antibiotic penetration and can become source of infection [4, 13].

Some predisposing brain conditions were also identified such as meningitis, abscess, empyema as well as cerebral infarcts which can be a source of direct spread of microorganisms to the cerebral venous sinuses [1, 14].

Clinic

The onset of the disease is usually acute in patients with septic cerebral venous thrombosis [3]. The latent period between primary infection of face or nose and the development of septic CVT is usually less than a week [10, 15].

Patients with more fulminant disease manifest most of the symptoms and signs early in the disease [4, 15, 16].

Fever is usually present. The pattern of temperature is "picket fence" suggestive of thrombophlebitis [17]. Signs of sepsis may be seen including tachycardia, and hypotension, which can progress to confusion and coma [17].

Transverse sinuses' septic thrombosis is usually a complication of middle ear infection or mastoiditis and patients usually present with the features of primary site infection along with symptoms and signs of raised intracranial pressure and focal neurological signs [3].

Fever and generalized malaise neck pain and stiffness focal neurological symptoms can develop due to intracranial involvement which can occur due to venous

congestion or infarction are common with transverse location [3, 18].

As was demonstrated earlier, the infection may spread to superior sagittal sinus via the diploic veins, but also from the transverse sinus that receives venous drainage from the middle ear and the mastoid. A reflex shall be to consider sagittal sinus thrombosis in case of ear infection as well as all brain infectious conditions.

Extensive septic thrombosis may be associated with complications including meningitis, brain abscess, and subdural empyema and infarcts may be the manifestation of [1, 16].

Etiology

Bacterial infections are the most common cause of septic cerebral venous thrombosis. Nevertheless, other pathogens have been documented as well viral:

- Bacterial infections: staphylococcus aureus is the most identified organism, followed by streptococcal species, gram-negative organisms, and anaerobes [1, 3, 10, 16].
- Viral infections such as cytomegalovirus, herpes simplex, measles, hepatitis, and HIV [3, 14].
- Fungal infections including aspergillus, mucormycosis, and coccidioidomycosis [3]. Parasitic infections including malaria, trichinosis, and toxoplasmosis have also been reported [3, 14].

But what we have to keep in mind that the primary pathogens to cause septic cerebral thrombosis are bacteria.

Biology

D-Dimers

They are highly sensitive but not very specific, showing some variability during tumoral, infectious, or inflammatory pathologies [19], which is the case of our patient. If negative, they eliminate the diagnosis of venous thrombosis [19]. They are particularly interesting in the surveillance of thromboembolic disease and in the detection of possible recurrences [20].

Determination of coagulation factors for protein or C deficiency

Septic cerebral venous thrombosis is frequently associated with thrombophilic states. Infection was a common trigger of cerebral venous thrombosis in previously healthy children. In two studies of pediatric population, which studied the association between infection and cerebral venous thrombosis, children were screened for thrombophilia, among them 62–70% had one or more prothrombotic condition [21, 22].

Saposnik et al. recommend screening for potential prothrombotic conditions like the use of contraceptives, underlying inflammatory or infectious conditions in the initial stage [23].

Imaging

Modern imaging plays an important role in the establishment of the positive diagnosis, detect complications as well as look for an etiology of cerebral venous thrombosis.

The imaging means differ according to the topography of the thrombosis, but the appearance of the thrombus is the same:

- Sonography: intraluminal, mobile, or fixed echoic image.
- CT: it is a hyperdense endovascular image in spontaneous contrast, hypodense after injection and surrounded by the contrast medium.
- MRI: an endovascular hypointensity in T2 and a defect in T1 with gadolinium injection. Magnetic resonance imaging (MRI) is the modality of choice for the exploration of cerebral venous thrombosis. There are several findings described in the literature. The most obvious are parenchymal lesions, which show some variabilities with time. The earliest changes are related to the appearance of a vasogenic edema, which translates into subcortical hypointense zones in T1 and hyperintense in fluid attenuated inversion recovery (FLAIR) [24, 25].

In later stages, hemorrhagic foci develop signaling a blood–brain barrier rupture; in this case, the T2 gradient echosequence remains the more sensitive by demonstrating a hypointense signal within the hemorrhagic zone. Subarachnoid hemorrhage can be viewed as a hypointensity in the cerebral cortex surface in gradient echosequences. Thickening and contrast enhancement are of the dura mater which is noted near the thrombosis, but also at the level of adjacent leptomeninges [25, 26].

MRI-angiography confirms the absence of flux at the thrombosed sinus and appreciate the extension of thrombosis; it evaluates the reversal of the sinus waning of anticoagulation but it cannot be used in case of contraindication to gadolinium injection (gadolinium allergy, history of transplantation, and renal failure) [27]. Nevertheless, the difficulty of accessing MRI in the emergency context and the need for a suitable technical platform make CT the examination indicated in the emergency context [27].

Cerebral CT may reveal cerebral venous thrombosis in the presence of signs of neurological localization related to either intracerebral hematoma, which results in corticosubcortical hyperdensity whose topography is directly related to the site of venous thrombosis, or to a softening venous vasogenic edema and corticosubcortical hypodensity [28].

Thrombosis of the superior sagittal sinus induces hemorrhagic edematous or hemorrhagic venous ischemia localized in parasagittal regions fronto-parieto-occipital; the involvement of the transverse sinus induces lower temporo-occipital lesions or cerebellar lesions [27]. Any

densitometric abnormality in these areas should lead to a systematic and careful examination of sinus densities and adjacent cortical veins. The venous thrombus is spontaneously hyperdense; the hyperdensity appears early, but decreases markedly after the eighth day [28]. In the case of thrombosis, the sinus density is usually greater than 70 Hounsfield unit (HU) [28]. The injection of contrast medium often displays a sign of the “delta” or the “empty triangle” corresponding to the enhancement sinus walls, while the light of the sinuses is not enhanced due to the presence of an intraluminal thrombus; this sign appears from the fifth day and persists for two months [29]. The spontaneous hyperdensity of a cortical vein (“sign of the rope”) remains an inconstant sign; the sections obtained after injection can demonstrate intraluminal hypodensity associated with a contrast enhancement the venous wall; multiplanar reformations are useful to demonstrate the anomaly [29].

The most frequently associated CT signs were cerebral edema, parenchymal hematoma in the venous drainage area, leptomeningeal contrast enhancement as well as subarachnoid hemorrhage.

Management and treatment

The mainstay of treatment is the management of underlying infection by an early initiation of antibiotherapy and systemic stabilization of the patient. The initial choice of intravenous antibiotics should be made keeping in view the most common organisms involved in the suspected site of origin. A reasonable initial combination may include ceftriaxone, vancomycin, and metronidazole to cover the broadest spectrum [3, 16].

Another suggested regimen is a combination of a third generation cephalosporin, nafcillin, and metronidazole [17].

The total duration of therapy is not clearly established, and should depend on the clinical response, the primary site of infection, and associated complications, but a minimum of 3–4 weeks of intravenous therapy is required [10, 16, 17]. The role of steroids is not well established in the management of septic cerebral venous thrombosis. They may help in decreasing the inflammation and swelling, however, its use is not well supported by evidence and must be weighted, as it induces an immunosuppressive as well as a prothrombotic condition [16, 17].

Although anticoagulation is preconized in case of aseptic thrombosis, its use remains controversial in the management of septic thrombosis is controversial. The advantage of anticoagulation therapy is prevention of the propagation of thrombus, as well as possible inhibition of platelet function and anti-inflammatory effect [13]. But these effects come with risks, it may trigger an intracranial or systemic hemorrhage and a dissemination of infection [13, 30]. However, the reported incidence of hemorrhage with the use of anticoagulation is extremely low. Most of the literature is based on retrospective analysis. The number of patients included in the reviews is also small to draw definitive conclusions [31]. The most recent studies

favor the use of anticoagulation along with antibiotics early in the management, as there is a significant reduction in morbidity. Nevertheless there are no clear protocol as of yet in the pediatric population [13, 30].

Surgical treatment is reserved for the suspected site of infection, which may require drainage of non-draining sites of primary infection foci [1, 13, 31].

CONCLUSION

In general, CVT is a disease with complex clinical manifestations, atypical in many patients. If an alteration of consciousness is the main symptom in a CVT patient, the prognosis can be bleak. Most patients with CVT have a good prognosis after early anticoagulant and antibiotherapy. Since cerebral hernia is the most common cause of death in CVT, intensive care should be given special attention to the detection and treatment of focal lesions occupying space.

REFERENCES

- DiNubile MJ, Boom WH, Southwick FS. Septic cortical thrombophlebitis. *J Infect Dis* 1990;161(6):1216–20.
- Sharma AA, Jen R, Butler A, Lavoie PM. The developing human preterm neonatal immune system: A case for more research in this area. *Clin Immunol* 2012;145(1):61–8.
- Kojan S, Al-Jumah M. Infection related cerebral venous thrombosis. *J Pak Med Assoc* 2006;56(11):494–7.
- Pavlovich P, Looi A, Rootman J. Septic thrombosis of the cavernous sinus: Two different mechanisms. *Orbit* 2006;25(1):39–43.
- Mahajerin A, Croteau SE. Epidemiology and risk assessment of pediatric venous thromboembolism. *Front Pediatr* 2017;5:68.
- Gerotziafas GT. Risk factors for venous thromboembolism in children. *Int Angiol* 2004;23(3):195–205.
- Jung HL. Venous thromboembolism in children and adolescents. *Blood Res* 2016;51(3):149–51.
- Felten DL, O'Banion MK, Maida MS. *Netter's Atlas of Neuroscience*. 3ed. Philadelphia: Elsevier - Health Sciences Division; 2015.
- Seker A, Martins C, Rhoton AL. Meningeal anatomy. In: Pamir MN, Black MP, Fahlbusch R, editors. *Meningiomas*. Amsterdam: Elsevier; 2010. p. 11–51.
- DiNubile MJ. Septic thrombosis of the cavernous sinuses. *Arch Neurol* 1988;45(5):567–72.
- Raper D, Louveau A, Kipnis J. How do meningeal lymphatic vessels drain the CNS? *Trends Neurosci* 2016;39(9):581–6.
- Louveau A, Smirnov I, Keyes TJ, et al. Structural and functional features of central nervous system lymphatic vessels. *Nature* 2015;523(7560):337–41.
- Bhatia K, Jones NS. Septic cavernous sinus thrombosis secondary to sinusitis: Are anticoagulants indicated? A review of the literature. *J Laryngol Otol* 2002;116(9):667–76.
- Saadatnia M, Fatehi F, Basiri K, Mousavi SA, Mehr GK. Cerebral venous sinus thrombosis risk factors. *Int J Stroke* 2009;4(2):111–23.
- Chen HW, Su CP, Su DH, Chen HW, Chen YC. Septic cavernous sinus thrombosis: An unusual and fatal disease. *J Formos Med Assoc* 2006;105(3):203–9.
- Ebright JR, Pace MT, Niazi AF. Septic thrombosis of the cavernous sinuses. *Arch Intern Med* 2001;161(22):2671–6.
- Desa V, Green R. Cavernous sinus thrombosis: Current therapy. *J Oral Maxillofac Surg* 2012;70(9):2085–91.
- Tveterås K, Kristensen S, Dommerby H. Septic cavernous and lateral sinus thrombosis: Modern diagnostic and therapeutic principles. *J Laryngol Otol* 1988;102(10):877–82.
- Alons IM, Jellema K, Wermer MJ, Algra A. D-dimer for the exclusion of cerebral venous thrombosis: A meta-analysis of low risk patients with isolated headache. *BMC Neurol* 2015;15:118.
- Palareti G, Legnani C, Cosmi B, Guazzaloca G, Pancani C, Coccheri S. Risk of venous thromboembolism recurrence: High negative predictive value of D-dimer performed after oral anticoagulation is stopped. *Thromb Haemost* 2002;87(1):7–12.
- Sébire G, Tabarki B, Saunders DE, et al. Cerebral venous sinus thrombosis in children: Risk factors, presentation, diagnosis and outcome. *Brain* 2005;128(Pt 3):477–89.
- Oestreicher-Kedem Y, Raveh E, Kornreich L, Yaniv I, Tamary H. Prothrombotic factors in children with otitis media and sinus thrombosis. *Laryngoscope* 2004;114(1):90–5.
- Saposnik G, Barinagarrementeria F, Brown RD Jr, et al. Diagnosis and management of cerebral venous thrombosis: A statement for healthcare professionals from the American Heart Association/American Stroke Association. *Stroke* 2011;42(4):1158–92.
- Chu K, Kang DW, Yoon BW, Roh JK. Diffusion-weighted magnetic resonance in cerebral venous thrombosis. *Arch Neurol* 2001;58(10):1569–76.
- Ducieux D, Oppenheim C, Vandamme X, et al. Diffusion-weighted imaging patterns of brain damage associated with cerebral venous thrombosis. *AJNR Am J Neuroradiol* 2001;22(2):261–8.
- Lafitte F, Boukobza M, Guichard JP, et al. MRI and MRA for diagnosis and follow-up of cerebral venous thrombosis (CVT). *Clin Radiol* 1997;52(9):672–9.
- Dietemann JL. *Neuro-Imagerie Diagnostique*. France: Elsevier Health Sciences; 2018.
- Black DF, Rad A, Gray L, Campeau NG, Kallmes DF. Cerebral venous sinus density on noncontrast CT correlates with hematocrit. *AJNR Am J Neuroradiol* 2011;32(7):1354–7.
- Crassard I, Ameri A, Rougemont D, Bousser MG. *Thromboses veineuses cérébrales*. EMC - Neurologie 2012;9(3):1–14.
- Levine SR, Twyman RE, Gilman S. The role of anticoagulation in cavernous sinus thrombosis. *Neurology* 1988;38(4):517–22.
- Southwick FS, Richardson EP Jr, Swartz MN. Septic thrombosis of the dural venous sinuses. *Medicine (Baltimore)* 1986;65(2):82–106.

Author Contributions

Yassine Smiti – Acquisition of data, Drafting the work, Revising the work critically for important intellectual content, Final approval of the version to be published, Agree to be accountable for all aspects of the work in ensuring that questions related to the accuracy or integrity of any part of the work are appropriately investigated and resolved

Lemssiah Adib – Acquisition of data, Drafting the work, Revising the work critically for important intellectual content, Final approval of the version to be published, Agree to be accountable for all aspects of the work in ensuring that questions related to the accuracy or integrity of any part of the work are appropriately investigated and resolved

Aziza Bentalha – Acquisition of data, Drafting the work, Revising the work critically for important intellectual content, Final approval of the version to be published, Agree to be accountable for all aspects of the work in ensuring that questions related to the accuracy or integrity of any part of the work are appropriately investigated and resolved

Alae El Koraichi – Acquisition of data, Drafting the work, Revising the work critically for important intellectual content, Final approval of the version to be published, Agree to be accountable for all aspects of the work in ensuring that questions related to the accuracy or integrity of any part of the work are appropriately investigated and resolved

Leghlimi Hasnaa – Acquisition of data, Drafting the work, Revising the work critically for important intellectual content, Final approval of the version to be published, Agree to be accountable for all aspects of the work in ensuring that questions related to the accuracy or integrity of any part of the work are appropriately investigated and resolved

Salma Ech-Cherif El Kettani – Acquisition of data, Drafting the work, Revising the work critically for important intellectual content, Final approval of the version to be published, Agree to be accountable for all aspects of the work in ensuring that questions related to the accuracy or integrity of any part of the work are appropriately investigated and resolved

Othman Ayouche – Acquisition of data, Drafting the work, Revising the work critically for important intellectual content, Final approval of the version to be published, Agree to be accountable for all aspects of the work in ensuring that questions related to the accuracy or integrity of any part of the work are appropriately investigated and resolved

Asaad El Bakkari – Acquisition of data, Drafting the work, Revising the work critically for important intellectual content, Final approval of the version to be published, Agree to be accountable for all aspects of the work in ensuring that questions related to the accuracy or integrity of any part of the work are appropriately investigated and resolved

Nazik Allali – Acquisition of data, Drafting the work, Revising the work critically for important intellectual content, Final approval of the version to be published, Agree to be accountable for all aspects of the work in ensuring that questions related to the accuracy or integrity of any part of the work are appropriately investigated and resolved

Latifa Chat – Acquisition of data, Drafting the work, Revising the work critically for important intellectual content, Final approval of the version to be published, Agree to be accountable for all aspects of the work in ensuring that questions related to the accuracy or integrity of any part of the work are appropriately investigated and resolved

Guarantor of Submission

The corresponding author is the guarantor of submission.

Source of Support

None.

Consent Statement

Written informed consent was obtained from the patient for publication of this article.

Conflict of Interest

Authors declare no conflict of interest.

Data Availability

All relevant data are within the paper and its Supporting Information files.

Copyright

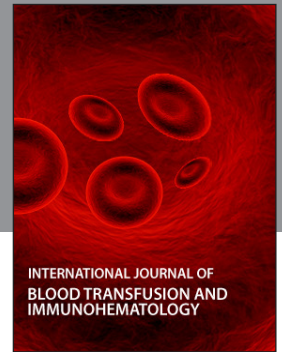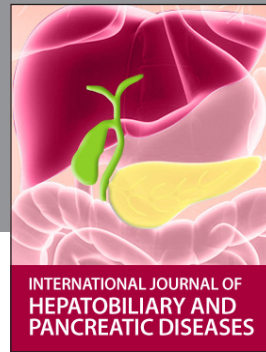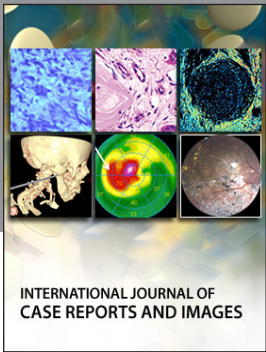
© 2019 Yassine Smiti et al. This article is distributed under the terms of Creative Commons Attribution License which permits unrestricted use, distribution and reproduction in any medium provided the original author(s) and original publisher are properly credited. Please see the copyright policy on the journal website for more information.

Access full text article on
other devices



Access PDF of article on
other devices





Submit your manuscripts at
www.edoriumjournals.com

