

Juvenile xanthogranuloma-related central diabetes insipidus and pregnancy: Case report and literature review

Ana Luiza Pessoa De Resende, Paulo Sergio França,
Gustavo Henrique Soares Takano, Florêncio Figueiredo Cavalcante Neto

CASE REPORT

A 27-year-old patient, G1POA0, presented with diabetes insipidus caused by juvenile xanthogranuloma, diagnosed at 11 years of age due to the appearance of xanthomas in the skin and central nervous system (CNS). Skin biopsy evidenced the presence of numerous foamy cytoplasm cells and Touton giant cells, expressing CD-68 and S100 protein (Figures 1 and 2). She was followed up at the High-Risk Prenatal Care Unit of the University of Brasilia Hospital, together with the Endocrinology Team. On the eighth month of gestation, it was necessary to increase the number of nasal desmopressin puffs from three to seven per day (0.1–2.5 mg/ml); no other alterations were observed in the pre-natal period. A C-section delivery was performed at 39 weeks and 3 days, due to fetal tachysystole observed at cardiotocography. The child was born at term, with Apgar score of 8/8 and weighing 4,015 g. The anatomopathological assessment of the placenta did not evidence any alterations. After delivery, the desmopressin dose was reduced back to three puffs per day. In the post-delivery consultation, the patient was clinically stable.

DISCUSSION

Diabetes insipidus is a rare condition in pregnancy that affects approximately two to four women per

Ana Luiza Pessoa De Resende¹, Paulo Sergio França¹,
Gustavo Henrique Soares Takano², Florêncio Figueiredo
Cavalcante Neto²

Affiliations: ¹Department of Obstetrics and Gynecology, University Hospital of Brasilia, Brazil; ²Department of Pathology, University Hospital of Brasilia, Brazil.

Corresponding Author: Ana Luiza Pessoa De Resende, Department of Obstetrics and Gynecology, University Hospital of Brasilia, Brazil; Email: analuizapr@gmail.com

Received: 22 May 2019
Accepted: 13 June 2019
Published: 20 August 2019

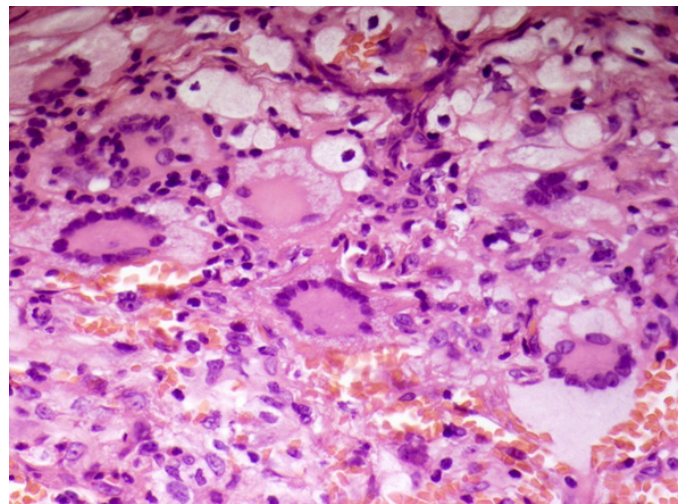


Figure 1: Touton giant cell details.

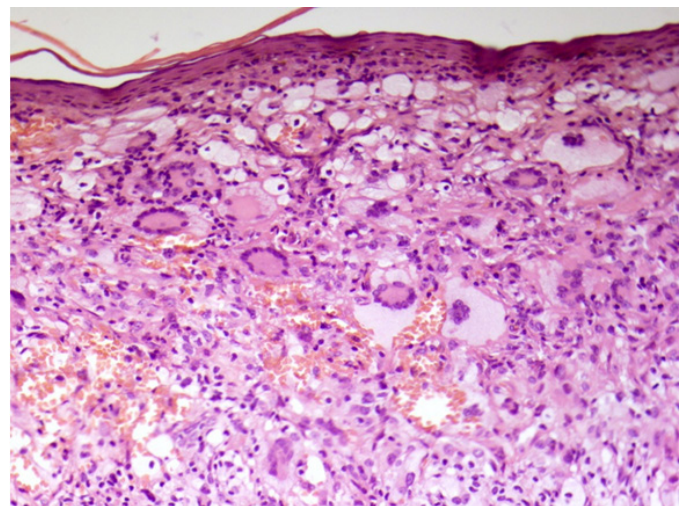


Figure 2: Histiocytic infiltrate and Touton giant cells.

100,000 pregnancies [1–3]. In the past 30 years, few cases have been reported; some cases probably go unnoticed because the symptoms are confused with those of a normal gestation [1, 4].

In pregnancy, there is a decrease in plasma osmolality of about 10 mOsm/kg, which in turn results from the

adjustment of the thirst threshold [1]. The metabolic clearance of ADH increases by up to six times between the 8th and the 20th week of pregnancy. Furthermore, the placental syncytiotrophoblast plays a significant role in the production of vasopressinase (aminopeptidase), which degrades ADH. The action of this enzyme is directly proportional to the weight of the placenta. It increases gradually during gestation, reaching its peak in the third trimester, as does antidiuretic hormone (ADH) [3, 4].

The treatment of choice is desmopressin (DDAVP), an analog of ADH with a different N-terminal chain, which prevents it from being degraded by placental vasopressinase [2, 5]. It can be administered through several routes; the nasal route is preferred due to its rapid absorption and convenience [2, 5].

CONCLUSION

Gestational diabetes insipidus does not appear to entail serious complications throughout pregnancy. With early diagnosis, correct treatment, and good prenatal follow-up, the prognosis is favorable, leading to a pregnancy with low maternal and fetal morbimortality.

Keywords: Diabetes insipidus, Gestational diabetes insipidus, Juvenile xanthogranuloma, Touton giant cell

How to cite this article

De Resende ALP, França PS, Takano GHS, Neto FFC. Juvenile xanthogranuloma-related central diabetes insipidus and pregnancy: Case report and literature review. Int J Case Rep Images 2019;10:101043Z01AR2019.

Article ID: 101043Z01AR2019

doi: 10.5348/101043Z01AR2019CR

REFERENCES

1. Chanson P, Salenave S. Diabetes insipidus and pregnancy. *Ann Endocrinol (Paris)* 2016;77(2):135–8.
2. Quigley J, Shelton C, Issa B, Sripada S. Diabetes insipidus in pregnancy. *The Obstetrician & Gynaecologist* 2018;20(1):41–8.
3. Marques P, Gunawardana K, Grossman A. Transient diabetes insipidus in pregnancy. *Endocrinol Diabetes Metab Case Rep* 2015;2015:150078.

4. Aleksandrov N, Audibert F, Bedard MJ, Mahone M, Goffinet F, Kadoch IJ. Gestational diabetes insipidus: A review of an underdiagnosed condition. *J Obstet Gynaecol Can* 2010;32(3):225–31.
5. Del Carpio-Orantes L. Transient central diabetes insipidus associated with pregnancy. Case report and bibliography review. [Article in Spanish]. *Rev Med Inst Mex Seguro Soc* 2017;55(5):672–5.

Author Contributions

Ana Luiza Pessoa De Resende – Conception of the work, Design of the work, Acquisition of data, Analysis of data, Interpretation of data, Drafting the work, Revising the work critically for important intellectual content, Final approval of the version to be published, Agree to be accountable for all aspects of the work in ensuring that questions related to the accuracy or integrity of any part of the work are appropriately investigated and resolved

Paulo Sergio França – Conception of the work, Design of the work, Acquisition of data, Analysis of data, Interpretation of data, Drafting the work, Revising the work critically for important intellectual content, Final approval of the version to be published, Agree to be accountable for all aspects of the work in ensuring that questions related to the accuracy or integrity of any part of the work are appropriately investigated and resolved

Gustavo Henrique Soares Takano – Conception of the work, Design of the work, Acquisition of data, Analysis of data, Interpretation of data, Drafting the work, Revising the work critically for important intellectual content, Final approval of the version to be published, Agree to be accountable for all aspects of the work in ensuring that questions related to the accuracy or integrity of any part of the work are appropriately investigated and resolved

Florêncio Figueiredo Cavalcante Neto – Conception of the work, Design of the work, Acquisition of data, Analysis of data, Interpretation of data, Drafting the work, Revising the work critically for important intellectual content, Final approval of the version to be published, Agree to be accountable for all aspects of the work in ensuring that questions related to the accuracy or integrity of any part of the work are appropriately investigated and resolved

Guarantor of Submission

The corresponding author is the guarantor of submission.

Source of Support

None.

Consent Statement

Written informed consent was obtained from the patient for publication of this article.

Conflict of Interest

Authors declare no conflict of interest.

Data Availability

All relevant data are within the paper and its Supporting Information files.

Copyright

© 2019 Ana Luiza Pessoa De Resende et al. This article is distributed under the terms of Creative Commons

Attribution License which permits unrestricted use, distribution and reproduction in any medium provided the original author(s) and original publisher are properly credited. Please see the copyright policy on the journal website for more information.

Access full text article on other devices



Access PDF of article on other devices





Submit your manuscripts at
www.edoriumjournals.com

