

# Umbilical artery catheterization a cause of abdominal aortic thrombosis in neonates: A case report

El Bakkari Asaad, Othman Ayouche, Smiti Yassine,  
Dahbi Youssef, Salmi Najlaa, Nazik Allali, Latifa Chat

## ABSTRACT

**Introduction:** Aortic thromboembolism is relatively common among patients following cardiovascular procedures and trauma. The abdominal aorta is the most common site for thrombosis, especially its distal portion. Based on the Virchow triad, thrombosis is caused by an imbalance among endothelium, blood flow, and coagulation. Inherited or acquired hypercoagulable states play a key role in thrombus formation in both the arterial and venous system. Elevated levels of C-reactive protein, homocysteine and lipoprotein (a) are more likely to be involved with arterial thrombus. Antiphospholipid antibodies are associated with both venous and arterial thromboembolic events. The advent of new radiologic modalities, with more noninvasive techniques, has allowed for early diagnostics and treatment of these entities, in neonatal population. **Case Report:** We report the case of five days newborn, with a sepsis history due to foeto-maternal infection, who needed an umbilical catheter for monitoring. Three days later, he presented with distal ischemia an abolition of femoral artery pulses in front of that we conducted a Doppler ultrasound (US) and a computed tomography (CT) angiography, which demonstrated an inframesenteric aorta thrombosis which extended to the iliac axes. No surgery was necessary, and an anti-thrombin

treatment was conducted. No complications were noted in follow-up exams. **Conclusion:** Radiologists should keep in mind that abdominal aortic thrombosis, even if it is a rare entity, could complicate many conditions altering the Virchow triad. Arterial thrombosis is often due to a parietal mechanism, for example, umbilical catheters. Sonography is the modality of choice for first line diagnosis in neonates. Contrast-enhanced CT is recommended for the diagnosis of pseudo-occlusion and determines the treatment choice.

**Keywords:** Aortic thrombosis, Computed tomography, Newborn, Ultrasound, Umbilical

### How to cite this article

Asaad EB, Ayouche O, Yassine S, Youssef D, Najlaa S, Allali N, Chat L. Umbilical artery catheterization a cause of abdominal aortic thrombosis in neonates: A case report. Int J Case Rep Images 2019;10:101037Z01EA2019.

Article ID: 101037Z01EA2019

\*\*\*\*\*

doi: 10.5348/101037Z01EA2019CR

El Bakkari Asaad<sup>1</sup>, Othman Ayouche<sup>1</sup>, Smiti Yassine<sup>1</sup>, Dahbi Youssef<sup>1</sup>, Salmi Najlaa<sup>1</sup>, Nazik Allali<sup>1</sup>, Latifa Chat<sup>1</sup>

**Affiliation:** <sup>1</sup>Children's Hospital, Ibn Sina Hospital, Mohamed V University, Rabat, Morocco.

**Corresponding Author:** El Bakkari Asaad, Children's Hospital, Ibn Sina Hospital, Mohamed V University, Rabat, Morocco; Email: elbakkari.asaad@gmail.com

Received: 30 March 2019

Accepted: 06 April 2019

Published: 22 July 2019

## INTRODUCTION

Aortic thromboembolism is common among patients who have undergone vascular procedures [1]. The abdominal aorta is the most common site for thrombosis, especially its distal portion [2].

Thrombosis is caused by an imbalance among the different factors of the Virchow triad endothelium, blood flow, and coagulation. Inherited or acquired hypercoagulable states play a key role in thrombus formation in both the arterial and venous system.

Among the biological anomalies discovered during blood analysis, we tend to associate elevated levels of C-reactive protein with arterial thrombus [1, 2]. In emergencies, the use of an umbilical catheter is common as the peripheral vessels of the newborn are sometimes difficult to access. Umbilical arterial catheter placement is indicated:

- To ensure a central perfusion of drugs, blood products, hypertonic solutes, or vasoactive products when the child is in great respiratory distress.
- Blood exchange transfusion.
- It is an emergency lane in the resuscitation room at birth, for the injection of cardiotoxic products in case of vasoplegia.
- Continuous monitoring of blood pressure and repeated blood samples.
- In case of failure of peripheral venous access or the exhaustion of peripheral venous capital.

The placement of an umbilical arterial catheter is contraindicated for newborns with parietal abdominal defect, such as omphalocele and gastroschisis, as well as omphalitis, which is an umbilical cord inflammation, or peritonitis.

Contrast-enhanced CT is the imaging modality of choice to investigate the disorder as it is widely available, noninvasive, and relatively cheap and can identify the extension of the thrombi in a perfect way and enable evaluation of the possible complications that are mainly of ischemic nature.

## CASE REPORT

We report the case of a newborn admitted in the Neonatal Intensive Care Units for meconium aspiration and sepsis. On admission, we observed some severe clinical symptoms: hypothermia, cyanosis, feeding difficulties, lethargy, upon which an umbilical catheterization to monitor arterial pressure was preconized. The technique utilized to perform arterial umbilical catheterization is as follows: The newborn was placed in supine position, immobilizing his arms and legs.

- Lift the umbilical cord.
- Disinfection: Asepsis of skin and cord with alcoholic chlorhexidine at 0.5%.
- Put the pierced field sterile and a sterile lace around the umbilical cord.
- Cut the umbilical cord with the scalpel about 10 mm of its parietal implantation.
- Identify the two umbilical arteries and insert the Ch 5 catheter previously purged of all air with 0.9% NaCl. The estimated insertion length was of 7 cm.
- Fixation suture on Wharton's jelly and Steri-Strips.

Three days later, the evolution was marked by a bilateral abolition of pulses of femoral artery's pulses as well as signs of poor extremity perfusion (cyanosis, and

an alteration of the conscious state). These symptoms lead to a radiological exploration.

First, we conducted a pulsed and Doppler abdominal US that demonstrated an intraluminal hyperechoic material in the abdominal aorta with a decrease in circulating flux and a color Doppler aliasing and local velocities acceleration. The iliac and femoral flows were demodulated and damped.

Second, we realized a CT angiography for better exploration of the thrombosis extension. We found a complete low dense intraluminal clot of the inframesenteric aorta extending to the iliac axes without visceral ischemia signs, non-enhancing after contrast injection (Figures 1 and 2). An initial biological coagulation exploration; blood count, prothrombin time, activated cephalin time; was found normal. I have level of homocysteinemia at 16  $\mu\text{mol/l}$  (normal between 4 and 14). There was no deficiency of ATIII, protein C or S, no mutation of the factor II gene or factor V Leiden. There was no inflammatory syndrome or autoantibodies, especially anti-phospholipid antibodies. The presence of periaortic lymph nodes, whose anatomopathological examination showed only an inflammatory aspect, led to the completion of a thorough paraneoplastic etiological assessment. Gastroscopy, colonoscopy, and thoracoabdominal CT were normal.

The evolution was marked by a clinical improvement under anticoagulant treatment (low molecular weight heparin). Follow-up at one year did not allow an etiological diagnosis, leaving the only cause of umbilical

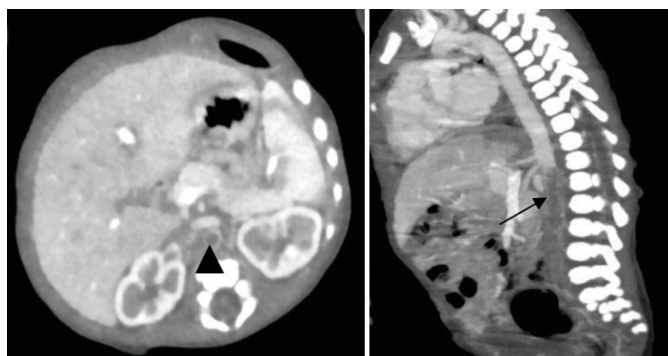


Figure 1: Sagittal and axial view, C+ arterial phase: Partially thrombosed inframesenteric aorta extending to the iliac arteries.

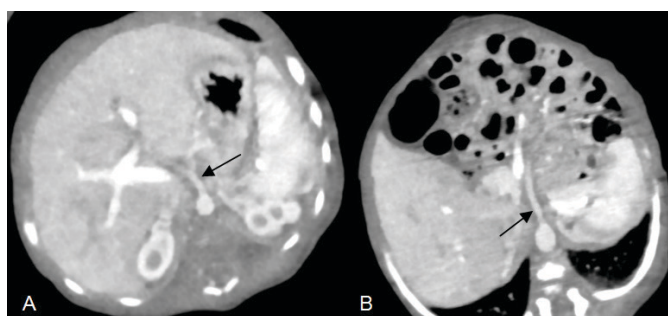


Figure 2: Axial view CT angiography shows opacification of both the coeliac trunk and the superior mesenteric artery.

catheterization, which remains the first cause of aortic thrombosis of the newborn in third world countries.

## DISCUSSION

Aortic thrombosis in neonatal period is usually a mortal event. It is often associated with a lot of predisposing conditions, which alter the Virchow. Thrombosis is the coagulation of blood in a vascular cavity (heart, artery, vein, and capillary) during the course of life. The definition excludes blood clots formed after death and hematoma, a collection of blood coagulated out of a vascular cavity [3–6].

Three main factors, whose respective importance varies according to the pathological situations, are involved in the formation of a thrombus. This is Virchow's triad, which is composed of three factors [3–6]: Parietal factor: It is a lesion of the vascular wall leading to an interruption of the endothelium: it allows the contact between the blood and the subendothelial extracellular matrix. This factor is the only one necessary for the constitution of a thrombosis and which is sufficient on its own to trigger the thrombotic process. It is often isolated in arterial and intracardiac thromboses. Also included in the parietal mechanisms are certain conditions in which there is no true endothelial destruction, but a procoagulant endothelial activation losing the thromboresistance properties of the endothelium (under the effect of bacterial toxins).

- Its causes are many: trauma: compression or vascular contusion, circulatory turbulence: at the level of valvulae or vascular junctions, inflammation: arteritis, phlebitis, septic phenomena of neighborhood.
- Hemodynamic factor: Stasis is a predominant factor in the formation of venous thromboses. It also causes endothelial pain by hypoxia. It favors especially the increase in size of an already constituted microthrombosis. The causes of blood stasis in arteries are aneurysms, hypotension.
- Blood factor or hypercoagulability includes all the alterations of the coagulation pathways favoring thrombosis. Hypercoagulability is more inconstantly involved in the constitution of thromboses than the two preceding factors, but constitutes an undeniable risk factor for patients who suffer from it. Its causes include genetic or acquired blood clotting diseases; states of blood hyperviscosity (polycythemia, hemoconcentration).

The morphology of the arterial thrombus vary with time can take various aspects, which depend on its location and its circumstances of appearance. The recent thrombus usually appears at the level of an endothelial lesion (atherosclerotic plaque) or an area of turbulence (aneurysm). It adheres to the vascular wall at the level of the original lesion, and extend in a retrograde manner [3, 4].

The degree of obliteration of the vascular conduit is variable, totally obliterating thrombus: this is most often seen in thrombi of small- or medium-sized arteries, partially obliterating or mural thrombus: large- and medium-sized arteries, heart.

If the thrombus is not responsible for the immediate death, the following evolutions could be observed [3, 4, 6]: Thrombolysis: It is the destruction of the thrombus by the fibrinolytic enzymes of the plasma, with restoration of the vascular permeability. It is actually a rare event but could be triggered by therapy. It is especially possible in the case of small and recent thrombi.

- Thrombus organization: This is the most common event. A fibrous organization starts at the 48th hour.
- Migration of the thrombus: This is the rupture of all or part of the thrombus with migration into the blood stream constituting an embolus.
- Softening of the thrombus: This is a rare development, which results from the action of polynuclear enzymes present in the thrombus. Softening can occur on recent aseptic thrombus, and promote its migration.

Arterial thrombosis is essentially triggered by the parietal factor, that is to say the alteration of the arterial wall, post-catheterization thrombosis is frequently described cause in neonates.

Clinical manifestations are usually nonspecific, with a predominance of severe perinatal asphyxia, hypertension as well as distal cyanosis. Some neonates also exhibit sign of mesenteric ischemia or renal failure [7].

The role of radiology is to diagnose thrombosis and to evaluate its relationship to the adjacent structures as well as the prevention of further complications. Radiological features of thrombosis are often pathognomonic.

Doppler US helps establish the diagnosis in neonatal period. On B-mode images, the aorta is located in front of the lumbar spine, left of the inferior vena cava. It is scanned in axial section in B (+ harmonic) mode in order to define its path (vertical or sinuous) then the lesion is analyzed in axial section perpendicular to the central line of the aorta and in longitudinal section aligned on the center line, in B and duplex mode [8].

A parietal thrombus can be difficult to see in case repetition echoes in the intra-aortic lumen. Abdominal aorta thrombosis often involves its distal portion and encases the origin of the iliac arteries. It exists a decrease in circulating flux with an "aliasing" in color Doppler and local velocities acceleration. The iliac flows are demodulated and damped: monophasic flow with increased systolic rise time [8, 9].

In case of abdominal aorta total occlusion, no color signal is recorded in the arterial lumen. The flows recorded in the iliac arteries are demodulated. One of the most important thing to do is to describe the diameter and the wall of the aorta to approach the possible mechanism of occlusion [8, 9].

Contrast-enhanced CT also plays a very important role in the evaluation of arterial thrombosis. Because of its high resolution, it is possible to visualize very fine circulating channels showing pseudo-occlusions. It is also useful thanks to the axial sections to place the vessels in their anatomical environment in order to create a better distinction from veins [10].

Therapies are variable as the damages caused by arterial clotting: they range from simple watchful waiting to open surgery as well as interventional radiology techniques. In neonatal period, only supportive therapy is preconized in most cases [11].

Among these, the most indicated therapies for patients with multivisceral attack with a conservation of renal function are, in the absence of contraindication, thrombolysis [7, 12]:

- Heparinization:
  - 1.5 mg/kg/12 h for neonates less than two months.
  - 1 mg/kg/12 h for neonates more than two months.
- Tissue plasminogen activators: T-PA is administered, with a dosage of 1 mg/kg for a duration of 4 hours, as a continuous infusion of >0.25 mg/kg/h preceded by a loading dose of 0.1 mg/kg bolus.

Follow-up exams are mainly comprised of Doppler US for distal vascular complication.

In our case, we decided for a heparin therapy with at a dose of 1 mg/kg/12 h was given for 15 days with a biological surveillance of activated cephalin time due to a nonavailability of anti-Xa dosage; and a daily Doppler US surveillance, as we suspected catheterization for the thrombi origin [13]. There was no attempt of thrombolysis with tissue plasminogen activator, which is indicated for post-catheter arterial thrombosis [7]. The evolution was characterized by a clinical amelioration and the resolution of the cloth by using heparin therapy.

## CONCLUSION

Radiologists should keep in mind that abdominal aorta clots, even if it is a rare entity, could complicate many conditions altering the Virchow triad. Arterial thrombosis are often due to a parietal mechanism, for example, umbilical catheters. Sonography is the modality of choice for first line diagnosis in neonates. Contrast-enhanced CT is recommended for the diagnosis of pseudo-occlusion and determines the treatment choice.

## REFERENCES

1. Boo NY, Wong NC, Zulkifli SS, Lye MS. Risk factors associated with umbilical vascular catheter-associated thrombosis in newborn infants. *J Paediatr Child Health* 1999;35(5):460–5.

2. Green C, Yohannan MD. Umbilical arterial and venous catheters: Placement, use, and complications. *Neonatal Netw* 1998;17(6):23–8.
3. Davies M. Pathology of arterial thrombosis. *Br Med Bull* 1994;50(4):789–802.
4. Esmon CT. Basic mechanisms and pathogenesis of venous thrombosis. *Blood Rev* 2009;23(5):225–9.
5. Nagel K, Tuckuviene R, Paes B, Chan AK. Neonatal aortic thrombosis: A comprehensive review. *Klin Padiatr* 2010;222(3):134–9.
6. López JA, Chen J. Pathophysiology of venous thrombosis. *Thromb Res* 2009;123 Suppl 4:S30–4.
7. Vailas GN, Brouillette RT, Scott JP, Shkolnik A, Conway J, Wiringa K. Neonatal aortic thrombosis: Recent experience. *J Pediatr* 1986;109(1):101–8.
8. Long A. Exploration ultrasonore des artères. In: Joffre F, editor. *Traité D'imagerie Vasculaire*. Paris: Elsevier Massan; 2015. p. 2–27.
9. Deeg KH, Wölfel D, Rupprecht T. Diagnosis of neonatal aortic thrombosis by colour coded Doppler sonography. *Pediatr Radiol* 1992;22(1):62–3.
10. Laissy JP, Travers Jy, Goupil J, Idir I, Storey J. Exploration tomодensitométrique des vaisseaux. In: Joffre F, editor. *Traité D'imagerie Vasculaire*: Elsevier Massan; 2015. p. 34–42.
11. Schmidt B, Andrew M. Neonatal thrombosis: Report of a prospective Canadian and international registry. *Pediatrics*. 1995;96(5 Pt 1):939–43.
12. Monagle P, Chan A, Massicotte P, Chalmers E, Michelson AD. Antithrombotic therapy in children: The seventh ACCP conference on antithrombotic and thrombolytic therapy. *Chest* 2004;126(3 Suppl):645S–87.
13. Cambouliques J, Paut O. Traitement des thromboses chez l'enfant: Médicaments antithrombotiques et fibrinolytiques. *Réanimation* 2001;10(5):487–94.

\*\*\*\*\*

## Author Contributions

El Bakkari Asaad – Conception of the work, Design of the work, Acquisition of data, Analysis of data, Interpretation of data, Drafting the work, Revising the work critically for important intellectual content, Final approval of the version to be published, Agree to be accountable for all aspects of the work in ensuring that questions related to the accuracy or integrity of any part of the work are appropriately investigated and resolved

Othman Ayouché – Conception of the work, Design of the work, Acquisition of data, Analysis of data, Interpretation of data, Drafting the work, Revising the work critically for important intellectual content, Final approval of the version to be published, Agree to be accountable for all aspects of the work in ensuring that questions related to the accuracy or integrity of any part of the work are appropriately investigated and resolved

Smiti Yassine – Conception of the work, Design of the work, Acquisition of data, Analysis of data, Interpretation of data, Drafting the work, Revising the work critically for important intellectual content, Final approval of the version to be published, Agree to be accountable for all

aspects of the work in ensuring that questions related to the accuracy or integrity of any part of the work are appropriately investigated and resolved

Dahbi Youssef – Conception of the work, Design of the work, Acquisition of data, Analysis of data, Interpretation of data, Drafting the work, Revising the work critically for important intellectual content, Final approval of the version to be published, Agree to be accountable for all aspects of the work in ensuring that questions related to the accuracy or integrity of any part of the work are appropriately investigated and resolved

Salmi Najlaa – Conception of the work, Design of the work, Acquisition of data, Analysis of data, Interpretation of data, Drafting the work, Revising the work critically for important intellectual content, Final approval of the version to be published, Agree to be accountable for all aspects of the work in ensuring that questions related to the accuracy or integrity of any part of the work are appropriately investigated and resolved

Nazik Allali – Conception of the work, Design of the work, Acquisition of data, Analysis of data, Interpretation of data, Drafting the work, Revising the work critically for important intellectual content, Final approval of the version to be published, Agree to be accountable for all aspects of the work in ensuring that questions related to the accuracy or integrity of any part of the work are appropriately investigated and resolved

Latifa Chat – Conception of the work, Design of the work, Acquisition of data, Analysis of data, Interpretation of data, Drafting the work, Revising the work critically for important intellectual content, Final approval of the version to be published, Agree to be accountable for all

aspects of the work in ensuring that questions related to the accuracy or integrity of any part of the work are appropriately investigated and resolved

### **Guarantor of Submission**

The corresponding author is the guarantor of submission.

### **Source of Support**

None.

### **Consent Statement**

Written informed consent was obtained from the patient for publication of this article.

### **Conflict of Interest**

Authors declare no conflict of interest.

### **Data Availability**

All relevant data are within the paper and its Supporting Information files.

### **Copyright**

© 2019 El Bakkari Asaad et al. This article is distributed under the terms of Creative Commons Attribution License which permits unrestricted use, distribution and reproduction in any medium provided the original author(s) and original publisher are properly credited. Please see the copyright policy on the journal website for more information.

Access full text article on  
other devices



Access PDF of article on  
other devices





**Submit your manuscripts at**  
[www.edoriumjournals.com](http://www.edoriumjournals.com)

