

Apparent appendicitis in Amyand hernia with unexpected pathology

David A Russler-Germain, Tyler J Fraum,
Marcus P Watkins, Nancy L Bartlett

CASE REPORT

A 70-year-old man with a history of peripheral T-cell lymphoma in complete remission since 2012, presented with a three-week history of a tender 'knot' in his right inguinal/suprapubic region. He denied fevers, nausea, vomiting, and constipation. Physical examination was remarkable only for a 4x5 cm firm mass in the right suprapubic region. Complete blood counts and a comprehensive metabolic panel were normal except for a chronically elevated creatinine (1.9 mg/dL) and mildly elevated lactate dehydrogenase (279 units/L). Transaxial (Figure 1A) and coronal (Figure 1B) computed tomography (CT) images, obtained without intravenous contrast, revealed marked appendiceal thickening (arrows) and periappendiceal fat-stranding (arrowheads), suspicious for acute appendicitis. As shown in Figure 1B, the appendix was located within an indirect inguinal hernia sac (bracket), an entity known as an Amyand hernia. There was no evidence of appendiceal perforation. One day later, the patient underwent a laparoscopic appendectomy and open primary right inguinal hernia repair with a post-operative diagnosis of "acute, perforated appendicitis incarcerated within an indirect right inguinal hernia." In addition to acute-

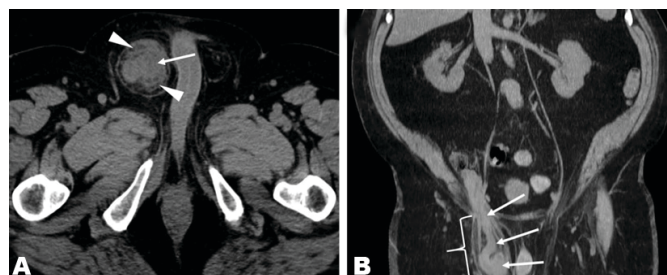


Figure 1: Computed tomography (CT) images obtained without intravenous contrast; (A) transaxial image, (B) coronal image, appendiceal thickening (arrows) and periappendiceal fat-stranding (arrowheads), suspicious for acute appendicitis, the appendix was located within an indirect inguinal hernia sac (bracket), an entity known as an Amyand hernia.

on-chronic inflammation in the hernia sac, pathology revealed diffuse large B-cell lymphoma of the appendix. Subsequent staging by fluorodeoxyglucose (FDG)-PET/CT revealed multiple FDG-avid liver lesions consistent with stage IV lymphoma. The patient subsequently achieved a complete response with R-CHOP chemotherapy.

DISCUSSION

Amyand hernia was first described by the surgeon Claudius Amyand in 1735. It refers to the protrusion of a vermiform appendix in an inguinal hernia sac and occurs in <1% of all inguinal hernias. Appendicitis in an Amyand hernia accounts for <0.1% of all cases of appendicitis [1–3]. Amyand hernias occur more frequently in male patients, and have a bimodal age distribution with peak incidences in neonates and in patients over 70 years of age [4–6]. Reports of Amyand hernia predominantly describe preoperative diagnoses made by ultrasound or CT, otherwise diagnosis of Amyand hernias tend to occur intraoperatively [7–9]. While almost always an indirect hernia, the phenomenon of a direct Amyand hernia has been also described [10]. A four-category classification system has been proposed by Losanoff and Basson to guide staging and management of Amyand hernias [11]. It bases surgical recommendations on the presence or absence of a normal appendix (Stage 1), localized

David A Russler-Germain¹, Tyler J Fraum², Marcus P Watkins³,
Nancy L Bartlett⁴

Affiliations: ¹Resident, Department of Internal Medicine, Washington University School of Medicine, Saint Louis, MO, USA; ²Resident, Department of Radiology, Washington University School of Medicine, Barnes-Jewish Hospital, Saint Louis, MO, USA; ³Scientific Writer, Department of Medical Oncology, Washington University School of Medicine, Saint Louis, MO, USA; ⁴Professor, Department of Medical Oncology, Washington University School of Medicine, Saint Louis, MO, USA.

Corresponding Author: Nancy L Bartlett, Washington University School of Medicine, 660 South Euclid, Box 8056, Saint Louis, MO 63110, USA; Email: nbartlet@wustl.edu

Received: 16 March 2019

Accepted: 24 April 2019

Published: 11 June 2019

acute appendicitis (Stage 2), peritonitis (Stage 3), or other abdominal pathology (Stage 4). Stage 4 Amyand hernia is a small subgroup of an already rare condition, typically encompassing cases with abscess formation, or alternatively with coexistence of a malignancy, typically a primary appendiceal tumor [12, 13]. The patient described in our case report fits this category with his unexpected diagnosis of diffuse large B-cell lymphoma (DLBCL) of the appendix. The most common site of extranodal involvement of non-Hodgkin lymphoma (NHL) is the gastrointestinal (GI) tract, representing 10–15% of all NHL cases, and ~1/3 of all NHL with any extranodal involvement [14]. Involvement of the appendix is rare, as the most commonly involved sites in the GI tract are the stomach, small intestine, pharynx, colon, and esophagus [14, 15].

CONCLUSION

Computed tomography (CT) findings of acute appendicitis are nonspecific and that differential diagnoses should be considered when there is an atypical clinical presentation. In this case, the subacute presentation over three weeks and the absence of fever, leukocytosis, or gastrointestinal symptoms were unusual for acute appendicitis.

Keywords: Amyand hernia, Appendicitis, Lymphoma

How to cite this article

Russler-Germain DA, Fraum TJ, Watkins MP, Bartlett NL. Apparent appendicitis in Amyand hernia with unexpected pathology. *Int J Case Rep Images* 2019;10:101030Z01DG2019.

Article ID: 101030Z01DG2019

doi: 10.5348/101030Z01DG2019CL

REFERENCES

1. Ryan WJ. Hernia of the vermiform appendix. *Ann Surg* 1937;106:135–9.
2. Thomas WE, Vowles KD, Williamson RC. Appendicitis in external herniae. *Ann R Coll Surg Engl* 1982;64(2):121–2.
3. Michalinos A, Moris D, Vernadakis S. Amyand's hernia: A review. *Am J Surg* 2014;207(6):989–95.

4. Cankorkmaz L, Ozer H, Guney C, Atalar MH, Arslan MS, Koyluoglu G. Amyand's hernia in the children: A single center experience. *Surgery* 2010;147(1):140–3.
5. Meinke AK. Review article: Appendicitis in groin hernias. *J Gastrointest Surg* 2007;11(10):1368–72.
6. Srouji MN, Buck BE. Neonatal appendicitis: Ischemic infarction in incarcerated inguinal hernia. *J Pediatr Surg* 1978;13(2):177–9.
7. Akfirat M, Kazez A, Serhatlioglu S. Preoperative sonographic diagnosis of sliding appendiceal inguinal hernia. *J Clin Ultrasound* 1999;27(1):156–8.
8. Luchs JS, Halpern D, Katz DS. Amyand's hernia: Prospective CT diagnosis. *J Comput Assist Tomogr* 2000;24(6):884–6.
9. Kueper MA, Kirschniak A, Ladurner R, Grandrath FA, Konigsrainer A. Incarcerated recurrent inguinal hernia with covered and perforated appendicitis and periappendicular abscess: Case report and review of the literature. *Hernia* 2007;11(2):189–91.
10. D'Alia C, Lo Schiavo MG, Tonante A, et al. Amyand's hernia: Case report and review of the literature. *Hernia* 2003;7(2):89–91.
11. Losanoff JE, Basson MD. Amyand hernia: A classification to improve management. *Hernia* 2008;12(3):325–6.
12. Wu C, Yu C. Amyand's hernia with adenocarcinoid tumor. *Hernia* 2010;14(4):423–5.
13. Lee YT, Wu HS, Hung MC, Lin ST, Hwang YS, Huang MH. Ruptured appendiceal cystadenoma presenting as right inguinal hernia in a patient with left colon cancer: A case report and review of literature. *BMC Gastroenterol* 2006;6:32.
14. Paryani S, Hoppe RT, Burke JS, et al. Extralymphatic involvement in diffuse non-Hodgkin's lymphoma. *J Clin Oncol* 1983;1(11):682–8.
15. Caristo G, Griseri G, Fornaro R, et al. Primary lymphoma of appendix presenting as acute appendicitis: A case report. *Int J Surg Case Rep* 2018;48:30–30.

Author Contributions

David A Russler-Germain – Conception and design, Acquisition of data, Analysis and interpretation of data, Drafting the article, Critical revision of the article, Final approval of the version to be published, Agree to be accountable for all aspects of the work in ensuring that questions related to the accuracy or integrity of any part of the work are appropriately investigated and resolved

Tyler J Fraum – Acquisition of data, Analysis and interpretation of data, Drafting the article, Critical revision of the article, Final approval of the version to be published, Agree to be accountable for all aspects of the work in ensuring that questions related to the accuracy or integrity of any part of the work are appropriately investigated and resolved

Marcus P Watkins – Conception and design, Drafting the article, Critical revision of the article, Final approval of the version to be published, Agree to be accountable for

all aspects of the work in ensuring that questions related to the accuracy or integrity of any part of the work are appropriately investigated and resolved

Nancy L Bartlett – Conception and design, Acquisition of data, Analysis and interpretation of data, Drafting the article, Critical revision of the article, Final approval of the version to be published, Agree to be accountable for all aspects of the work in ensuring that questions related to the accuracy or integrity of any part of the work are appropriately investigated and resolved

Guarantor of Submission

The corresponding author is the guarantor of submission.

Source of Support

None.

Consent Statement

Written informed consent was obtained from the patient

for publication of this article.

Conflict of Interest

Authors declare no conflict of interest.

Data Availability

All relevant data are within the paper and its Supporting Information files.

Copyright

© 2019 David A Russler-Germain et al. This article is distributed under the terms of Creative Commons Attribution License which permits unrestricted use, distribution and reproduction in any medium provided the original author(s) and original publisher are properly credited. Please see the copyright policy on the journal website for more information.

Access full text article on
other devices



Access PDF of article on
other devices





Submit your manuscripts at
www.edoriumjournals.com

