

CT-scan imaging of a puerperalis woman with cerebral infarction due to straight sinus thrombosis mimicking cerebral abscess in bilateral thalamus

Muhammad Yunus Amran, Lisa Tenriesa Muslich

CASE REPORT

A 24-year-old woman was admitted to the emergency room (ER) with loss of consciousness accompanied by restlessness and voiceless from two days prior to admission. History of nausea, five times vomiting and weakness prior to loss of consciousness was obtained from patient's family (husband and mother). Patient also had a history of fever three days before the admission which subsided after consuming acetaminophen and vitamins and occurred all over again not long after. Patient was in the period of postpartum day 37th, normal delivery with perineal stitches, assisted by a midwife in Community Health Sub-center. There was no long history of cough, trauma, or history of fever from second to tenth day after delivery. The patient looked pale shortly after delivery, and complained of pain in the back of her head. General examination showed blood pressure 140/90 mmHg, regular and strong heart rate with 92 beats per minute, 20 times per minute thoraco-abdominal type of breathing, and 37.1°C temperature. No pallor, jaundice

nor cyanosis was observed. The neurological examination included Glassgow Coma Scale (GCS) score that was 7/15 (E2M4V1). The cortical function was difficult to assess. The meningeal signs that included nuchal rigidity and Kernig's sign were both positive; cranial nerves were within normal limits; abdominal wall reflexes, sensory function, as well as autonomic function such as urination and defecation were within normal limits. The movement and strength in motoric functions were difficult to assess and showed no lateralization. The muscle tone and physiological reflexes were increased and pathological reflexes were positive in all extremities. Laboratory examination showed an increased number of white blood cells ($16.6 \times 10^3/\text{mm}^3$) while other results of laboratory tests such as complete blood count, random blood glucose, urea, creatinin, liver functions, and blood electrolytes were within normal limits. Head CT scan (Figure 1) showed a hyperdense lesion filling the posterior interhemispheric fissure, basal ganglia and right thalamic region which was suggestive of encephalitis with subarachnoid hemorrhage on the posterior interhemispheric fissure. The results of cerebral CT arteriography and venography showed a hypodense lesion (33.93 HU) on bilateral thalamus particularly in the right side with minimal enhancement ring after injection of contrast. Moreover, there was also linear posterior interhemispheric hyperdense lesion in accordance with rectus sinus. Filling defects of the rectus

Muhammad Yunus Amran¹, Lisa Tenriesa Muslich²

Affiliations: ¹Clinical Associate Professor and Lecturer, Department of Neurology, Medical Faculty of Hasanuddin University, Dr. Wahidin Sudirohusodo General Hospital, and Hasanuddin University Teaching Hospital, Jl. PerintisKemerdekaan KM 11, Makassar, South Sulawesi, Indonesia; ²Clinical Assistant Professor and Lecturer, Clinical Microbiology Department, Medical Faculty of Hasanuddin University, Hasanuddin University Teaching Hospital, Makassar, South Sulawesi, Indonesia.

Corresponding Author: Muhammad Yunus Amran, M.D., Ph.D., FIPM, Neurologist, Lecturer and Clinical Assistant Professor, Department of Neurology, Medical Faculty of Hasanuddin University, Dr. Wahidin Sudirohusodo General Hospital, and Hasanuddin University Teaching Hospital, Jl. PerintisKemerdekaan KM 11, Makassar, 90245, Indonesia; Email: yunusamran10@gmail.com

Received: 24 February 2019

Accepted: 22 March 2019

Published: 25 April 2019

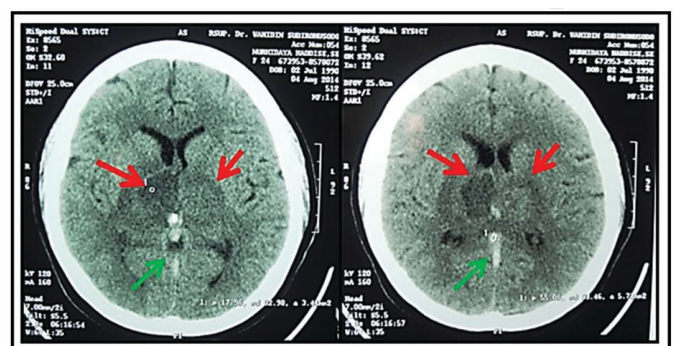


Figure 1: Head CT Scan with contrast. Red arrows indicate hypodense lesion in the right bilateral thalamus area and green arrows show the hyperdense lesion due to the contrast of the interhemispheric fissure, with a thrombus in the sinus rectus.

and left transverse sinus were seen up to left internal jugular vein. These results (Figure 2A, B, C and D) were suggestive of thrombosis of rectus and left transverse upto until the left and right internal jugular vein. The bilateral thalamus abscess was observed on the right side. Patient was admitted to the neurology ward for three weeks for treatment and was given therapy in accordance with standard procedure of cerebral abscess which consisted of broad spectrum antibiotic in a form of penicillin, third generation of cephalosporin and metronidazole. The patient was also given acetylsalicylic acid, fondaparinux sodium and warfarin for the CVST. Other investigations were carried out and showed anti-rubella IgG 124; anti-rubella IgM 0.14; anti-CMV IgG 67, anti CMV IgM 0.19 and blood cultures for aerobic and anaerobic bacteria. All the results were found to be negative. Before the patient was discharged, radiological head CT scan was performed to control the progressivity of the lesion, and the results showed a visible diminished hypodense lesion (14-29HU). In post contrast administration, a thick-walled lesion and contrast enhancement appeared (40.44 HU) without calcification in the right thalamus region (Figure 3A and B). This was suggested as a cerebral abscess in the right thalamus region. Three weeks after discharge from

the hospital, the patient came to neurology outpatient clinic. Another laboratory examination was performed. The results were: erythrocyte $5.3 \times 10^6/\text{mm}^3$ (Normal); hemoglobin (HGB) 11.4 g/dl; hematocrite (HCT) 35.6% (slightly improved); MCV $67 \mu\text{m}^3$; MCH 21.5 pg; MCHC 32.1 g/dl; RDW 29.4%; WBC $11.1 \times 10^3/\text{mm}^3$ (slightly improved); neutrophils 70.2%; monocyte 11%; and PLT $436 \times 10^6/\text{mm}^3$ (increased) which was considered to be a sign of thrombocytosis. Prothrombin time (PT) 14.0 sec; normo Index Ratio (INR) 1.15; activated partial thromboplastin time (activated partial thromboplastin time/APTT) 27.5 sec; blood glucose 116 mg/dL; Urea 16 mg/dL; Creatinine 0.60 U/L; AST 40 U/L and SGPT 34 U/L. Radiological investigation of head CT scan showed multiple hypodense lesions (19HU), with firm boundaries. There was no occurrence of perifocal edema in the area of thalamus. There was no enhancement of contrast injection (22.75 HU). In the internal capsule of right basal ganglia and thalamus, as shown in Figure 4A and B, a hypodense lesion was present suggestive of an infarction. The patient's condition till the last CT-scan performed was good despite reduced agile attitude.

DISCUSSION

Cerebral Venous Sinus Thrombosis (CVST) resulting from post-partum process is seldom encountered and is a cerebrovascular disease caused by the presence of a thrombus (blood clot) in the veins of the brain/dural. CVST is very rare compared to other types of

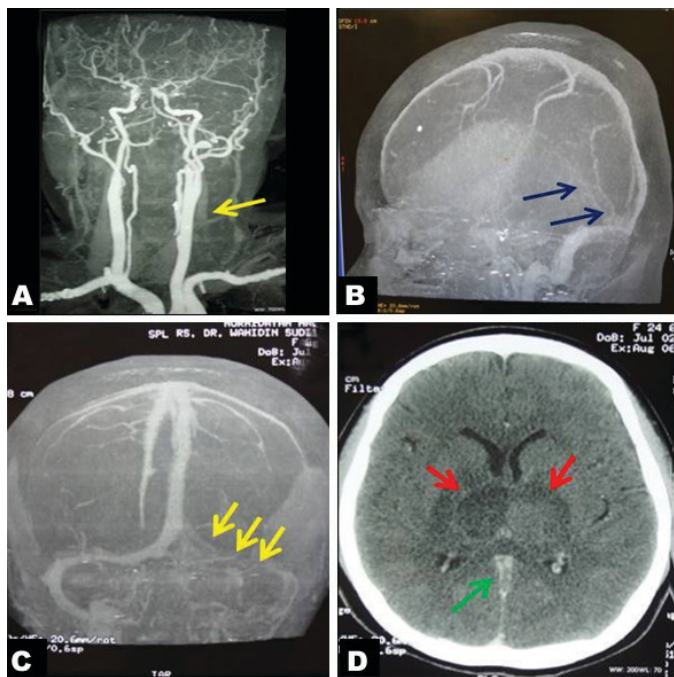


Figure 2: CT cerebral arteriography, venography and Head CT Scan with contrast. (A) The yellow arrow indicates the filling defect in the left internal jugular vein. (B) Filling defects in the sinus rectus (blue arrow). (C) Filling defect in the left transverse sinus indicated by the yellow arrow. (D) The red arrow on the head CT scan with contrast showed hypodense lesions with contrast enhancement suggested a cerebral abscess which is actually an infarct area or edema due to rectus sinus thrombosis. This one is indicated by a green arrow which is a typical sign of empty delta sign with their hypodense thrombus in the middle.

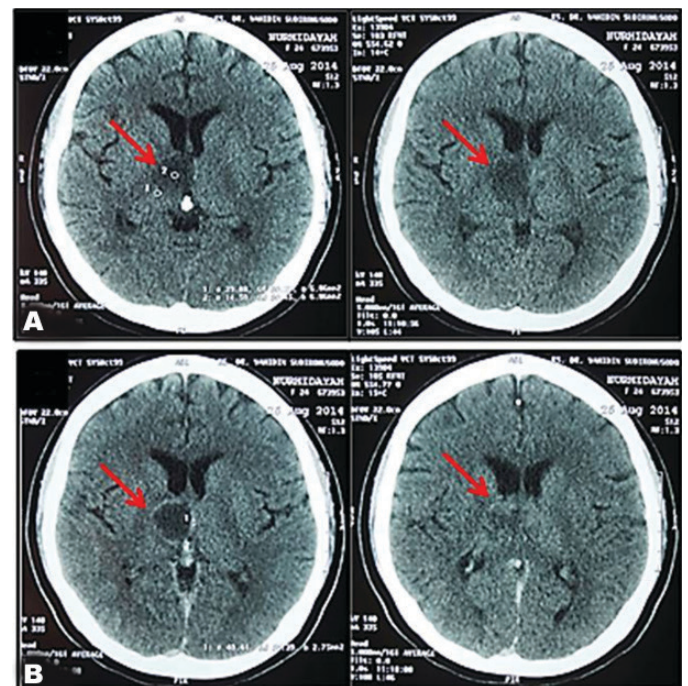


Figure 3(A and B): Head CT scan without contrast (A) and with contrast (B). (A) Hypodense lesions appear in the thalamus region primarily on the right. (B) Hypodense lesion with contrast enhancement indicating a cerebral abscess.

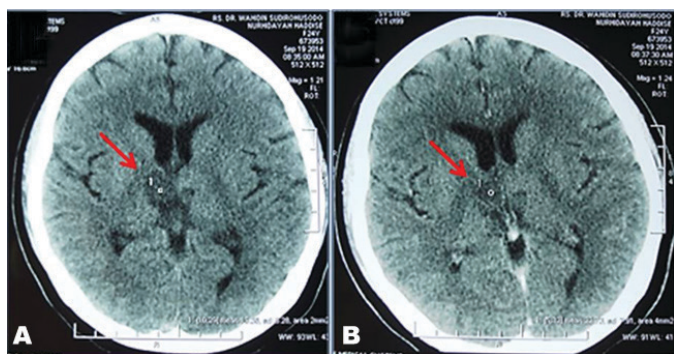


Figure 4: Non-contrast head CT scan (A) and contrast (B). A. Isodense lesion in the thalamus region, B. Hypodense lesion in the thalamus region without contrast enhancement showing an infarct lesion.

strokes, and has very different clinical symptoms and various etiological causes. About 0.5–1% of the stroke are caused by this CVST. Clinical symptoms caused by this disease vary greatly hence clinical experience is necessary in establishing the diagnosis [1, 2, 3]. CVST is estimated to occur in 3–4 per 1 million population per year, and about 3–8% of patients with CVST are caused by thrombosis of deep cerebral vein or the deep cerebral veins at the basal vein (vein of Rosenthal), the internal cerebral vein (internal vein) and cerebral vena magna (the great vein of Galen) [1, 4]. In the United States, the incidence of CVST reported to be around 11.6 per 100,000 post-partum women. The center of Canada registers that CVST incident is more common in children particularly neonatal age than adults. In adults, CVST occur at a younger age. The average age reported by the International Study on Cerebral Vein and Dural Sinus Thrombosis (ISCVT) in the cohort study was 37 years of age with only about 8% reported to be over 65 years of age. CVST is more common in women than men with a ratio worth of 2.9: 1 [2].

Brain venous drainage system occurs through a complex system rather than the superficial and deep veins. These veins have no valves but a thin wall in the absence of muscle tissue. It penetrates the arachnoid layer and the inner layer of dura to drain into the dural venous sinuses. Sinus venous is a channel formed by meningeal layer and endothelium duramater layer coated by endothel as a continuation of the cavity shaped vein endothelium. The functions of these venous sinuses are to accommodate the blood of meningeal, diploic and encephalon veins which then flow into the internal jugular vein [5].

CVST is more common in certain conditions, where around 85% of patients have been reported to have at least one of these risk factors: thrombophilia; prothrombotic conditions; deficiency of antithrombotic III, protein C and S; antiphospholipid syndrome and anticardiolipin antibodies; factor V Leiden, which cause resistance of C protein activation; mutation of prothrombin G 20210; hyperhomocystinuria; birth control pills usage; pregnancy and postnatal (purpura) that cause prothrombotic

instantaneous (as much as 2% of pregnancy-related stroke and frequency CVST on puerperium, (12 cases per 100,000 births); nephrotic syndrome; polycythemia vera and paroxysmal nocturnal hemoglobinuria; a direct injury to the sinuses and veins of the brain; severe dehydration; liver and heart disorders; and meningitis as well as ear infections. The state of infection that usually causes CVST is pneumococcal bacteria, but fungal, parasitic infections and TB meningitis can also cause CVST [1, 6]. The mechanism is very different from CVST arterial infarction, where it is highly related to Virchow's triad that includes the static flow of blood, injury to the blood vessel walls and changes in blood composition in the form of hypercoagulability. There are two mechanisms in CVST by which the thrombosis occurs including local edema and venous infarction. Edema is generally caused by vasogenic edema and could also be due to cytotoxic edema. Cytotoxic edema caused by an increase in intravenous pressure generating venous congestion, increased intravascular pressure, and decreased cerebral perfusion pressure. All of these reduction conditions may lead to cerebral blood flow below the level of blood flow within the penumbra region or infarct area, which then ultimately leads to the failure of energy, loss of pumping activity of Na⁺, K⁺-ATPase and the inclusion of intracellular water, resulting in cytotoxic edema. This also results in intracranial hypertension which causes an increase in venous pressure, decreased absorption of CSF and an increase in intra-cranial pressure [2].

Clinical symptoms of cerebral venous sinus thrombosis can vary and the onset may be acute, subacute or chronic. There are four major syndromes: isolated intracranial hypertension, abnormal neurological focal, seizures and encephalopathy. These syndromes can arise simultaneously or just one depending on regional expansion of the CVST. Intracranial hypertension is most often arising as a headache from CVST, about state > 90%, and 64% has been reported on the subacute. Symptoms of headache caused by CVST in some patients can resemble headache as on subarachnoid hemorrhage. Headache can be localized or generalized and can be exacerbated by Valsalva maneuver action or change in position. Other symptoms are papillary edema and visual disturbances. The headache caused by CVST in initial diagnosis resembles migraine. Focal neurological deficits were approximately 44% of patients with CVST.

Motoric weakness including hemiparesis is most common focal neurological deficit that appears in more than 40% of patients. Fluent aphasia may come from the left transverse sinus thrombosis. Sensory deficits are very rare. Focal or generalized seizures include status epilepticus observed in which has been 30–40% of patients with primary CVST of the sagittal sinus and cortical veins thrombosis. Encephalopathy can be caused by sinus thrombosis in the rectus and its branches or due to CVST with widespread symptoms, causing cerebral edema, wide venous infarction, or parenchymal hemorrhage that causes herniation. In elderly patients,

bias can be accompanied by a change in mental status compared to younger patients [7–11].

CVST therapy can be initiated if the diagnosis and the risk factors have been identified and corrected. Thus, CVST therapeutic management will be more easy to perform to improve the patient's prognosis. Anticoagulants, heparin, at a dose of 2500-5000 units subcutaneously can be administered for 3-4 days followed with the oral anticoagulant warfarin for six months after sinus venous thrombosis or even for longer period, if the condition persists. Thrombolytic therapy might be considered for removing blockages, and if necessary, it could be combined with mechanical thrombi-aspiration in patients whose condition has worsened after administration of adequate conservative therapy as recommended by European Federation of Neurological Societies [1, 12, 13].

In this reported case, it was quite difficult to determine the source of the infection. Based on literature, child bed infection can be presumed from the history of second to tenth day of postpartum fever. Meanwhile, this case has no history of fever after parturition. However, the place of mother's labor, community health sub-center with unguaranteed for sterility of the delivery place and equipment. Thus, it can be considered as the source of infection during perineal laceration wound stitching.

Vaginal delivery followed by episiotomy increases the occurrence of thromboembolism with two consisting risk factors [14]:

- A. The period of pregnancy which increases the tendency of thromboembolism include: cesarean, vaginal delivery with additional procedures, maternal age at high risk during pregnancy and childbirth, lactation suppression using estrogen preparations, sickle cell disease, a history of previous thrombophlebitis, heart disease, immobilization time, obesity and maternal infection and chronic venous insufficiency.
- B. Postpartum period includes smoking, pre-eclampsia, prolonged labor, anemia and bleeding.

Based on this, we initially concluded that at the time of delivery the mother is likely to experience a silent ascenders infection showing no symptoms of post-delivery infections. This may be due to perineal suturing procedure resulting a micro thromboembolism. A history of long labor and a post-partum headache was also confirmed [15, 16].

Pregnant mothers have high risk factor for cerebral venous thrombosis because of three interrelated factors along with physiological changes in pregnancy [17] such as:

1. Coagulation changes during pregnancy
In pregnancy, hypercoagulable blood occurs due to the changes in the levels of clotting factors.
2. Static vein
During pregnancy, static venous blood flow is possible to occur. This is due to a decline in the gradual flow of venous blood from the legs to the thigh, significant obstruction from the vena

cava due to compression of the enlarged uterus especially from the phase of mid-pregnancy, the low veins tone in the lower limbs at the beginning of pregnancy, dilated pelvic veins and possible dysfunction of venous valve leaflets.

3. Vascular endothelium trauma
Endothelial vascular thrombosis is a physiological barrier that produces prostacyclin which serves to prevent the occurrence of platelet aggregation and activation. In pregnancy, there can be damaging changes in the elastic fibers of the tunica media and intima due to high levels of estrogen.
4. Damage to the vascular endothelium
Diagnosis of cerebral abscess in this case was bit difficult; not only because of its imaging overview but also due to need of biopsy for confirmation of the diagnosis. The results of blood cultures showed negative results due to delay in conducting the examination. But the results of leukocytosis may indicate a bacterial infection. On radiological examination, it was difficult to determine whether the lesion found in the bilateral thalamus was an abscess or an infarction. Lesions of the thalamus region are numerous, so that radiological examinations need to be synchronized with the physical examination and clinical symptoms experienced by the patient. The clinical symptoms experienced by the patient may be present in those who could develop an abscess or CVST. In early radiological examination, abscesses and CVST were also found. Also, a contrast enhancement in radiological examination of CT scan of head could exist both, in abscess case or cerebral infarction case. Interestingly, the location of an abscess in the thalamus region usually occurred in the immunocompromised patient. This is a very rare case. Air fluid level during convalescence is mostly found in the CT scan. Yet, it was not visible in this case. On radiological examination, head CT scan after treatment showed a hypodense lesion that lead to a cerebral infarction due to thrombosis of the sinus rectus characterized by the defects filling from sinus rectus, to the left sinus transversus, sinus sigmoid and internal jugular vein. Therefore, we believe that this is a rare case of an infarct due to thrombosis in the deep cerebral veins and sinus rectus.

CONCLUSION

CVST resulting from postpartum process is seldom encountered and CVST is a cerebrovascular disease which has a wide variety of clinical manifestations. This should be supported by history taking, clinical symptoms and radiological examination and other laboratory

investigations. Illustration of this case showed that the initial radiological diagnosis done before treatment showing bilateral thalamic abscess, yet the subsequent CT-Head result done after treatment turned out to be a cerebral infarction. Therefore, both clinical and radiological findings are important and need to be synchronized before reaching the final diagnosis.

Keywords: Cerebral Infraction, Cerebral venous sinus thrombosis, Cerebral abscess, Head CT-Scan

How to cite this article

Amran MY, Muslich LT. CT-scan imaging of a puerperalis woman with cerebral infarction due to straight sinus thrombosis mimicking cerebral abscess in bilateral thalamus. Int J Case Rep Images 2019;10:101021Z01MA2019.

Article ID: 101021Z01MA2019

doi: 10.5348/101021Z01MA2019CL

REFERENCES

1. Stam J. Thrombosis of the cerebral veins and sinuses. N Engl J Med 2005;352(17):1791–8.
2. Mohr JP, Wolf PA, Grotta JC, Moskowitz MA, Mayberg M, Kummer RV. Section 3, Cerebral Venous Thrombosis in Book of Pathophysiology, Diagnosis, and Management. 5ed. Chapter 28. United States: Elsevier Saunders; 2011. p. 516–30.
3. Weimar C, Masuhr F, Hajjar K. Diagnosis and treatment of cerebral venous thrombosis. Expert Rev Cardiovasc Ther 2012;10(12):1545–53.
4. van den Bergh WM, van der Schaaf I, van Gijin J. The spectrum of presentations of venous infarction caused by deep cerebral vein thrombosis. Neurology 2005;65(2):192–6.
5. Netter FH. Arteries to brain and meninges. In: Netter FH, editor. Atlas of Human Anatomy. 3ed. USA: Saunders; 2004. p. 130–6.
6. Atanassova PA, Massaldjieva RI, Chalakova NT, Dimitrov BD. Cerebral Venous Sinus thrombosis - Diagnostic strategies and prognostic models: A review. In: Okuyan E, editor. Venous Thrombosis – Principles and Practice. London, UK: InTech; 2012.
7. Ferro JM, Canhão P, Stam J, Bousser MG, Barinagarrementeria F; ISCVT Investigators. Prognosis of cerebral vein and dural sinus thrombosis: Results of the International Study on Cerebral Vein and Dural Sinus Thrombosis (ISCVT). Stroke 2004;35(3):664–70.

8. Tanislav C, Siekmann R, Sieweke N, et al. Cerebral vein thrombosis: Clinical manifestation and diagnosis. BMC Neurol 2011;11:69.
9. Agostoni E. Headache in cerebral venous thrombosis. Neurol Sci 2004;25 Suppl 3:S206–10.
10. Ferro JM, Canhão P, Bousser MG, Stam J, Barinagarrementeria F; ISCVT Investigators. Early seizures in cerebral vein and dural sinus thrombosis: Risk factors and role of antiepileptics. Stroke 2008;39(4):1152–8.
11. Ferro JM, Canhão P, Bousser MG, Stam J, Barinagarrementeria F; ISCVT Investigators. Cerebral vein and dural sinus thrombosis in elderly patients. Stroke 2005;36(9):1927–32.
12. Einhäupl K, Bousser MG, de Bruijn SF, et al. EFNS guideline on the treatment of cerebral venous and sinus thrombosis. Eur J Neurol 2006;13(6):553–9.
13. Sasidharan PK. Cerebral vein thrombosis misdiagnosis and mismanaged. Trombosis 2012;2012:1–11.
14. Biswas MK, Perloff DP. Cardiac, hemotologic, pulmonary, renal and urinary tract disorders in pregnancy. In: DeCherney AH, Pernoll ML, editors. Current Obstetric & Gynecologic Diagnosis & Treatment. Norwalk, Connecticut: Appleton & Lange; 1994. p. 428–67.
15. James AH. Venous thromboembolism in pregnancy. Arterioscler Thromb Vasc Biol 2009;29(3):326–31.
16. Lowdermilk DL. Chapter 25. Postpartum complications. In: Lowdermilk DL, Perry SE, Cashion MC, editors. Evolve Resources for Maternity Nursing. 8ed. USA: Mosby; 2011. p. 831–32.
17. Khaelani BA, Mapari UU, Sikandar R. Obstetric cerebral venous thrombosis. J Pak Med Assoc 2006;56(11):490–93.

Author Contributions

Muhammad Yunus Amran – Conception of the work, Design of the work, Acquisition of data, Analysis of data, Interpretation of data, Drafting the work, Revising the work critically for important intellectual content, Final approval of the version to be published, Agree to be accountable for all aspects of the work in ensuring that questions related to the accuracy or integrity of any part of the work are appropriately investigated and resolved

Lisa Tenriesa Muslich – Conception of the work, Design of the work, Acquisition of data, Analysis of data, Interpretation of data, Drafting the work, Revising the work critically for important intellectual content, Final approval of the version to be published, Agree to be accountable for all aspects of the work in ensuring that questions related to the accuracy or integrity of any part of the work are appropriately investigated and resolved

Guarantor of Submission

The corresponding author is the guarantor of submission.

Source of Support

None.

Consent Statement

Written informed consent was obtained from the patient for publication of this article.

Conflict of Interest

Authors declare no conflict of interest.

Data Availability

All relevant data are within the paper and its Supporting Information files.

Copyright


© 2019 Muhammad Yunus Amran et al. This article is distributed under the terms of Creative Commons Attribution License which permits unrestricted use, distribution and reproduction in any medium provided the original author(s) and original publisher are properly credited. Please see the copyright policy on the journal website for more information.

Access full text article on
other devices



Access PDF of article on
other devices





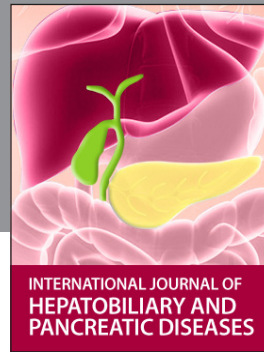INTERNATIONAL JOURNAL OF
CASE REPORTS AND IMAGES



VIDEO JOURNAL OF
CLINICAL RESEARCH



VIDEO JOURNAL OF
BIOMEDICAL SCIENCE




INTERNATIONAL JOURNAL OF
HEPATOBIILIARY AND
PANCREATIC DISEASES



INTERNATIONAL JOURNAL OF
BLOOD TRANSFUSION AND
IMMUNOHEMATOLOGY



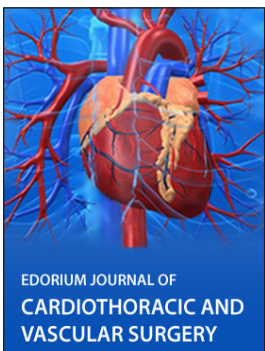EDORIUM JOURNAL OF
OPHTHALMOLOGY



Submit your manuscripts at
www.edoriumjournals.com



EDORIUM JOURNAL OF
MEDICINE



EDORIUM JOURNAL OF
CARDIOTHORACIC AND
VASCULAR SURGERY



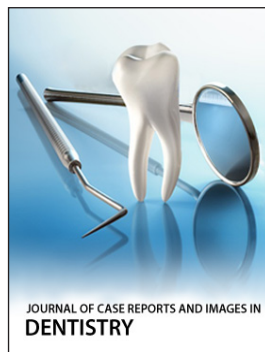
JOURNAL OF CASE REPORTS
AND IMAGES IN ORTHOPEDICS
AND RHEUMATOLOGY



EDORIUM JOURNAL OF
PSYCHOLOGY




EDORIUM JOURNAL OF
CELL BIOLOGY



JOURNAL OF CASE REPORTS AND IMAGES IN
DENTISTRY



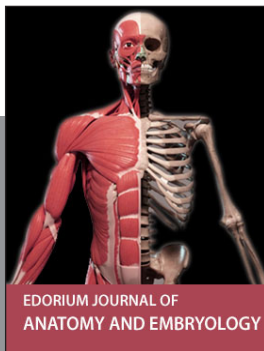EDORIUM JOURNAL OF
CANCER



EDORIUM JOURNAL OF
PSYCHIATRY



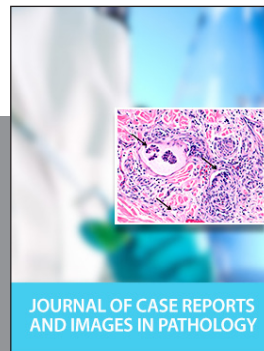JOURNAL OF CASE REPORTS AND
IMAGES IN INFECTIOUS DISEASES




EDORIUM JOURNAL OF
ANATOMY AND EMBRYOLOGY



EDORIUM JOURNAL OF
SURGERY



JOURNAL OF CASE REPORTS
AND IMAGES IN PATHOLOGY



EDORIUM JOURNAL OF
ANESTHESIA