

Managing an inguinoscrotal pseudocyst larger than the pre-operative hernia: Case series on symptomatic giant inguinoscrotal pseudocyst

Joshua Sheng Hao Lim, Ng Weng Leong Victor, Lim Kok Ren

ABSTRACT

Introduction: Seroma formation after inguinal hernia repair is common and most of the seromas will resolve spontaneously without any intervention. If the seroma has not resolved by six weeks, it is not likely to resolve spontaneously. Large symptomatic inguinoscrotal pseudocyst formation after inguinal hernia repair is rare. Hence there is no consensus on how these cases should be managed. **Case Series:** We present two cases of large and symptomatic inguinoscrotal pseudocyst formation after inguinal surgery. Both patients underwent surgical excision of the pseudocyst after failed repeated aspiration. Both patients' pseudocysts were successfully treated with no recurrence upon follow-up. **Conclusion:** Surgical excision remained the definitive treatment for symptomatic inguinoscrotal seroma.

Keywords: Inguinal hernia, Seroma, Pseudocyst

How to cite this article

Lim JSH, Victor NWL, Ren LK. Managing an inguinoscrotal pseudocyst larger than the pre-operative hernia: Case series on symptomatic giant inguinoscrotal pseudocyst. Int J Case Rep Images 2019;10:101009Z01JL2019.

Joshua Sheng Hao Lim¹, Ng Weng Leong Victor², Lim Kok Ren³

Affiliations: ¹Medical Officer, Department of General Surgery, Changi General Hospital, Singapore; ²Consultant, Laboratory Medicine, Changi General Hospital, Singapore; ³Consultant, Department of General Surgery, Changi General Hospital, Singapore.

Corresponding Author: Lim Kok Ren, 2 Simei St 3 Singapore 529889, Singapore; Email: kok_ren_lim@cgh.com.sg

Received: 14 December 2018

Accepted: 16 January 2019

Published: 28 February 2019

Article ID: 101009Z01JL2019

doi: 10.5348/101009Z01JL2019CS

INTRODUCTION

Seroma formation following inguinal hernia repair is not uncommon, incidence commonly quoted in literature is between 1.9–12% [1]. However, the true incidence of seroma is believed to be higher than 12%, as reported by Cihan et al and Fan et al. [2, 3]. Most seroma will resolve spontaneously without requiring any intervention [1, 2]. Clinically palpable seroma may cause discomfort and can cause anxiety for both patient and surgeon, with concern over failure of repair resulting in early recurrence of hernia. Park et al. reported that if seroma in laparoscopic repair of incisional hernia is symptomatic and persists longer than 6 weeks, it should be viewed as a complication [4]. When seroma redevelops after repeated aspiration, it is likely that a pseudocyst has formed and further aspirations will fail. There have only been a handful of case reports on management of pseudocyst, with all patients eventually having surgical excision of the cyst.

CASE SERIES

We present two cases of giant symptomatic pseudocyst formation after inguinal herniorrhaphy, one following laparoscopic total extra-peritoneal (TEP) repair and another after open Lichtenstein repair.

Case 1

An 86-year-old man presented with bilateral reducible indirect inguinal hernias. His right inguinal hernia was small but his left hernia was large and extended into the inguinal-scrotal area upon standing. He underwent a successful laparoscopic repair (TEP approach) of his bilateral inguinal hernia. During

surgery, a large indirect left inguinal hernia and a small right pantaloon inguinal hernia were identified. The whole large left indirect hernia sac was dissected free from the cord structures and the concurrent right direct and indirect hernias were reduced. Meshes were placed and secured with absorbable tackers.

Two weeks post-surgery, he represented to the outpatient clinic with complaints of a large left scrotal swelling and a smaller right groin swelling. There was no recurrence of hernia on ultrasound (US) and computed tomography (CT) scans of the pelvis. However, there was a 13x5x6 cm collection extending from the superomedial aspect of the inguinal region into the left hemi-scrotum and a 7x3x4 cm collection on the right inguinal area (Figure 1). The collections were symptomatic causing the patient pain upon standing and affected his ability to sit comfortably, presumably due to the weight and size of the large seromas. Both collections were aspirated repeatedly but unfortunately, kept recurring. In view of his symptoms, the patient agreed for excision of the seromas.

Case 2

A 57-year-old man presented with a right incarcerated inguinoscrotal hernia. An open Lichtenstein repair was performed and proceeded uneventfully. During surgery, the indirect sac was traced all the way down to the testicular level, dissected free from the cord structures and excised.

At his outpatient four weeks post-operative review, he complained of a hard and large painless mass in his scrotum. CT scan of abdomen and pelvis was performed to exclude early recurrence of the hernia. The CT scan showed diffuse thickening along the right spermatic cord and inguinal canal with a 12x9x10cm collection compressing and displacing the penis and scrotal contents to the contralateral side (Figure 2). The collection was

repeatedly aspirated without improvement. In view of the size of the mass and failure of aspiration, the patient opted for surgical excision.

Surgical treatment

Both patients' operative techniques were similar. The patient was placed in supine position. A curvilinear incision was made directly over the large pseudocyst. The large pseudocyst was dissected free from the overlying skin and the dartos muscle. The inguinal cord structures (i.e. vas deferens and testicular vessels) and the testis were difficult to identify exteriorly as they had been incorporated into the thick wall of the pseudocyst. The wall of the pseudocyst was opened anterolaterally to avoid any injury to the poorly visible cord structures. Upon laying open the cyst, the testis was identified by its white colored tunica. Attempts to dissect the testis, vas deference and the testicular vasculature were futile due to the dense adhesions. Decision was made to partially excise the seroma leaving behind part of the pseudocyst wall that encased the testis, vas deferens and testicular vasculature. The inner surface of the residual cyst wall was cauterized using monopolar diathermy. A size 10 French gauge Blake drain (Ethicon) Silicone drain 10Fr round, hubless with 1/8" trocar-suction drain made in Israel -J-VAC adapter, trocar made in USA was placed to prevent further accumulation of fluid. The wound was infiltrated with 10mls of 0.5% Marcaine.

Both patients were discharged two days post-surgery with drain in-situ. At outpatient review, each drain was removed when zero drainage was seen for three consecutive days. On examination, both patients had some palpable thickening along the cord and testis, likely due to the residual partial cyst wall. Both patients remained asymptomatic six months after their pseudocyst resection and with no further seroma formation.

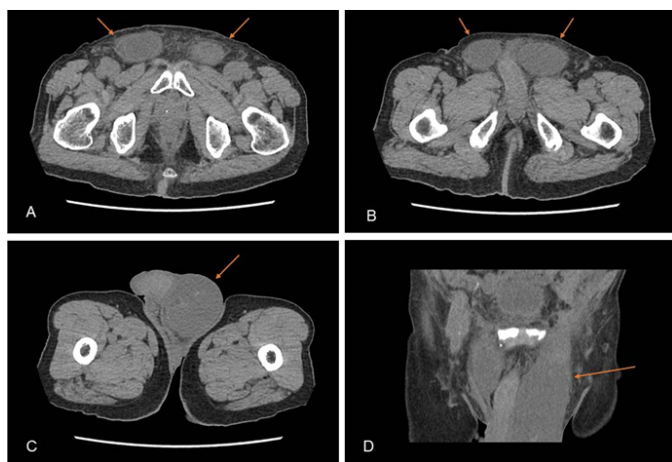


Figure 1: CT scan images (A-C axial view, D coronal view) showing a 13x5x6 cm collection extending from the superomedial aspect of the inguinal region into the left hemi-scrotum and a 7x3x4 cm collection on the right inguinal area (arrows indicate the collection).

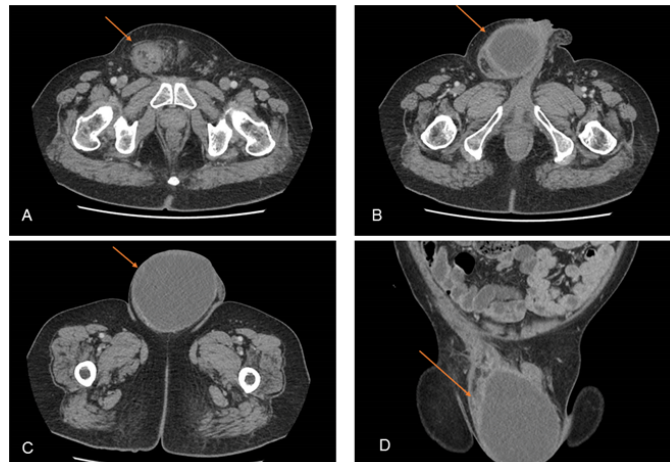


Figure 2: CT scan images (A-C axial view, D coronal view) showing diffuse thickening along the right spermatic cord and inguinal canal with a 12x9x10 cm collection compressing and displacing the penis and scrotal contents to the contralateral side. (arrows indicate the collection).

Cytology of the seroma fluid showed a mixed inflammatory cellular infiltrate with the presence of macrophages, small lymphocytes and neutrophils. The macroscopic appearance of the resected specimen revealed a smooth outer wall and a trabeculated and loculated inner lining (Figures 3 and 4). The histology of the pseudocyst wall showed hyalinization and fibrosis with granulation tissue and foci of mild chronic inflammation.

DISCUSSION

Prevention and treatment of post-operative seromas pose a challenge to all surgeons who perform inguinal hernia repair, regardless of surgical method whether open or laparoscopic. Seroma formation after inguinal surgery is common, especially following laparoscopic repair [1, 2, 4]. Most small seromas will resolve spontaneously without any intervention [2, 5]. However, large seromas can be symptomatic, causing pain and discomfort to patients. Aspiration is one of the simplest ways to treat seromas. However, it can be uncomfortable and possesses a risk of bacterial contamination [6]. Recurrences requiring repeated aspirations can also be frustrating for the patient. We believe that once the thick hyalinized and fibrotic wall develops around the seroma, repeated aspiration will inevitable be futile, making subsequent treatment challenging.

Both our patients developed large pseudocyst extending from the groin into the scrotum. Cord structures and testis were incorporated into the thick wall of the seroma making surgical excision challenging. Initial attempts to dissect and free the cord structures and testis using monopolar diathermy and scissor dissection were met with profuse oozing from the raw surface of the dissected area. In addition, we were concerned about potential injury to the testicular vessels which could result in testicular ischemia or infarction. Taking these issues into consideration, we opted to leave behind part of the cyst wall containing the testis and cord structures. The inner lining of the residual cyst wall was cauterized with monopolar diathermy, to prevent continued secretion of fluids from the inner surface which could result in recurrence. This is a similar surgical approach reported by Ielpo et al, who reported the first giant pseudocyst following herniorrhaphy in 2012 [7]. In another case report published recently, Favela et al successfully resected a giant scrotal pseudocyst completely from the cord structure [8]. These encompass all the case reports till date, either due to the rarity of pseudocyst as a complication, or underreporting of its incidence.

The pathogenesis of post-operative giant seromas is still not fully understood and is likely to be a complex interplay of factors [9, 10]. In our patients, we postulate that extensive dissection of the whole indirect inguinoscrotal sac might been a possible contributing factor. Dissection causes bleeding and tissue damage and further tissue trauma is caused by use of diathermy. The degree of tissue damage may have triggered an excessive inflammatory response and haemoserous inflammatory fluid formation, resulting in the collection of fluid in the inguinoscrotal space previously occupied by the indirect hernia sac. Furthermore, the marked inflammatory response results in formation of a thick fibrotic wall around the collection which prevents the fluid from being reabsorbed.

The histology of the pseudocyst provides some insight as to why conservative management with repeated aspiration did not worked in both our patients. Firstly, the mixed inflammatory yield within the seroma fluid highlights that the presence of mild chronic inflammation within the pseudocyst, a finding supported by Andrades et al and Klink et al. [11, 12]. The presence of persistent inflammation could account for the re-accumulation of fluid following repeated aspiration. Secondly, the chronic inflammatory process resulted in the formation of a thick hyalinized and fibrotic outer shell, preventing the reabsorption of fluid. Therefore, it is unlikely that the giant pseudocysts would have resolved without surgical intervention.

CONCLUSION

In conclusion, giant pseudocyst is a rare complication after inguinal hernia repair and there have been limited

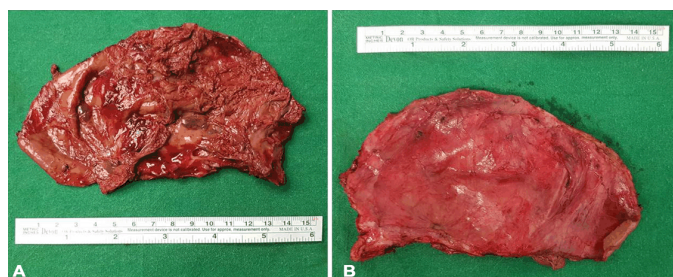


Figure 3: Resected pseudocyst. (A: Inner surface, B: Outer surface).

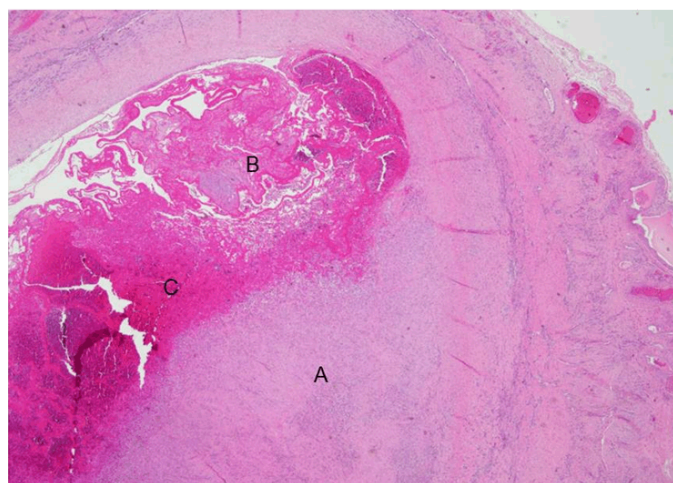


Figure 4: A: Thick hyalinized fibrous tissue, B: Blood clot, C: Granulation tissue.

reports on how these should be treated. In our report, we share our experience with successful surgical excision and postulate how extensive surgical dissection contributes to pathogenesis. We believe that surgical excision remains the definitive treatment for symptomatic giant inguinoscrotal pseudocyst which have failed repeated aspiration.

REFERENCES

1. Lau H, Lee F. Seroma following endoscopic extraperitoneal inguinal hernioplasty. *Surg Endosc* 2003;17(11):1773-7.
2. Cihan A, Ozdemir H, Uçan BH, et al. Fade or fate: Seroma in laparoscopic inguinal hernia repair. *Surg Endosc* 2006;20(2):325-8.
3. Fan JKM, Liu J, Chen K, et al. Preperitoneal closed-system suction drainage after totally extraperitoneal hernioplasty in the prevention of early seroma formation: A prospective double-blind randomised controlled trial. *Hernia* 2018;22(3):455-65.
4. Park A, Birch DW, Lovrics P. Laparoscopic and open incisional hernia repair: A comparison study. *Surgery* 1998;124(4):816-21.
5. Schwab JR, Beaird DA, Ramshaw BJ, et al. After 10 years and 1903 inguinal hernias, what is the outcome for the laparoscopic repair? *Surg Endosc* 2002;16(8):1201-6.
6. Toy FK, Bailey RW, Carey S, et al. Prospective multicenter study of laparoscopic ventral hernioplasty: Preliminary results. *Surg Endosc* 1998;12(7):955-9.
7. Ielpo B, Lapuente F, Martin P, et al. First cases of giant pseudocyst complicating inguinal hernia repair. *Hernia* 2012;16(5):589-91
8. Favela J, Huerta S. A case report of a groin pseudocyst following inguinal hernia repair and a review of the literature. *Int J Surg Case Rep* 2018;50:32-5.
9. Bonnema J, van Geel AN, Ligtenstein DA, Schmitz PI, Wiggers T. A prospective randomized trial of high versus low vacuum drainage after axillary dissection for breast cancer. *Am J Surg* 1997;173(2):76-9.
10. Bacilious N, Kulber DA, Peters ED, et al. Harvesting of the latissimus dorsi muscle: A small animal model for seroma formation. *Microsurgery* 1995;16(9):646-9.
11. Andrades P, Prado A, Danilla S, et al. Progressive tension sutures in the prevention of postabdominoplasty seroma: A prospective, randomized, double-blind clinical trial. *Plast Reconstr Surg* 2007;120(4):935-46.
12. Klink CD, Binnebösel M, Lucas AH, et al. Do drainage liquid characteristics serve as predictors for seroma formation after incisional hernia repair? *Hernia* 2010;14(2):175-9.

Acknowledgements

Dr. Michael Tan Chien Sheng for interpreting the histology slides of the pseudocyst.

Author Contributions

Joshua Sheng Hao Lim – Substantial contributions to conception and design, Acquisition of data, Analysis and interpretation of data, Drafting the article, Revising it critically for important intellectual content, Final approval of the version to be published

Ng Weng Leong Victor – Substantial contributions to conception and design, Acquisition of data, Analysis and interpretation of data, Drafting the article, Revising it critically for important intellectual content, Final approval of the version to be published

Kok Ren Lim – Substantial contributions to conception and design, Acquisition of data, Analysis and interpretation of data, Drafting the article, Revising it critically for important intellectual content, Final approval of the version to be published

Guarantor of Submission

The corresponding author is the guarantor of submission.

Source of Support

None.

Consent Statement

Written informed consent was obtained from the patient for publication of this case series.

Conflict of Interest

Authors declare no conflict of interest.

Data Availability

All relevant data are within the paper and its Supporting Information files.

Copyright

© 2019 Joshua Sheng Hao Lim et al. This article is distributed under the terms of Creative Commons Attribution License which permits unrestricted use, distribution and reproduction in any medium provided the original author(s) and original publisher are properly credited. Please see the copyright policy on the journal website for more information.

Access full text article on
other devices



Access PDF of article on
other devices

