

# Fetus-In-Fetu or fetaform teratoma: Clinical dilemma

Adnan Amin Alsulaimani, Alaaelddin Mohammed Elsayed EI-Zeky

## ABSTRACT

**Fetus in fetu (FIF) is an uncommon anomaly in Pediatric age group. The literature cites around 100 cases worldwide of twin fetus in fetu. Hypothesis vary about whether FIF represents an enclosure or failed monozygotic twin or a well-differentiated variant of mature teratomas. The presence of a vertebral column has been considered to be mandatory for the diagnosis of fetus in fetu. It should be differentiated from a teratoma because of the teratomas malignant potential. Our case is another example of lesion that fits in this spectrum of interesting dilemma and highlight on the magnitude of imaging studies to differentiate between them.**

**Keywords: Fetus in fetu, Fetaform teratoma**

### How to cite this article

Alsulaimani AA, EI-Zeky AME. Fetus-In-Fetu or fetaform teratoma: Clinical dilemma. Int J Case Rep Images 2018;9: 100984Z01AA2018.

Article ID: 100984Z01AA2018

\*\*\*\*\*

Adnan Amin Alsulaimani<sup>1</sup>, Alaaelddin Mohammed Elsayed EI-Zeky<sup>2</sup>

**Affiliations:** <sup>1</sup>Professor of Neonatology, Consultant Pediatrician, Prince Al-Mansour Armed Forces Hospital Taif, Kingdom of Saudi Arabia; <sup>2</sup>Consultant Neonatologist Al-Hada Armed Forces Hospital, Taif, Kingdom of Saudi Arabia, MRCPCH 2002, UK.

**Corresponding Author:** Adnan Amin Alsulaimani, Professor of Neonatology, Consultant Pediatrician, Prince Al-Mansour Armed Forces Hospital Taif, Kingdom of Saudi Arabia; Email: adnamn@gmail.com

Received: 26 September 2018

Accepted: 23 November 2018

Published: 17 December 2018

doi: 10.5348/100984Z01AA2018CR

## INTRODUCTION

Fetuses in fetu and retroperinatal teratoma have been considered as two distinct entities [1]; Recent literature question the necessity of presence of axial skeleton to be mandatory for the diagnosis of fetus-in-fetu [2]. This entity is differentiated from teratoma by its embryological origin, its unusual location in the retroperitoneal space, and the presence of vertebral organization with limb buds and well developed organ system. In most cases of FIF, only one fetus exists inside the baby, only on extremely rare cases are multiple fetuses found [3]. The surgical removal of the twin fetus is the treatment of choice.

## CASE REPORT

A two days old, full term male newborn born to a Saudi mother G<sub>5</sub>P<sub>5</sub> without any pregnancy or familial significant risk factors. The baby delivered by cesarian section due to breech presentation. Upon examination of the baby abdomen was discovered that a firm, irregular and non-tender mass was present in the left hypochondrium extending to the umbilical region, genitalia were normal apart from undescended bilateral testis. Conventional X-ray of the abdomen showed multiple dense radio-opacities in the left upper quadrant of the abdomen (Figure 1). An ultrasound of the baby abdomen showed a large encysted, hyperechoic heterogenous complex mass. MRI lumbar spine and CT scan of the baby's abdomen revealed (Figures 2 & 3) an encapsulated cystic peritoneal mass contain multiple bony elements of axial skeleton with pelvic girdle, lower extremity buds, ribs and no cranial vault can be appreciated. On laparotomy, a left upper quadrant retroperineal mass in 8x6 cm in size, covered with a sac containing a partially developed fetus with partial differentiation of the limbs, skull, spine and vertebrae (Figure 4). Both testes were felt retroperitonally. Baby did well and discharged home after few days in good general condition. The chromosome analysis confirm a male chromosome complement without structural anomalies. The tumor marker, Carcinoembryonic antigen (CEA) was normal.

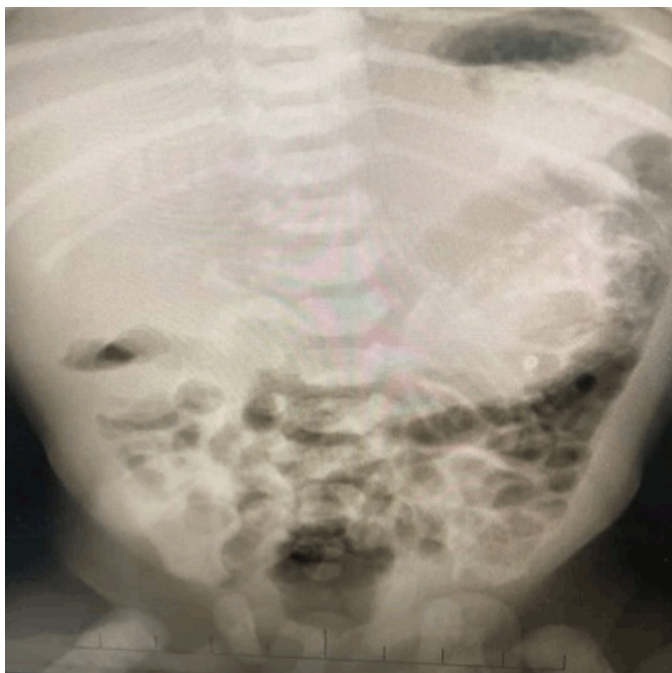


Figure 1: X-ray of abdomen showed heterogenous and amorphous large area of calcification, mostly peritoneal calcification seen in the left hypochondrial area. A small calcified area in right suprarenal region.

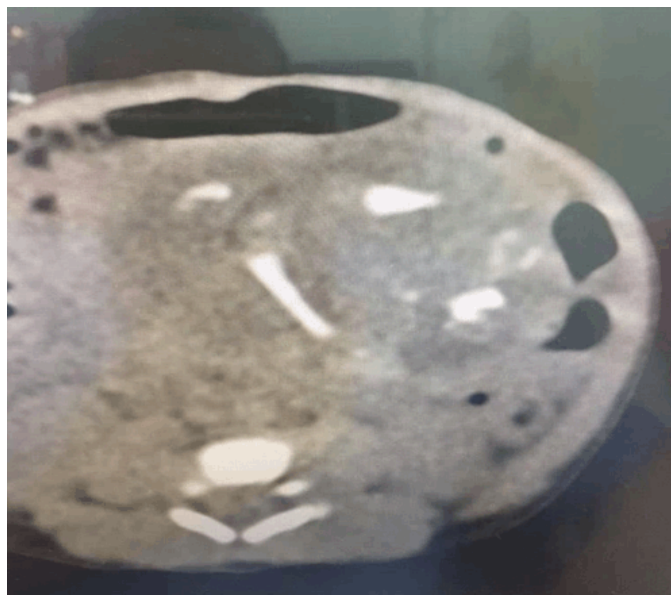

Figure 3: CT scan of the baby's abdomen showed encapsulated cystic peritoneal mass contain multiple bony elements of axial skeleton with pelvic girdle.

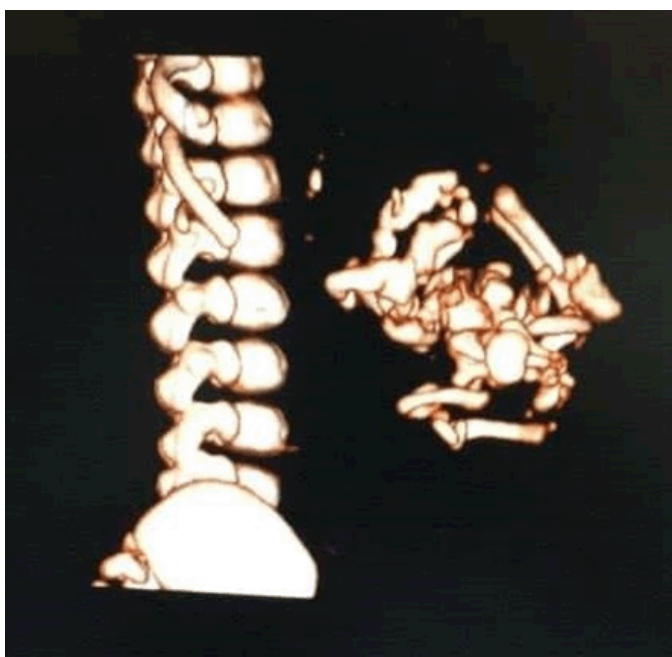


Figure 2: MRI Lumbar spine showed encapsulated cystic peritoneal mass contain multiple bony elements of axial skeleton with pelvic girdle.

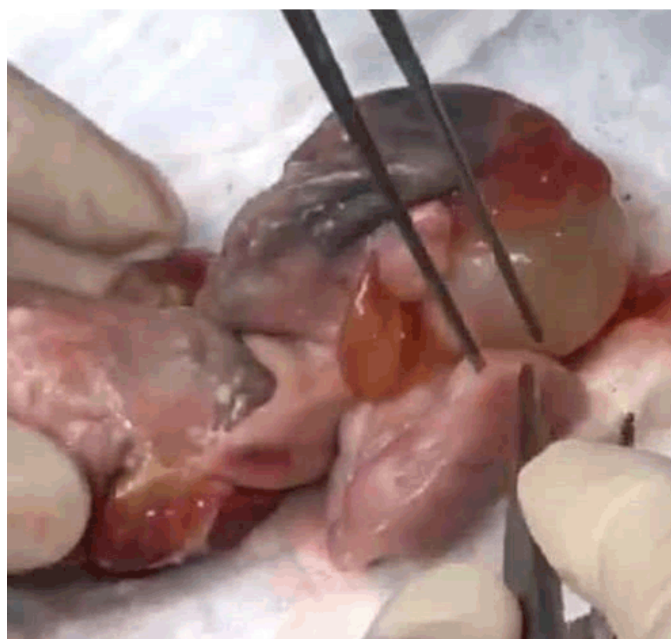

Figure 4: A mass sized 8x6 cm covered with a sac containing partially developed fetus.

## DISCUSSION

Fetus in fetu was generally considered a highly differential teratom till 1935. Willis et al [1] defined FIF as a separate entity containing some organs, limbs and vertebral column. The phenomenon of FIF has been described at least since the 17<sup>th</sup> century [4], but the credit

with first description of it go to Meckel in 1800 [5]. In review of the literature, about nine percent of cases of FIF, no vertebral skeleton could be identified an imaging or histopathologically. Moreover, more cases reported with hands, phalanges and nail were found but no vertebral column were exists [3, 6]. Most investigators believe that the presence of a developed vertebral column is not a prerequisite for diagnosis [7, 8]. Spencer [9] has suggested that an FIF must have one or more of the following condition:

- Be enclosed within a distinct sac.
- Be partially or completely covered by normal skin.

- Have grossly recognizable anatomic parts.
- Be attached to the host by only a few relatively large blood vessels.
- Either be located immediately adjacent to one of the site of attachment of conjoined twins or be associated with the neutral tube or the gastrointestinal system.

A teratoma, on the other hand, shows lesser organization of microscopically identifiable tissues. Teratoma have a broader attachment site with multiple small blood vessels. The differential diagnosis of a complex mass with calcified components in a fetus or neonate include FIF, teratoma, meconium pseudocyst and neuroblastoma [2]. Our case include most of spencer characteristics of FIF. The normal value of CEA marker, the coexistence of vertebral column and the finding of the testis in the retroperionium, all confirm the diagnosis of FIF in this case. Although the prognosis for FIF is more favorable than for cystic teratoma, the presence of immature elements nevertheless indicates the need for close clinical radiological, serological and tumor marker work-up.

## CONCLUSION

We conclude Fetus in fetu is an extremely rare condition. Currently it is considered as a benign condition; however, controversy continues regarding its future malignant potential or association. When mass compression becomes significant, as in our case, the child or adult can suffer from poor growth or development, infections and even lack of organ function. With surgical treatment, normal anatomy and physiology can be restored and the malignant potential excised. Definitive diagnosis is best made using CT and MRI techniques serology test and tumor marker surveillance and in addition to genetic testing and pathologic reviews, physicians must consider the potential for a minimum of 18 months follow up to avoid a missed malignancy. Surgical outcomes are reportedly good following excision, but further data collection is required for long term results.

## REFERENCES

1. Willis RA. The borderland of embryology and pathology. Bull N Y Acad Med 1950 Jul;26(7):440-60.
2. Higgins KR, Coley BD. Fetus in fetu and fetiform teratoma in 2 neonates: An embryologic spectrum? J Ultrasound Med 2006 Feb;25(2):259-63.
3. Hoeffel CC, Nguyen KQ, Phan HT, et al. Fetus in fetu: A case report and literature review. Pediatrics 2000 Jun;105(6):1335-44.
4. Gould GM, Pyle WL. Anomalies and Curiosities of Medicine. Philadelphia, PA: WB Saunders Company; 1896.

5. Senyüz OF, Rizalar R, Celayir S, Oz F. Fetus in fetu or giant epignathus protruding from the mouth. J Pediatr Surg 1992 Dec;27(12):1493-5.
6. Basu A, Jagdish S, Iyengar KR, Basu D. Fetus in fetu or differentiated teratomas? Indian J Pathol Microbiol 2006 Oct;49(4):563-5.
7. Marnet D, Vinchon M, Kerdraon O, Joriot S, Chafiotte C, Dhellemmes P. Antenatal diagnosis of a third ventricular mass: Fetus in fetu or teratoma? Childs Nerv Syst 2008 Aug;24(8):887-91.
8. Chua JH, Chui CH, Sai Prasad TR, Jabcobsen AS, Meenakshi A, Hwang WS. Fetus-in-fetu in the pelvis: Report of a case and literature review. Ann Acad Med Singapore 2005 Nov;34(10):646-9.
9. Spencer R. Parasitic conjoined twins: External, internal (fetuses in fetu and teratomas), and detached (acardiacs). Clin Anat 2001 Nov;14(6):428-44.

\*\*\*\*\*

## Acknowledgement

I wish to express our sincere gratitude to Ms. Nihad Alim for helping us in encoding the entire manuscript. Her flexibility in work helped us successfully in completing this manuscript.

## Author Contributions

Adnan Amin Alsulaimani – Substantial contributions to conception and design, Acquisition of data, Analysis and interpretation of data, Drafting the article, Revising it critically for important intellectual content, Final approval of the version to be published

Alaaeldin Mohammed Elsayed EI-Zeky – Substantial contributions to conception and design, Acquisition of data, Analysis and interpretation of data, Drafting the article, Revising it critically for important intellectual content, Final approval of the version to be published

## Guarantor of Submission

The corresponding author is the guarantor of submission.

## Source of Support

None.

## Consent Statement

Written informed consent was obtained from the patient for publication of this case report.

## Conflict of Interest

Authors declare no conflict of interest.

## Data Availability

All relevant data are within the paper and its Supporting Information files.

## Copyright

© 2018 Adnan Amin Alsulaimani et al. This article is distributed under the terms of Creative Commons Attribution License which permits unrestricted use,

distribution and reproduction in any medium provided the original author(s) and original publisher are properly

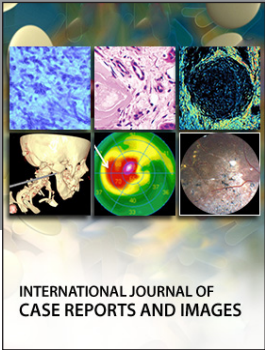
credited. Please see the copyright policy on the journal website for more information.

Access full text article on  
other devices



Access PDF of article on  
other devices





INTERNATIONAL JOURNAL OF CASE REPORTS AND IMAGES



VIDEO JOURNAL OF CLINICAL RESEARCH



VIDEO JOURNAL OF BIOMEDICAL SCIENCE



INTERNATIONAL JOURNAL OF HEPATOBILIARY AND PANCREATIC DISEASES




INTERNATIONAL JOURNAL OF BLOOD TRANSFUSION AND IMMUNOHEMATOLOGY



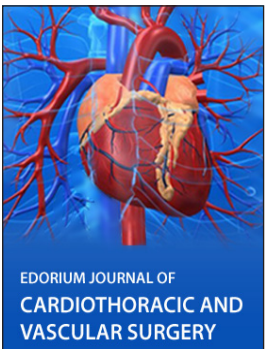
EDORIUM JOURNAL OF OPHTHALMOLOGY



**Submit your manuscripts at**  
[www.edoriumjournals.com](http://www.edoriumjournals.com)



EDORIUM JOURNAL OF MEDICINE



EDORIUM JOURNAL OF CARDIOTHORACIC AND VASCULAR SURGERY



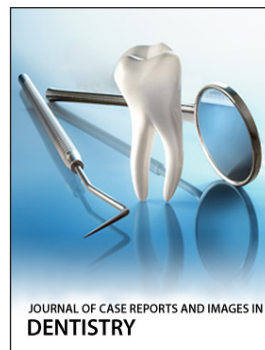JOURNAL OF CASE REPORTS AND IMAGES IN ORTHOPEDICS AND RHEUMATOLOGY



EDORIUM JOURNAL OF PSYCHOLOGY



EDORIUM JOURNAL OF CELL BIOLOGY



JOURNAL OF CASE REPORTS AND IMAGES IN DENTISTRY



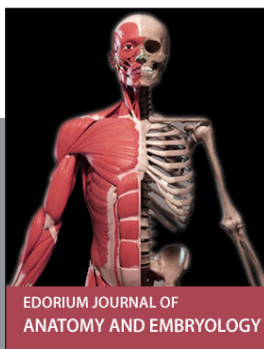EDORIUM JOURNAL OF CANCER



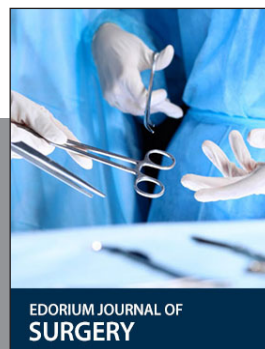
EDORIUM JOURNAL OF PSYCHIATRY



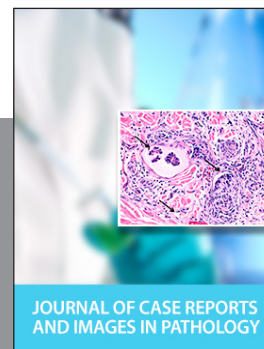JOURNAL OF CASE REPORTS AND IMAGES IN INFECTIOUS DISEASES



EDORIUM JOURNAL OF ANATOMY AND EMBRYOLOGY



EDORIUM JOURNAL OF SURGERY



JOURNAL OF CASE REPORTS AND IMAGES IN PATHOLOGY



EDORIUM JOURNAL OF ANESTHESIA