

# A novel approach of non-surgical faecal diversion technique with stoma bag application: A case report

Tzu-Yi Chuang, Paul Tingey, Hassan Malik,  
Havish Srinath, Andrew Thomas Sax

## ABSTRACT

**Introduction:** Faecal diversion techniques are commonly used to avoid contamination of wounds in the perianal, gluteal, or upper thigh regions. Diversion may be achieved using operative or non-operative methods. Traditional non-operative methods may be less effective for patients with anal sphincter damage or dysfunction. **Case Report:** Our report discusses a novel faecal diversion technique in a 67-year old female with a gluteal abscess complicated by necrotising fasciitis, which effectively used a perianal stoma to prevent faecal contamination of her wound. **Conclusion:** This method was safe, inexpensive, and effective, and prevented the need of operative management. We feel this technique is valuable in preventing faecal wound contamination in individuals with anal sphincter damage or dysfunction.

**Keywords:** Faecal diversion, Stoma bag, Perianal stoma

Tzu-Yi Chuang<sup>1</sup>, Paul Tingey<sup>2</sup>, Hassan Malik<sup>3</sup>, Havish Srinath<sup>3</sup>, Andrew Thomas Sax<sup>4</sup>

**Affiliations:** <sup>1</sup>Surgical Principle House Officer, Department of General Surgery, Ipswich Hospital, Ipswich, Queensland, Australia; <sup>2</sup>Surgical Intern, Department of General Surgery, Ipswich, Ipswich, Queensland, Australia; <sup>3</sup>Surgical Registrar, Department of General Surgery, Ipswich Hospital, Ipswich, Queensland, Australia; <sup>4</sup>Medical Student, Faculty of Medicine, The University of Queensland, Queensland, Australia

**Corresponding Author:** Tzu-Yi (Arron) Chuang, 7/141 Station Road, Sunnybank, Queensland-4109, Australia; Email: Thomas0227@hotmail.com

Received: 27 September 2018

Accepted: 10 October 2018

Published: 23 November 2018

## How to cite this article

Chuang TY, Tingey P, Malik H, Srinath H, Sax A. A novel approach of non-surgical faecal diversion technique with stoma bag application: A case report. Int J Case Rep Images 2018;9:100971Z01TC2018.

Article ID: 100971Z01TC2018

\*\*\*\*\*

doi: 10.5348/100971Z01TC2018CR

## INTRODUCTION

Wound management around the perineal region is always a challenging task due to high risk of faecal contamination. Perineal wounds are commonly caused by severe infections such as necrotising fasciitis and Fournier's gangrene; pressure ulcers from long term immobilised patients; or burns [1–6]. The risk of infection due to faecal contamination can result in sepsis, graft failure, delayed wound healing or scar complications. Most patients with serious perineal wounds require extensive and multiple surgical debridement to improve healing and establish adequate infection control. In order to optimise the wound healing and prevent sepsis, faecal diversion is often required to reduce wound contamination [1–3].

Faecal diverting systems have been classified according to surgical and non-surgical approaches. Surgical diverting systems involve a diverting stoma creation such as an ileostomy or colostomy. Non-surgical interventions involve the insertion of Foley catheter into the anus, rectal tube or faecal pouch, and more recent interventions such as balloon based catheter stool management systems (e.g. The Zassi bowel management system or ConvaTec Flexi-Seal management system), or non-balloon-based self-retaining device (e.g. Qora SMK) [6]. Although catheter stool management systems have been shown to be an effective method for faecal diversion, it appears to have limitations in patients with anal sphincter damage.

In our study, we present the first ever case to describe a stoma bag application on the perianal area as a non-surgical faecal diversion system for patients with anal sphincter damage.

## CASE REPORT

A 67-year-old obese female was brought in by ambulance with clinical signs of septic shock. She suffered from a 3 day history of increasing right buttock pain, diarrhoea and light headedness. The ambulance service was contacted by the patient and she was found to be hypotensive (83/54 mmHg), febrile (38.3 °C) and tachycardia (110 bpm). Her pertinent medical history includes alcohol dependence, hypertension, hypothyroidism, gastroesophageal reflux disease, chronic back pain and obesity. At the emergency department, she received resuscitation with 3.5 L of crystalloid fluid. A central line and arterial line were both established and secured with a noradrenaline infusion. Meropenem, vancomycin and lincomycin were given while the patient was in emergency department. Urgent surgical review revealed that she had signs of necrotising fasciitis of the right buttock extending to the perineal verge. The anaesthetic team and intensive care unit were both involved prior to emergency surgery. Intra-operatively, it was found that necrotic subcutaneous fat had extended laterally from right buttock to per-anal margin medially and superiorly. No perineum extension was noted. She was admitted to the ICU post-operatively. A relook operation was done on day 1 following the initial procedure due to increasing inotropic requirements. Further debridement was done to extend superiorly to the iliac brim and laterally to right greater trochanter. Vacuum dressing was applied to right buttock in the 3<sup>rd</sup> surgical debridement. The patient underwent a total of seven surgical debridement procedures under general anaesthesia. Vacuum dressing was applied to the wound from day 4 with 2-3 day dressing changes which also allowed for routine examination. IV meropenem, vancomycin and lincomycin were continued throughout the patients admission. It was additionally found that the patient had gram positive cocci bacteraemia, *Staphylococcus Aureus* 2+ isolated from the wound swab, and a concurrent *E. Coli* urinary tract infection. As a result, the infectious disease team subsequently changed her antibiotic to 4 weeks of intravenous Flucloxacillin and Piperacillin/Tazobactam on day 5 of admission. An echocardiogram was also performed to rule out infective endocarditis; no abnormalities were detected.

Our patient unfortunately displayed signs of significant anal sphincter tone weakness with faecal incontinence as her inpatient stay progressed. We attempted to use a non-balloon catheter-based stool management kit several times post-surgical debridement without success as it was unable to maintain a good position with soiling

around the tube followed by dislodged of the tube itself. In an attempt to overcome this, the patient was given loperamide and codeine to thicken the faecal effluent. With numerous trials of different methods to successfully divert the faeces, we decided to approximate the inferior part of wound around the perianal region by suturing the segments with 0' nylon (Figure 1). We subsequently applied a stoma bag around the perianal region. We then utilised stoma adhesive paste to assist the union of the stoma bag to the perianal area, extending to the perineal raphe. Duoderm™ was also applied around the stoma bag. We then applied the vacuum dressing on the right buttock wound as shown in Figure 2. Careful monitoring was conducted and no significant soiling or faecal contamination was noted.

Her perineal wound had slowly improved with good granulation tissue and minimal faecal contamination. The plastic and reconstructive team subsequently became involved in her care and a split skin graft was applied on day 29 following admission. A successful 80% graft take is shown on Figure 3 (one week post graft application). As the patient had significant functional deconditioning associated with poor motility, she was subsequently transferred to rehabilitation for ongoing intense physiotherapy and a rehabilitation program.

## DISCUSSION

Necrotising fasciitis is a disease associated with acute fulminant infection of the genital, perineal and abdominal regions [1]. Early diagnosis with aggressive surgical debridement and appropriate wound care is the cornerstone of the treatment in these cases [1]. Faecal

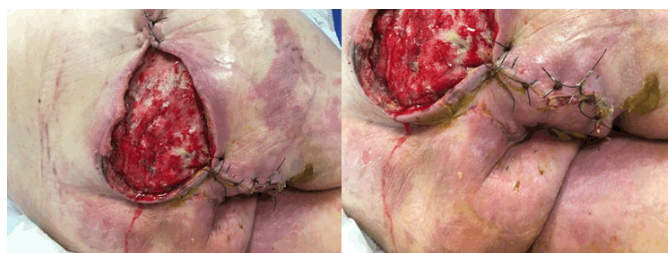

Figure 1: Approximation of the wound edges was achieved with 0' nylon sutures.

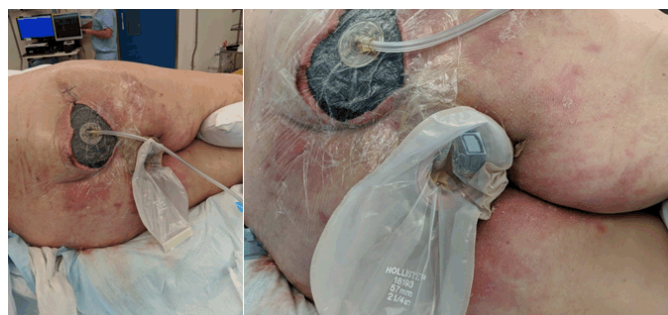


Figure 2: Application of the stoma bag with stoma paste and vacuum dressing at wound site.

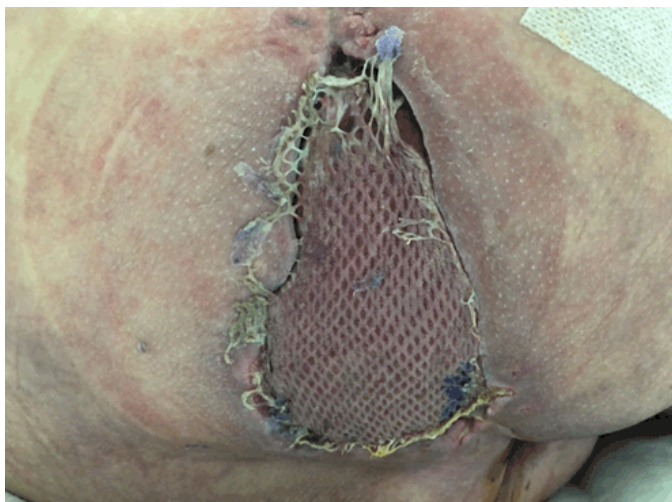

Figure 3: Skin graft site one week following the procedure.

contamination has been known to be one of the risk factors for perineal wounds, especially in patients with sphincter dysfunction, faecal incontinence and long-term bed-ridden patients. Surgical stoma formation such as temporary diverting ileostomy or colostomy is traditionally used to avoid faecal contamination. However, the complications of stoma formation and reversal of stoma significantly increase the patient's overall morbidity, motility, length of hospital stay, and healthcare costs. Specific complications of stoma formation include leak, stoma failure, infection, parastomal hernia, bowel obstruction, necrosis, stenosis or prolapse of stoma. Additionally, reversal of the stoma also can be complicated by anastomotic leakage, wound infection, bowel obstruction, intraabdominal collection and bowel injury.

Over the past few decades, many papers have discussed non-surgical faecal diversion methods such as Foley catheter attachment to the anus, rectal tube insertion, creation of faecal pouch, and stool management systems with or without balloons [1–6]. It has been shown that non-surgical faecal diverting systems have reduced the patient's duration of hospital stay, additional surgery requirements, and rate of complications [6]. Additionally, from a healthcare cost perspective, Sheth et al. [1] report that the average cost of a faecal diversion with colostomy is US\$9341, whereas usage of an intrarectal balloon catheter is approximately US\$6510. Given these advantages, it is recommended that a bowel management catheter is the preferred method compared to colostomy in patients without anal sphincter or rectal injury [6].

Balloon-based catheter stool management systems have been used in many perianal sepsis cases, however, it has been shown that the balloon can increase the risk of necrosis due to over-inflation of the balloon and subsequent haemorrhage in the rectum, sphincter dysfunction, and anal erosion [1].

We unfortunately failed to apply a non-balloon-based self-retaining device multiple times while the patient was

in the intensive care unit. The device had expelled itself several times, perhaps due to patient's anal sphincter damage. Our case supports the fact that catheter based management stool may not be useful for patients with anal sphincter damage.

Although catheter based stool management systems have been shown to be effective, it may not be applicable in patients with anal sphincter or rectal injury. As described in case report section, we have successfully demonstrated that the application of a stoma bag in the perianal area provides a useful and cost effective method to divert the faeces. This allows us to avoid surgical intervention thus improving patient's clinical outcome.

## CONCLUSION

Necrotising fasciitis is a serious infection involved in the genital, perineal and abdominal region. Faecal contamination is a crucial issue for perianal wound healing. Numerous faecal diversion methods had been proposed and applied. Non-surgical, non-balloon catheter based faecal diverting systems have been shown to be the preferred method, however, it may be not suitable for patients with anal sphincter or rectal injury. Here, we demonstrated a successful and cost-effective approach to control faecal contamination by applying a stoma bag with stoma paste along with a vacuum dressing on the perianal wound. This has assisted us in avoiding surgical ileostomy/colostomy formation and further reduced the likelihood of surgical complications.

\*\*\*\*\*

## Acknowledgements

We would like to thank our plastic and reconstructive colleagues, ICU, anaesthetic team, and infectious disease team for their valuable contributions in this case.

## Author Contributions

Tzu-Yi Chuang – Acquisition of data, Analysis and interpretation of data, Drafting the article, Revising it critically for important intellectual content, Final approval of the version to be published

Paul Tingey – Acquisition of data, Revising it critically for important intellectual content, Final approval of the version to be published

Hassan Malik – Acquisition of data, Revising it critically for important intellectual content, Final approval of the version to be published

Havish Srinath – Acquisition of data, Analysis and interpretation of data, Drafting the article, Revising it critically for important intellectual content, Final approval of the version to be published

Andrew Thomas Sax – Analysis and interpretation of data, Drafting the article, Revising it critically for important intellectual content, Final approval of the version to be published

**Guarantor of Submission**

The corresponding author is the guarantor of submission.

**Source of Support**

None.

**Consent Statement**

Written informed consent was obtained from the patient for publication of this case report.

**Conflict of Interest**

Authors declare no conflict of interest.

**Data Availability**

All relevant data are within the paper and its Supporting Information files.

**Copyright**

© 2018 Tzu-Yi Chuang et al. This article is distributed under the terms of Creative Commons Attribution License which permits unrestricted use, distribution and reproduction in any medium provided the original author(s) and original publisher are properly credited. Please see the copyright policy on the journal website for more information.

**REFERENCES**

1. Sheth H, Rao SA, Venkataramani K. Contemporary non-surgical approach for faecal diversion in a case of Fournier's gangrene. *BMJ Case Rep* 2017 Dec 22;2017.
2. Keshava A, Renwick A, Stewart P, Pilley A. A nonsurgical means of fecal diversion: The Zassi Bowel Management System. *Dis Colon Rectum* 2007 Jul;50(7):1017-22.
3. Goh M, Chew MH, Au-Yong PS, Ong CE, Tang CL. Nonsurgical faecal diversion in the management of severe perianal sepsis: A retrospective evaluation of the flexible faecal management system. *Singapore Med J* 2014 Dec;55(12):635-9.
4. Bordes J, Goutorbe P, Asencio Y, Meaudre E, Dantzer E. A non-surgical device for faecal diversion in the management of perineal burns. *Burns* 2008 Sep;34(6):840-4.
5. Oguz A, Gümüs M, Turkoglu A, et al. Fournier's Gangrene: A summary of 10 years of clinical experience. *Int Surg* 2015 May;100(5):934-41.
6. Eray IC, Alabaz O, Akcam AT, et al. Comparison of diverting colostomy and bowel management catheter applications in fournier gangrene cases requiring fecal diversion. *Indian J Surg* 2015 Dec;77(Suppl 2):438-41.

Access full text article on  
other devices



Access PDF of article on  
other devices

