

Langar's axillary arch; a misleading finding to the physicians and unexpected barrier to the surgeons

Sardar Hassan Arif, Ayad Ahmad Mohammed, Abdulwahid M. Salih, Fahmi Hussein Kakamad

ABSTRACT

Introduction: Variation in the axillary anatomy is of tremendous practical relevance along almost all operations executed in this area. The aim of this study is to report and discuss a case with the axillary arch of Langer. **Case Report:** A 48-year-old lady presented to the clinic with a right breast mass sized about 3×2.5 cm in the upper outer quadrant for a 6-month duration. The mass was proved to be malignant. During mastectomy and axillary lymph node dissection, an abnormal muscle was encountered that crossed the axilla in front of the axillary vessels and extended from the pectoralis major muscle to the latissimus dorsi. **Conclusion:** Axillary arch of Langer is a rare but crucial anatomical variation of the axillary region required to be known by every physician and surgeon dealing with pathologies in this region to promote their assessment and dissection skill.

Keywords: Axillary arch, Axillary lymph node dissection, Langer's muscle, Latissimus dorsi muscle

Sardar Hasan Arif¹, Ayad Ahmad Mohammed¹, Abdulwahid M. Salih², Fahmi Hussein Kakamad³

Affiliations: ¹University of Duhok, College of Medicine, Department of General Surgery, Duhok, Kurdistan Region, Iraq; ²University of Sulaimani, College of Medicine, Department of General Surgery, Sulaimani, Kurdistan Region, Iraq; ³Kscien organization, Hamdi Str. Azadi Mall, Sulaimani, Kurdistan Region, Iraq.

Corresponding Author: Fahmi Hussein Kakamad, Doctor City, 11th Building, Apartment 50, Sulaimani, Kurdistan region, Iraq; Email:fahmi.hussein@univsul.edu.iq

Received: 10 June 2018

Accepted: 08 October 2018

Published: 13 November 2018

How to cite this article

Arif SH, Mohammed AA, Salih AM, Kakamad FH. Langar's axillary arch; a misleading finding to the physicians and unexpected barrier to the surgeons. Int J Case Rep Images 2018;9:100966Z01SA2018.

Article ID: 100966Z01SA2018

doi: 10.5348/100966Z01SA2018CR

INTRODUCTION

Variation in the axillary anatomy is of tremendous practical relevance along almost all operations executed in this area. These range from the major procedures like vascular bypass surgeries, axillary dissection and reconstructive procedures to the minimal axillary operations like sentinel lymph node biopsy (SLNB), where accuracy in perceiving anatomical landmarks is crucial [1]. Various small muscles like dorso-epitrochlearis, chondro-epitrochlearis, costo-coracoideus which collectively called axillary arches or Langar's axillary arch are seldom encountered in the axillary region, and they are regarded as the principle axillary anatomy variation [2]. Although the size of the muscle is not constant, it measures about 0.5-1.5 cm in breadth and 7-10 cm in length. It could be singular or multiple fibers [2]. It extends from the coracobrachialis, pectoralis major, or the fascia covering the biceps brachii to the edge of latissimus dorsi crossing the neurovascular bundle of the upper arm [3, 4]. The aim of this study is to report and discuss a case with the axillary arch of Langer.

CASE REPORT

A 48-year-old lady presented to the clinic with a right breast mass sized about 3×2.5 cm in the upper outer

quadrant for a 6-month duration. The axilla was free of lymph node by examination. The mass assessed by the triple assessment (mammography, ultrasound, and biopsy) and proved to be malignant. There was no evidence of metastatic disease (as proven by PET scan). During the mastectomy, and axillary lymph node dissection, we encountered an abnormal muscle that crossed the axilla in front of the axillary vessels and extended from the pectoralis major muscle to the latissimus dorsi (Figure 1). We excised the slip to gain access to the axilla and proceed to axillary lymph node dissection. The surgery was uneventful, and the patient had no postoperative complications. The pathological assessment revealed invasive ductal carcinoma Grade 3, one out of 11 lymph nodes was involved by the tumor. The tumor was positive for estrogen and progesterone receptors and negative for Her2/neu, and the ki67 were expressed in 10% of the cells.

DISCUSSION

The muscular arch of the axilla (axillopectoral muscle, Langer's axillary arch) can be described as an anomalous muscular slip of the latissimus dorsi muscle. It generally joins the pectoralis major muscle to insert onto the lateral border of the intertubercular sulcus of the humerus, passing medially and anteriorly to the biceps brachii, and coracobrachialis muscles, the axillary artery, and comitant veins, the median, ulnar, and radial nerves and the medial cutaneous nerve of the forearm.

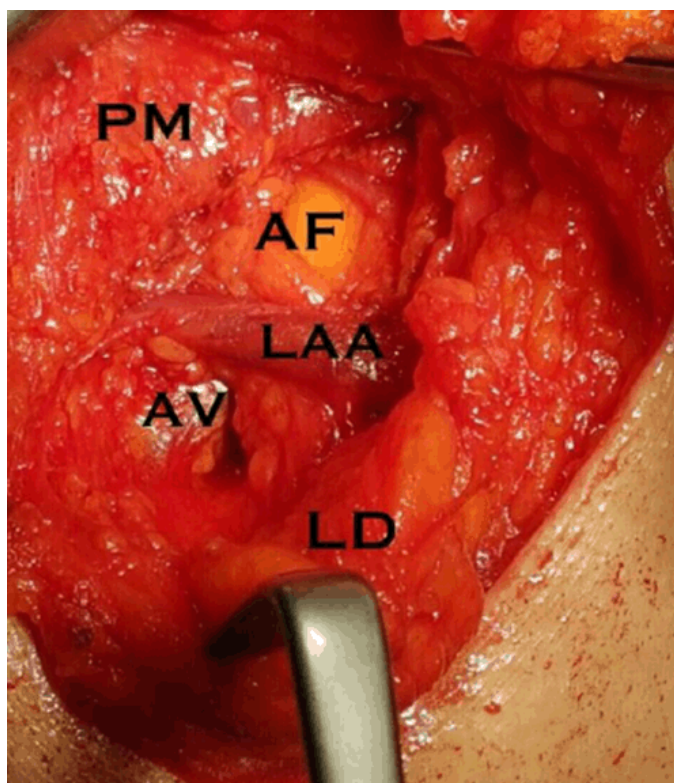


Figure 1: Showing the right axilla during surgery. PM, pectoralis major; AF, axillary fat; AA, Langer's axillary arch; AV, axillary vein; LD latissimus dorsi.

This anatomical variation although certified by Langer in 1864, it was first chronicled by Ramsay in 1795. Despite the fact that contrasting prevalence has been recorded by the anatomists and surgeons, its precise picture has never been confirmed [4–6]. However, the popularity range depends on the population. Numbers can be found in the literature between 1.7% in the Turkish population, and 43.8% in the Chinese population [7, 8]. The frequency of this anatomical variation has never been reported in our country (Iraq) and its prevalence in this region is not known. Jeleu summarized the three main characteristics of a typical axillary arch in his literature review; (1) the axillary arch has a constant origin from the latissimus dorsi muscle, (2) the structures surrounding the posteroanterior part of the upper axillary neurovascular bundle from the ventrolateral to the dorsomedial region [9].

Preoperative awareness of this variation is achievable by a history of periodic axillary vein thrombosis, loss of the normal concavity of the axilla, a marked disparity between axillary fullness, the great difficulty encountered in the axillary examination, phlebography and operation [3, 9]. Magnetic resonance imaging (MRI) is a helpful tool to diagnose the axillary arch. It can positively correlate its presence with neurovascular entrapment symptoms. Also, it can assess its anatomic relations [10, 11]. Knowledge about anatomical alterations of the axillary region is very influential for both the surgeon and the physician who want to perform axillary operation or examination. Ligature mistakenly might be applied to the axillary arch of Langer, which if present passes over the axillary vessels and cause an unexpected problem [12].

supra axillary plane may be wrongly dissected because of the few axillary lymph nodes buried in the axillary arches [13]. If the arch of Langer is faced during axillary lymph node dissection, the nodes lateral and posterior to the arch should be removed. Unawareness to this problem may lead to local recurrence in patients with breast cancer and melanoma. This is in spite of imprecise cancer staging and improper subsequent management [13].

The axillary arch may be confused for the true lateral margin of the latissimus dorsi muscle. This may guide the operators to go into an area superior to the axillary vein escalating the peril of injury to the brachial plexus and axillary artery.

During sentinel node biopsy, the axillary arch can pose difficulty as it stretches in the hyper extension shifting the nodes into a higher region. Lymphoedema might be precipitated when breast reconstructed using latissimus dorsi myocutaneous flap. For this reason, a division of the axillary arch is necessary if the requirement for this flap is anticipated [14].

CONCLUSION

Axillary arch of Langer is a rare but crucial anatomical variation of the axillary region required to be known by

every physician and surgeon dealing with the pathologies of this region to promote their assessment and dissection skill.

REFERENCES

1. Clarys JP, Barbaix E, Van Rompaey H, Caboor D, Van Roy P. The muscular arch of the axilla revisited: its possible role in the thoracic outlet and shoulder instability syndromes. *Man Ther* 1996 Jun;1(3):133–139.
2. Le Bouedec G, Dauplat J, Guillot M, Vanneuville G. The axillopectoral muscle. [Article in French]. *J Chir (Paris)* 1993 Feb;130(2):66–9.
3. Miguel M, Llusá M, Ortiz JC, Porta N, Lorente M, Götzens V. The axillopectoral muscle (of Langer): Report of three cases. *Surg Radiol Anat* 2001 Sep;23(5):341–3.
4. Jeleu L, Georgiev GP, Surchev L. Axillary arch in human: Common morphology and variety. Definition of “clinical” axillary arch and its classification. *Ann Anat* 2007;189(5):473–81.
5. Georgiev GP, Jeleu L, Surchev L. Axillary arch in Bulgarian population: Clinical significance of the arches. *Clin Anat* 2007 Apr;20(3):286–91.
6. Besana-Ciani I, Greenall MJ. Langer’s axillary arch: Anatomy, embryological features and surgical implications. *Surgeon* 2005 Oct;3(5):325–7.
7. Kalaycioglu A, Gümüşalan Y, Ozan H. Anomalous insertional slip of latissimus dorsi muscle: Arcus axillaris. *Surg Radiol Anat* 1998;20(1):73–5.
8. Wagenseil F. Muskelbefunde bei Chinesen. *Verh Ges Phys Anthropol (Stuttgart)* 1927;2:42–51.
9. Sachatello CR. The axillopectoral muscle (Langer’s axillary arch): A cause of axillary vein obstruction. *Surgery* 1977 May;81(5):610–2.
10. Kanaka S, Pulipati A, Gaikwad M. Axillary arch and its relations— A rare case report. *Int J Biol Med Res* 2012;3:2277–9.
11. Karanlik H, Fathalizadeh A, Ilhan B, Serin K, Kurul S. Axillary arch may affect axillary lymphadenectomy. *Breast Care (Basel)* 2013 Dec;8(6):424–7.
12. Williams PL, Warwick R, Dyson M, Bannister LH. *Gray’s Anatomy*. 37ed. London: Churchill Livingstone; 1989.
13. Petrasek AJ, Semple JL, McCready DR. The surgical and oncologic significance of the axillary arch during axillary lymphadenectomy. *Can J Surg* 1997 Feb;40(1):44–7.
14. Kataria K, Srivastava A, Mandal A. Axillary arch muscle: A case report. *Eur J Anat* 2013; 17:259–61.

Author Contributions

Sardar Hasan Arif – Substantial contributions to conception and design, Acquisition of data, Analysis and interpretation of data, Drafting the article, Revising it critically for important intellectual content, Final approval of the version to be published

Ayad Ahmad Mohammed – Substantial contribution to the concept and design, Drafting the article, Revising it critically for important intellectual content, Final approval of the version to be published

Abdulwahid M. Salih – Substantial contribution to the concept and design, Drafting the article, Revising it critically for important intellectual content, Final approval of the version to be published

Fahmi Hussein Kakamad – Substantial contribution to the concept and design, Drafting the article, Revising it critically for important intellectual content, Final approval of the version to be published

Guarantor of Submission

The corresponding author is the guarantor of submission.

Source of Support

None.

Consent Statement

Written informed consent was obtained from the patient for publication of this case report.

Conflict of Interest

Authors declare no conflict of interest.

Data Availability

All relevant data are within the paper and its Supporting Information files.

Copyright

© 2018 Sardar Hasan Arif et al. This article is distributed under the terms of Creative Commons Attribution License which permits unrestricted use, distribution and reproduction in any medium provided the original author(s) and original publisher are properly credited. Please see the copyright policy on the journal website for more information.

Access full text article on
other devices



Access PDF of article on
other devices

