

Delayed acute abdomen of a farthest wandering fecalith retained after laparoscopic appendectomy

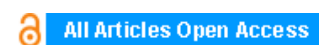
Ahmet Kocakusak, Mehmet Kulus, Yusuf Emre Altundal

ABSTRACT

Introduction: Retained fecaliths are avoidable complications of laparoscopic appendectomy. We reported herein a case of delayed acute abdomen caused by a far wandering appendicolith retained after laparoscopic appendectomy.

Case Report: A 24-year-old male who had been operated on because of acute appendicitis in our emergency department 15 days ago, was readmitted with signs and symptoms of acute abdomen. According to his medical history, laparoscopic appendectomy had been converted into open surgery because of perforated appendix and the patient had been discharged from the hospital on the second postoperative day without any complication. Laboratory results were within normal ranges except for the elevated levels of C-reactive protein and leukocyte count. Direct abdominal X-ray, ultrasonography and computed tomography detected a stoney structure of 2 cm surrounded by omentum and intestines at the right side of the vertebral column superior to umbilicus. The stoney fecalith of 2 cm which was found under the leaflet of the transverse mesocolon was surrounded by omentum and intestines creating a mass of almost 10 cm. The fecalith together with the surrounding and necrotizing omentum were resected. The patient was discharged from the hospital on the third postoperative day without any complication.

Conclusion: The fecalith is an incidental finding and not always the primary cause of acute or gangrenous (perforated) appendicitis. Insufflation of carbon dioxide used during laparoscopy could have resulted in the far wandering of the fecalith during the initial surgical intervention in the present case. One should keep in mind that retained appendicoliths after laparoscopic appendectomy might cause some complications which could have been avoided.



International Journal of Case Reports and Images (IJCRI)



International Journal of Case Reports and Images (IJCRI) is an international, peer reviewed, monthly, open access, online journal, publishing high-quality, articles in all areas of basic medical sciences and clinical specialties.

Aim of IJCRI is to encourage the publication of new information by providing a platform for reporting of unique, unusual and rare cases which enhance understanding of disease process, its diagnosis, management and clinico-pathologic correlations.

IJCRI publishes Review Articles, Case Series, Case Reports, Case in Images, Clinical Images and Letters to Editor.

Website: www.ijcasereportsandimages.com

Delayed acute abdomen of a farthest wandering fecalith retained after laparoscopic appendectomy

Ahmet Kocakusak, Mehmet Kulus, Yusuf Emre Altundal

ABSTRACT

Introduction: Retained fecaliths are avoidable complications of laparoscopic appendectomy. We reported herein a case of delayed acute abdomen caused by a far wandering appendicolith retained after laparoscopic appendectomy. **Case Report:** A 24-year-old male who had been operated on because of acute appendicitis in our emergency department 15 days ago, was readmitted with signs and symptoms of acute abdomen. According to his medical history, laparoscopic appendectomy had been converted into open surgery because of perforated appendix and the patient had been discharged from the hospital on the second postoperative day without any complication. Laboratory results were within normal ranges except for the elevated levels of C-reactive protein and leukocyte count. Direct abdominal X-ray, ultrasonography and computed tomography detected a stoney structure of 2 cm surrounded by omentum and intestines at the right side of the vertebral column superior to umbilicus. The stoney fecalith of 2 cm which was found under the leaflet of the transverse mesocolon was surrounded by omentum and intestines creating a mass of

almost 10 cm. The fecalith together with the surrounding and necrotizing omentum were resected. The patient was discharged from the hospital on the third postoperative day without any complication. **Conclusion:** The fecalith is an incidental finding and not always the primary cause of acute or gangrenous (perforated) appendicitis. Insufflation of carbon dioxide used during laparoscopy could have resulted in the far wandering of the fecalith during the initial surgical intervention in the present case. One should keep in mind that retained appendicoliths after laparoscopic appendectomy might cause some complications which could have been avoided.

Keywords: Acute, Appendicitis, Appendicolith, Fecalith, Laparoscopy

How to cite this article

Kocakusak A, Kulus M, Altundal YE. Delayed acute abdomen of a farthest wandering fecalith retained after laparoscopic appendectomy. Int J Case Rep Images 2016;7(12):827–831.

Article ID: Z01201612CR10733AK

doi:10.5348/ijcri-2016145-CR-10733

Ahmet Kocakusak¹, Mehmet Kulus², Yusuf Emre Altundal²

Affiliations: ¹General Surgeon in General Surgery Clinic, Health Ministry Haseki Education and Research State Hospital, Istanbul, Turkey; ²Resident in General Surgery Clinic, Health Ministry Haseki Education and Research State Hospital, Istanbul, Turkey.

Corresponding Author: Ahmet Kocakusak, MD, Semsettin Gunaltay Cad, Medine Apt, No: 197 / 23 Erenkoy, Kadikoy, Istanbul, Turkey; E-mail: ahmetkocakusak@yahoo.com

Received: 13 September 2016

Accepted: 10 May 2016

Published: 01 December 2016

INTRODUCTION

Many patients have revisited emergency department because of abscesses caused by retained fecaliths which had been once appendicoliths according to some

authors [1]. We reported herein a case of delayed acute abdomen of a far wandering appendicolith retained after laparoscopic appendectomy. One can find a wide variation in rates of appendicoliths during appendicitis. Since patients with appendicoliths are usually asymptomatic, appendicoliths are not pathognomonic in acute appendicitis. However, it is also true that appendicoliths can be found with perforation and abscess formation. In fact, appendicoliths are common, being present in 3% of general population and in nearly 10% cases of acute appendicitis. [2, 3].

CASE REPORT

A 24-year-old male patient, who had been operated on because of acute appendicitis in our emergency department 15 days ago, was readmitted to our general surgery department. According to his near medical history; laparoscopic appendectomy had been converted into open surgery because of perforated appendix and the patient had been discharged from the hospital on the second postoperative day without any complication. However, after two weeks; abdominal discomfort resulted in signs and symptoms of acute abdomen. Fever, abdominal guarding and rebound tenderness especially around umbilical region with acute abdomen resulted in re-hospitalization of the patient in our emergency department. Laboratory results were within normal ranges except for the levels of C-reactive protein and leukocyte count, were 95 mg/L and 17300/mm³, respectively. Direct abdominal X-ray (Figure 1), ultrasonography and computed tomography (Figure 2), detected a stoney structure of 2 cm surrounded by omentum and intestines at the right side of the vertebral column superior to umbilicus. Effused areas of small abscesses in addition air bubbles scattered around them throughout the abdomen were also reported. Right paramedian laparotomy exposed small islands of abscesses beginning at the abdominal wall. The stony fecalith of 2 cm was found under the leaflet of the transverse mesocolon (Figure 3) and it was surrounded by omentum and intestines creating a mass of almost 10 cm (Figure 4). The fecalith together with the surrounding and necrotizing omentum were resected (Figure 5). A Jackson-Pratt drain was placed. The patient was discharged from the hospital on the third postoperative day without any complication.

DISCUSSION

According to majority of the related studies, one cannot claim about a relationship between a gangrenous or perforated appendix and causative role of a fecalith. Fecaliths are usually described as incidental findings rather than being a primary cause of the disease [4]. Hence fecaliths are more dangerous when they leave appendix vermiformis. We think that insufflation of carbon dioxide

used in the laparoscopy could have resulted in the far wandering of the fecalith during the initial surgical intervention in the present case. Appendiceal fecaliths may lead to right iliac fossa pain in the absence of obvious appendiceal inflammation. Therefore, even the routine removal of a normal-looking appendix at laparoscopy in

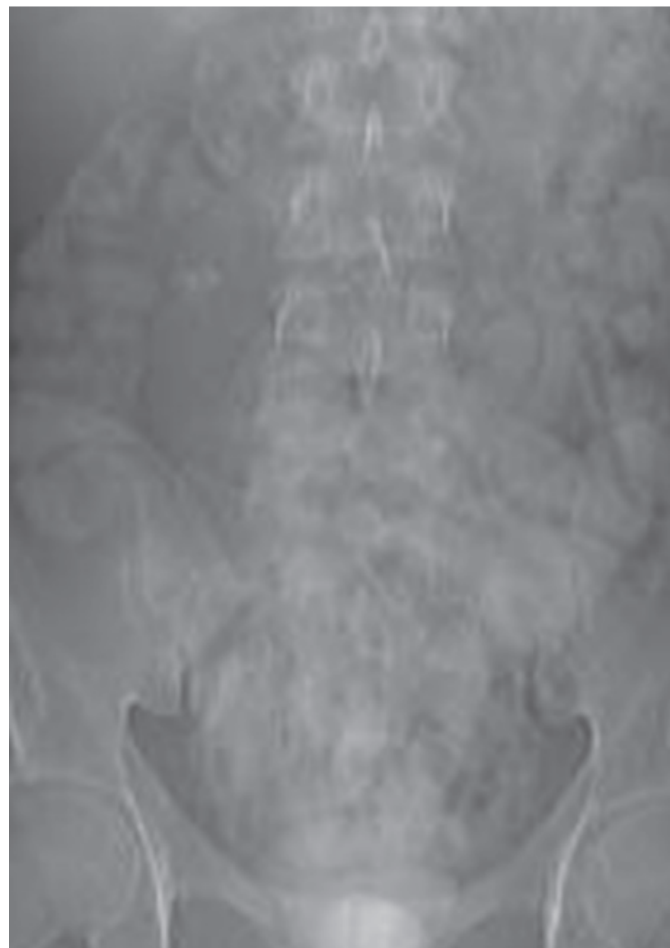

Figure 1: Direct abdominal plain radiography revealed a stoney structure at the right side of the vertebral column.

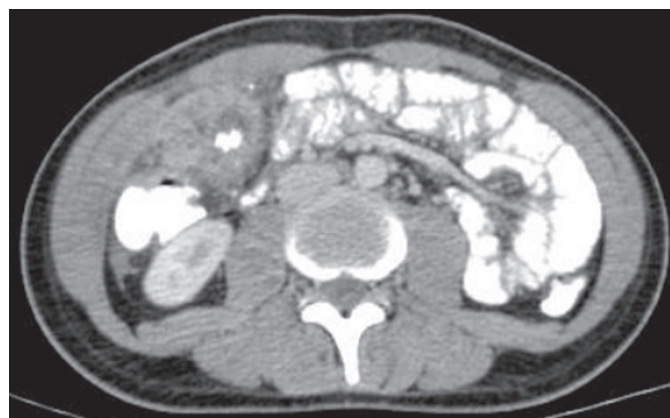

Figure 2: Computed tomography showed that a calcified structure of 2 cm at the right side of the epigastric area had been surrounded by omentum and intestines creating a mass 10 cm.

the absence of any other obvious pathology may be an effective treatment for recurrent symptoms in cases with a fecalith according to some authors [5]. Working as a lymphoid organ or colonic reservoir may also contribute

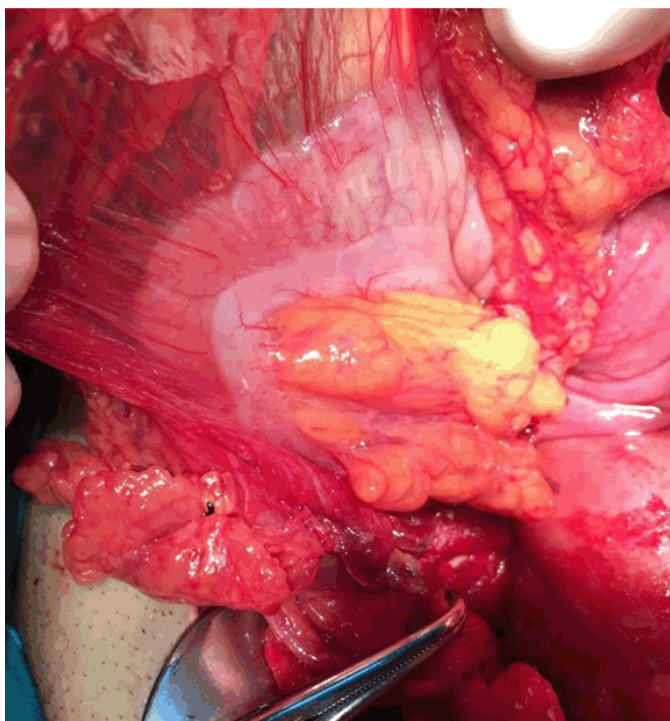


Figure 3: The stoney fecalith of 2 cm was found under the leaflet of the transverse mesocolon.

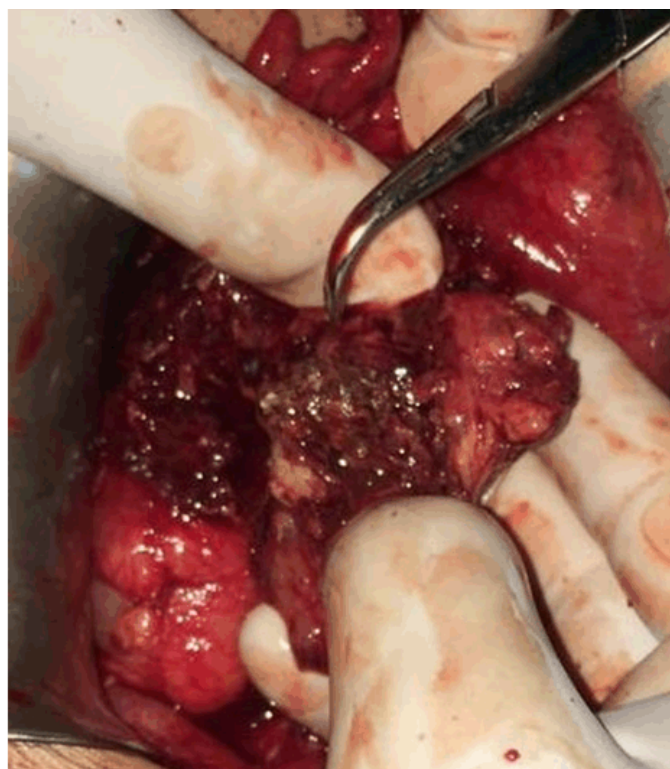

Figure 4: The mass was surrounded by omentum and intestines creating a mass of almost 10 cm.

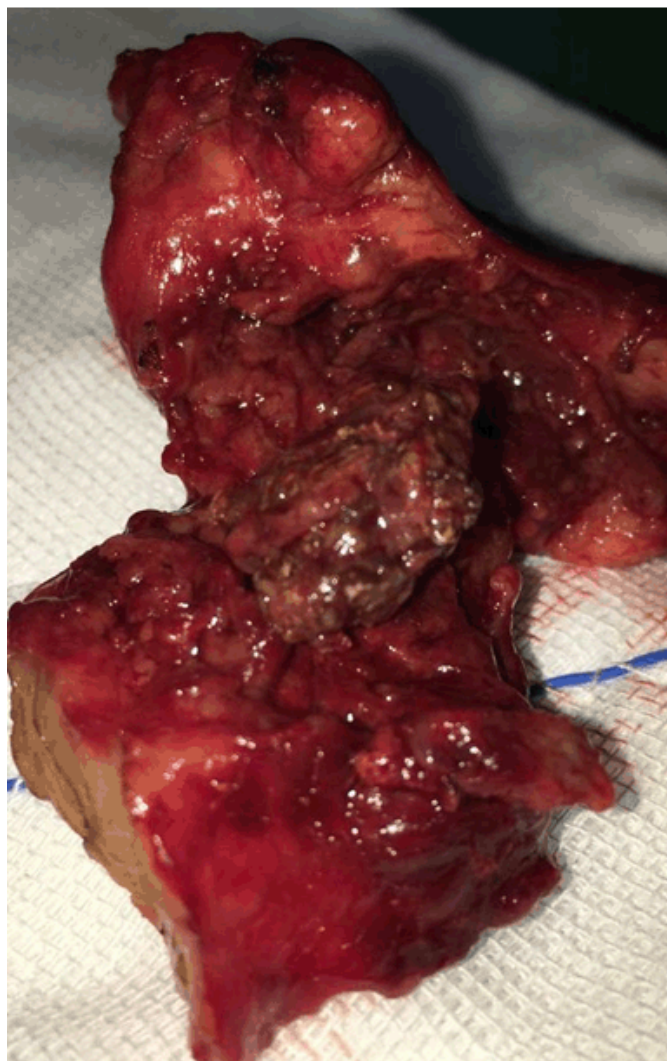


Figure 5: The fecalith together with the surrounding and necrotizing omentum were resected.

to acute appendicitis [6–8]. Interesting foreign bodies in the lumen of the appendix vermiformis [9] as well as eosinophilic appendicitis caused by *Schistosoma japonicum* [10] are all emphasizing that we still see only the tip of the iceberg of a very well-known disease. Acute appendicitis has always been among the most common cause of acute abdomen worldwide since antique times. Challenges in its diagnosis, variable combination of its clinical presentation especially altered by its retrocecal and/or subserosal locations, recommended scoring systems to decrease negative appendectomy rates, role and success of imaging modalities, non-operative treatment facilities, timing of appendectomy, in-hospital delay, appendicitis in pregnant patients, and its incidence which cannot be decreased along with its complications disguise continuous debates. Moreover; percutaneous drainage of a periappendicular abscess in the era of evolved radiological techniques has been another tool in its treatment during the last decades. One should always

keep in mind, that a hidden cecal or appendiceal tumor could be an undesirable concomitant fact with a silent appendiceal phlegmon or mucocele which are very hard to diagnose even with colonoscopy especially in patients in whom physicians recommend interval appendectomy in cases who had been treated medically [11].

CONCLUSION

In conclusion, we shall keep in mind that retained appendicoliths might cause some complications which we could have avoided during the previous surgical intervention.

Author Contributions

Ahmet Kocakusak – Substantial contributions to conception and design, Acquisition of data, Drafting the article, Revising it critically for important intellectual content, Final approval of the version to be published
Mehmet Kulus – Substantial contributions to conception and design, Analysis and interpretation of data, Drafting the article, Final approval of the version to be published
Yusuf Emre Altundal – Substantial contributions to conception and design, Drafting the article, Revising it critically for important intellectual content, Final approval of the version to be published

Guarantor

The corresponding author is the guarantor of submission.

Conflict of Interest

Authors declare no conflict of interest.

Copyright

© 2016 Ahmet Kocakusak et al. This article is distributed under the terms of Creative Commons Attribution License which permits unrestricted use, distribution and reproduction in any medium provided the original author(s) and original publisher are properly credited. Please see the copyright policy on the journal website for more information.

REFERENCES

1. Knight O, Brar R, Clark J. Retained faecolith: An avoidable complication of laparoscopic appendicectomy. *BMJ Case Rep* 2013 Sep 16;2013. pii: bcr2013201255.
2. Singhal S, Singhal A, Mahajan H, et al. Giant appendicolith: Rare finding in a common ailment. *J Minim Access Surg* 2016 Apr-Jun;12(2):170–2.
3. Lovrenski J, Jokic R, Varga I. Sonographically detected free appendicolith as a sign of retrocecal

- perforated appendicitis in a 2-year-old child. *J Clin Ultrasound* 2016 Jul 8;44(6):395–8.
4. Engin O, Muratli A, Ucar AD, Tekin V, Calik B, Tosun A. The importance of fecaliths in the aetiology of acute appendicitis. *Chirurgia (Bucur)* 2012 Nov-Dec;107(6):756–60.
5. Grimes C, Chin D, Bailey C, Gergely S, Harris A. Appendiceal faecaliths are associated with right iliac fossa pain. *Ann R Coll Surg Engl* 2010 Jan;92(1):61–4.
6. Raahave D, Christensen E, Moeller H, Kirkeby LT, Loud FB, Knudsen LL. Origin of acute appendicitis: Fecal retention in colonic reservoirs: A case control study. *Surg Infect (Larchmt)* 2007 Feb;8(1):55–62.
7. Monroe BJ, Williams SJ. A case of appendicitis with appendicolith diagnosed with ultrasound in the emergency department. *J Emerg Med* 2015 Jun;48(6):727–8.
8. Oberhofer E. From fecalith to ileus - what the ultrasound reveals. [Article in German]. *MMW Fortschr Med* 2015 Jul 23;157(13):20–2.
9. van Dijk JH, Vankeirsbilck J, Poelmans S. A rabbit's revenge: shotgun pellet appendicitis. *Acta Chir Belg* 2012 Nov-Dec;112(6):457–9.
10. Kanoksil W, Larbcharoensub N, Soontrapa P, Phongkitkarun S, Sriphojanart S, Nitiyanant P. Eosinophilic appendicitis caused by *Schistosoma japonicum*: A case report and review of the literature. *Southeast Asian J Trop Med Public Health* 2010 Sep;41(5):1065–70.
11. Alvarado A. How to improve the clinical diagnosis of acute appendicitis in resource limited settings. *World J Emerg Surg* 2016 Apr 26;11:16.

Access full text article on
other devices



Access PDF of article on
other devices



Edorium Journals: An introduction

Edorium Journals Team

About Edorium Journals

Edorium Journals is a publisher of high-quality, open access, international scholarly journals covering subjects in basic sciences and clinical specialties and subspecialties.

Invitation for article submission

We sincerely invite you to submit your valuable research for publication to Edorium Journals.

But why should you publish with Edorium Journals?

In less than 10 words - we give you what no one does.

Vision of being the best

We have the vision of making our journals the best and the most authoritative journals in their respective specialties. We are working towards this goal every day of every week of every month of every year.

Exceptional services

We care for you, your work and your time. Our efficient, personalized and courteous services are a testimony to this.

Editorial Review

All manuscripts submitted to Edorium Journals undergo pre-processing review, first editorial review, peer review, second editorial review and finally third editorial review.

Peer Review

All manuscripts submitted to Edorium Journals undergo anonymous, double-blind, external peer review.

Early View version

Early View version of your manuscript will be published in the journal within 72 hours of final acceptance.

Manuscript status

From submission to publication of your article you will get regular updates (minimum six times) about status of your manuscripts directly in your email.

Our Commitment

Six weeks

You will get first decision on your manuscript within six weeks (42 days) of submission. If we fail to honor this by even one day, we will publish your manuscript free of charge.*

Four weeks

After we receive page proofs, your manuscript will be published in the journal within four weeks (31 days). If we fail to honor this by even one day, we will publish your manuscript free of charge and refund you the full article publication charges you paid for your manuscript.*

Favored Author program

One email is all it takes to become our favored author. You will not only get fee waivers but also get information and insights about scholarly publishing.

Institutional Membership program

Join our Institutional Memberships program and help scholars from your institute make their research accessible to all and save thousands of dollars in fees make their research accessible to all.

Our presence

We have some of the best designed publication formats. Our websites are very user friendly and enable you to do your work very easily with no hassle.

Something more...

We request you to have a look at our website to know more about us and our services.

* Terms and condition apply. Please see Edorium Journals website for more information.

We welcome you to interact with us, share with us, join us and of course publish with us.



Edorium Journals: On Web



Browse Journals

CONNECT WITH US

