

Pain in heels: Two cases with piezogenic pedal papules


**Emrullah Hayta, Sibel Berksoy Hayta, Melih Akyol, Ozlem Sahin,
Sedat Ozelik**

ABSTRACT


Introduction: Piezogenic pedal papules (PPP), which are forms of responses to internal mechanical pressure, appear on the wrists and especially on feet. Repeated trauma or an inherent collagen defect mainly as Ehlers–Danlos syndrome can cause pain symptoms in heels. The PPP are mostly asymptomatic and noticed incidentally.

Case Reports: Unlike the majority of PPP cases, two patients (both housewives), who took part in the present study, were older and they had severe pain associated with PPP. One injection of a solution of equal amounts of betamethasone and prilocaine was applied in treatment of pain in both patients.

Conclusion: During follow-ups the patients did not report any clinical complaints considering the PPP and their VAS score remained significantly low.

 All Articles Open Access

International Journal of Case Reports and Images (IJCRI)



International Journal of Case Reports and Images (IJCRI) is an international, peer reviewed, monthly, open access, online journal, publishing high-quality, articles in all areas of basic medical sciences and clinical specialties.

Aim of IJCRI is to encourage the publication of new information by providing a platform for reporting of unique, unusual and rare cases which enhance understanding of disease process, its diagnosis, management and clinico-pathologic correlations.

IJCRI publishes Review Articles, Case Series, Case Reports, Case in Images, Clinical Images and Letters to Editor.

Website: www.ijcasereportsandimages.com

Pain in heels: Two cases with piezogenic pedal papules

Emrullah Hayta, Sibel Berksoy Hayta, Melih Akyol, Ozlem Sahin,
Sedat Ozcelik

ABSTRACT

Introduction: Piezogenic pedal papules (PPP), which are forms of responses to internal mechanical pressure, appear on the wrists and especially on feet. Repeated trauma or an inherent collagen defect mainly as Ehlers–Danlos syndrome can cause pain symptoms in heels. The PPP are mostly asymptomatic and noticed incidentally. **Case Reports:** Unlike the majority of PPP cases, two patients (both housewives), who took part in the present study, were older and they had severe pain associated with PPP. One injection of a solution of equal amounts of betamethasone and prilocaine was applied in treatment of pain in both patients. **Conclusion:** During follow-ups the patients did not report any clinical complaints considering the PPP and their VAS score remained significantly low.

Keywords: Ehlers-Danlos syndrome, Heel pain, Obesity, Piezogenic pedal papules

How to cite this article

Hayta E, Hayta SB, Akyol M, Sahin O, Ozcelik S. Pain in heels: Two cases with piezogenic pedal papules. Int J Case Rep Images 2016;7(2):81–84.

doi:10.5348/ijcri-201603-CS-10064

INTRODUCTION

Piezogenic pedal papules (PPPs), which are forms of responses to internal mechanical pressure and weakness in the connective tissue in the dermis, appear commonly over the medial aspect of the heel, but in some cases on the wrists mostly in bilateral and benign forms. The PPPs, which are typically flesh-colored or yellowish, are thought to represent herniations of adipose tissue through the plantar fascia retinaculum [1, 2].

Piezogenic pedal papules, which range in size from 2 mm to 2 cm, are mostly asymptomatic and noticed incidentally. However, people with repeated trauma or an inherent collagen defect such as Ehlers-Danlos syndrome can experience some pain symptoms. Though PPPs are common in a healthy population, more frequently among healthy adults and children, they may not seek medical treatment as papules seldom show any clinical signs [3–5].

Although in most of the studies in literature, PPP are generally observed in healthy individuals, sportsmen and especially marathon runners, which leads us to consider PPP as among the frictional and mechanical dermatoses related to sports [6, 7], our study focuses on two housewives having a completely different life style in comparison to sportsmen/women.

Unlike the majority of PPP cases, two patients, who took part in the present study, were older and they had severe pain associated with PPP.

Emrullah Hayta¹, Sibel Berksoy Hayta², Melih Akyol³, Ozlem Sahin⁴, Sedat Ozcelik⁵

Affiliations: ¹Assistant Professor, Cumhuriyet University, Faculty of Medicine, Physical Medicine and Rehabilitation, Sivas, Turkey; ²Assistant Professor, Cumhuriyet University, Faculty of Medicine, Department of Dermatology, Sivas, Turkey; ³Professor, Cumhuriyet University, Faculty of Medicine, Department of Dermatology, Sivas, Turkey; ⁴Associate Professor, Cumhuriyet University, Faculty of Medicine, Department of Physical Medicine and Rehabilitation, Sivas, Turkey; ⁵Professor, Cumhuriyet University, Faculty of Medicine, Department of Dermatology, Sivas, Turkey.

Corresponding Author: Emrullah HAYTA, Cumhuriyet University, Faculty of Medicine, Department of Physical Medicine and Rehabilitation, 58141 Sivas / Turkey; E-mail: dremay@gmail.com

Received: 19 June 2015

Accepted: 28 July 2015

Published: 01 February 2016

CASE SERIES

Case 1

A 62-year-old female patient was first seen in the dermatology outpatient clinic for intense pain in the both heels of one week duration, aggravated by standing or walking.

Examination revealed no abnormality except for slight obesity (BMI 29). When she was sitting, the heels appeared normal, but when she stood with dispersing the body weight equally to the foot surface, numerous yellowish round papules appeared on the posterior, medial and lateral aspect of both heels, causing moderate pain in both heels (Figure 1a–b). However, when she stood with full weight on the heels, the number of detectable papules increased almost immediately in parallel with sudden increase in pain, but when she stood on the toes, the papules disappeared gradually and the pain subsided.

Case 2

A 73-year-old female patient was admitted to our clinic with widespread pain, in both the heels for four month duration, aggravated by standing or walking.

Examination revealed no abnormality except for obesity (BMI 35). When she was sitting, the heels appeared normal, but when she stood with dispersing the body weight equally to the foot surface, numerous yellowish round papules appeared on the posterior, medial and lateral aspect of both heels, causing severe pain in both heels (Figure 2a–b).

In both patients, the papules were tender to pressure and differed both in location and in the severity of the pain (VAS score 9) from nodules found in plantar fasciitis. Also, lateral foot X-rays and ultrasonography showed no abnormality in terms of plantar fasciitis and epin calcanei. Two patients were diagnosed with the painful PPP by clinical examination and findings. Other possible factors resulting in heel pain are excluded.

Although the patients were put through electrotherapy for a consecutive ten days period along with some forms of conservative treatments such as regular relaxation, taping or padding the foot by heel cups, almost no significant clinical improvement was recorded (VAS score 8). As a result, one injection of a solution of equal amounts of betamethasone and prilocaine was applied in treatment of pain in both patients (Figure 3). According to the patients' reports, in the clinical evaluation of the patients in the following day, their VAS score were dramatically reduced to 1.

In order to prevent the relapse of the same condition, they were recommended to reduce their body weight, to use heel cups. In their six-months follow-ups, the patients did not report any clinical complaints considering the PPP and their VAS score remained significantly low. Moreover, in the follow-ups of both patients, it was noted that they lost weight, 5.4 and 4.2 kg.

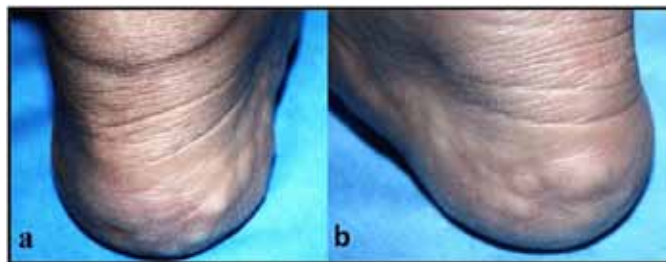


Figure 1: (a, b) Numerous yellowish round papules on the posterior, medial and lateral aspect of both heels.

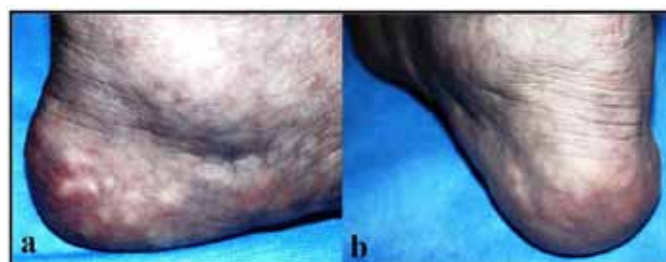


Figure 2: (a, b) Numerous yellowish round papules on the posterior, medial and lateral aspect of both heels.

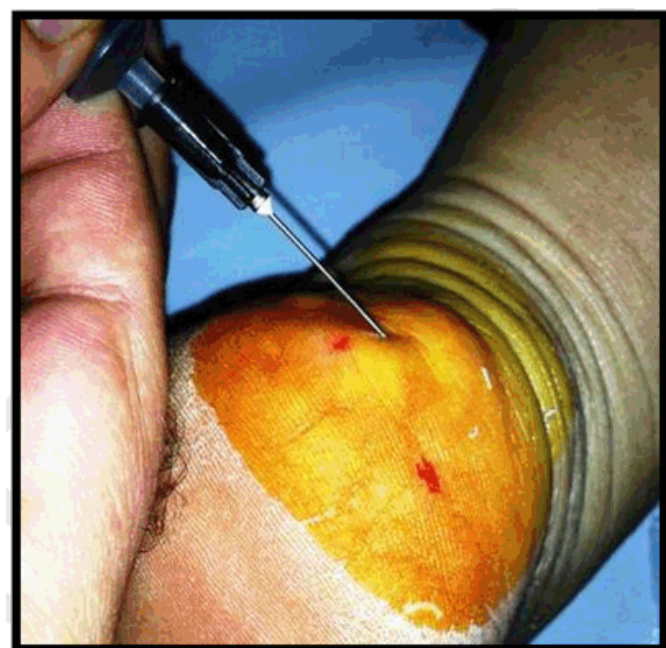


Figure 3: Injections of a solution of equal amount of betamethasone and prilocaine.

DISCUSSION

For the last four decades, although the majority of the reported cases of PPP have focused on healthy children, adults, sportsmen/women, and people with connective tissue disorders such as Ehler–Danlos, as it is in our cases, PPP may also occur in old population resulting not only from prolonged weight-bearing but also from degenerative loss and structural defect of connective tissue. Although there are some studies demonstrating

the link between obesity and PPP, the studies in the related literature are limited [7]. The resulting peripheral fat chambers on the heels may cause pain by triggering ischemia [8]. In old population, the major factor of the heel pain is generally accepted as plantar fasciitis [9]. However, as can be seen in our cases, in old patients with heel pain, PPP can cause severe pain. For this reason, in the diagnosis regarding the causes of the heel pain in old population, PPP may be seen as one of the significant factors.

Because PPP lesions are benign, laboratory evaluation X-rays and ultrasonography might not be necessary. However, these diagnostic tools might be useful only for distinguishing PPP from the causes of other heel pain [10]. In traditional treatment of PPP, there is a range of supportive measures and choices that can range from avoiding prolonged standing, taping or padding the foot by heel cups or orthotics to a series of electro acupuncture treatments, a series of injections of equal amounts betamethasone and bupivacaine at the site. In the non-resolving cases, surgical intervention might be seen as a last choice [11–13].

CONCLUSION

Painful piezogenic pedal papules (PPP) might be considered in differential diagnosis in old patients with no sports background who complain with heel or foot pain, aggravated by long-term standing. The PPP can lead to heel pain in almost all age groups and as its diagnosis is easy, it should be kept in mind as a possibility in patients complaining with heel pain.

Author Contributions

Emrullah Hayta – Substantial contributions to conception and design, Acquisition of data, Analysis and interpretation of data, Drafting the article, Revising it critically for important intellectual content, Final approval of the version to be published

Sibel Berksoy Hayta – Analysis and interpretation of data, Revising it critically for important intellectual content, Final approval of the version to be published

Melih Akyol – Analysis and interpretation of data, Revising it critically for important intellectual content, Final approval of the version to be published

Ozlem Sahin – Analysis and interpretation of data, Revising it critically for important intellectual content, Final approval of the version to be published

Sedat Ozelik – Analysis and interpretation of data, Revising it critically for important intellectual content, Final approval of the version to be published

Guarantor

The corresponding author is the guarantor of submission.

Conflict of Interest

Authors declare no conflict of interest.

Copyright

© 2016 Emrullah Hayta et al. This article is distributed under the terms of Creative Commons Attribution License which permits unrestricted use, distribution and reproduction in any medium provided the original author(s) and original publisher are properly credited. Please see the copyright policy on the journal website for more information.

REFERENCES

1. Singh SK, Tehseen M, Kalam A. Painless piezogenic pedal papules in a patient with rheumatic heart disease. *Indian J Dermatol Venereol Leprol* 2002 Mar-Apr;68(2):107–8.
2. Laing VB, Fleischer AB Jr. Piezogenic wrist papules: a common and asymptomatic finding. *J Am Acad Dermatol* 1991 Mar;24(3):415–7.
3. Graham BS, Barrett TL. Solitary painful piezogenic pedal papule. *J Am Acad Dermatol* 1997 May;36(5 Pt 1):780–1.
4. Montgomery F, Fioriti A. Piezogenic pedal papules: Treated by resection and hernial closure. *The Foot* 1998;8:171–2.
5. Gibney MD, Glaser DA. Piezogenic pedal papules in two family members. *Cutis* 1996 Apr;57(4):260–2.
6. Karadag AS, Bilgili SG, Guner S, Yilmaz D. A cases series of Piezogenic pedal papules. *Indian Dermatol Online J* 2013 Oct;4(4):369–71.
7. Schepis C, Greco D, Siragusa M, Romano C. Piezogenic pedal papules during Prader-Willi syndrome. *J Eur Acad Dermatol Venereol* 2005 Jan;19(1):136–7.
8. Tlougan BE, Mancini AJ, Mandell JA, Cohen DE, Sanchez MR. Skin conditions in figure skaters, ice-hockey players and speed skaters: part I - mechanical dermatoses. *Sports Med* 2011 Sep 1;41(9):709–19.
9. Redbord KP, Adams BB. Piezogenic pedal papules in a marathon runner. *Clin J Sport Med* 2006 Jan;16(1):81–3.
10. Cho SB, Ha HI, Kang TW, Chung KY. Ultrasonographic assessment of piezogenic pedal papules. *Clin Exp Dermatol* 2009 Oct;34(7):e325–6.
11. Anderson J, Stanek J. Effect of foot orthoses as treatment for plantar fasciitis or heel pain. *J Sport Rehabil* 2013 May;22(2):130–6.
12. Woodrow SL, Brereton-Smith G, Handfield-Jones S. Painful piezogenic pedal papules: response to local electro-acupuncture. *Br J Dermatol* 1997 Apr;136(4):628–30.
13. Doukas DJ, Holmes J, Leonard JA. A nonsurgical approach to painful piezogenic pedal papules. *Cutis* 2004 May;73(5):339–40, 346.

Access full text article on
other devices



Access PDF of article on
other devices



Edorium Journals: An introduction

Edorium Journals Team

About Edorium Journals

Edorium Journals is a publisher of high-quality, open access, international scholarly journals covering subjects in basic sciences and clinical specialties and subspecialties.

Invitation for article submission

We sincerely invite you to submit your valuable research for publication to Edorium Journals.

But why should you publish with Edorium Journals?

In less than 10 words - we give you what no one does.

Vision of being the best

We have the vision of making our journals the best and the most authoritative journals in their respective specialties. We are working towards this goal every day of every week of every month of every year.

Exceptional services

We care for you, your work and your time. Our efficient, personalized and courteous services are a testimony to this.

Editorial Review

All manuscripts submitted to Edorium Journals undergo pre-processing review, first editorial review, peer review, second editorial review and finally third editorial review.

Peer Review

All manuscripts submitted to Edorium Journals undergo anonymous, double-blind, external peer review.

Early View version

Early View version of your manuscript will be published in the journal within 72 hours of final acceptance.

Manuscript status

From submission to publication of your article you will get regular updates (minimum six times) about status of your manuscripts directly in your email.

Our Commitment

Six weeks

You will get first decision on your manuscript within six weeks (42 days) of submission. If we fail to honor this by even one day, we will publish your manuscript free of charge.

Four weeks

After we receive page proofs, your manuscript will be published in the journal within four weeks (31 days). If we fail to honor this by even one day, we will publish your manuscript free of charge and refund you the full article publication charges you paid for your manuscript.

Most Favored Author program

Join this program and publish any number of articles free of charge for one to five years.

Favored Author program

One email is all it takes to become our favored author. You will not only get fee waivers but also get information and insights about scholarly publishing.

Institutional Membership program

Join our Institutional Memberships program and help scholars from your institute make their research accessible to all and save thousands of dollars in fees make their research accessible to all.

Our presence

We have some of the best designed publication formats. Our websites are very user friendly and enable you to do your work very easily with no hassle.

Something more...

We request you to have a look at our website to know more about us and our services.

We welcome you to interact with us, share with us, join us and of course publish with us.



Edorium Journals: On Web



Browse Journals

CONNECT WITH US

