

# Tetraplegia developing with skull traction in patients with ankylosing spondylitis (AS): A case report

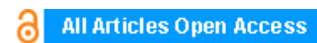**Emrullah Hayta, Ahmet Karadağ, Cesur Gumus**

## ABSTRACT


**Introduction:** Traffic accidents appear to be one of the frequently encountered causes of spinal cord injury (SPI) in patients with ankylosing spondylitis. The risk of spinal cord injury is 11.4 times higher in patients with AS compared to the healthy population. Although the fractures might be seen in any part of the spine, they most frequently occur in cervical region.

**Case Report:** Our subject in this case is a 62-year-old patient diagnosed with AS who had isolated muscle strength loss following a traffic accident. The patient was provided skull traction treatment having sustained a fracture in his C7 in a traffic accident, and he developed tetraplegia as a result.

**Conclusion:** Our objective with this case report is to emphasize that stress loading treatment methods such as skull traction which apply force to bone in fractures arising from traumas in patients with AS could lead to extremely severe neurological injuries.



## International Journal of Case Reports and Images (IJCRI)



International Journal of Case Reports and Images (IJCRI) is an international, peer reviewed, monthly, open access, online journal, publishing high-quality, articles in all areas of basic medical sciences and clinical specialties.

Aim of IJCRI is to encourage the publication of new information by providing a platform for reporting of unique, unusual and rare cases which enhance understanding of disease process, its diagnosis, management and clinico-pathologic correlations.

IJCRI publishes Review Articles, Case Series, Case Reports, Case in Images, Clinical Images and Letters to Editor.

**Website: [www.ijcasereportsandimages.com](http://www.ijcasereportsandimages.com)**

# Tetraplegia developing with skull traction in patients with ankylosing spondylitis (AS): A case report

Emrullah Hayta, Ahmet Karadağ, Cesur Gumus

## ABSTRACT

**Introduction:** Traffic accidents appear to be one of the frequently encountered causes of spinal cord injury (SCI) in patients with ankylosing spondylitis. The risk of spinal cord injury is 11.4 times higher in patients with AS compared to the healthy population. Although the fractures might be seen in any part of the spine, they most frequently occur in cervical region. **Case Report:** Our subject in this case is a 62-year-old patient diagnosed with AS who had isolated muscle strength loss following a traffic accident. The patient was provided skull traction treatment having sustained a fracture in his C7 in a traffic accident, and he developed tetraplegia as a result. **Conclusion:** Our objective with this case report is to emphasize that stress loading treatment methods such as skull traction which apply force to bone in fractures arising from traumas in patients with AS could lead to extremely severe neurological injuries.

**Keywords:** Ankylosing spondylitis, Rehabilitation, Skull traction, Spinal cord injury

## How to cite this article

Hayta E, Karadağ A, Gumus C. Tetraplegia developing with skull traction in patients with ankylosing spondylitis: A case report. Int J Case Rep Images 2016;7(2):111–114.

doi:10.5348/ijcri-201617-CR-10604

## INTRODUCTION

Ankylosing spondylitis (AS) is a chronic inflammatory disease characterized by enthesitis which specifically holds on sacroiliac joints, axial skeleton and sometimes on peripheral joints [1]. As a result of secondary osteoporosis and rigid spine with reduced mobility occurring in AS, the spine loses its elasticity and ability to counter impacts. Even the smallest load might easily lead to fractures in spine. The fact that pathology in cervical vertebrae might not be detected in conventional radiological examination might result in delayed diagnosis [2, 3].

In this case report, we present a subject with AS who sustained spinal cord injury (SCI) following skull traction implementation conducted due to cervical spinal cord injury in a traffic accident in a car. Our objective is to underline that stress loading treatment methods such as skull traction which apply force to bone in neurological complications arising from simple traumas in patients with AS might lead to extremely severe neurological injuries.

## CASE REPORT

A 62-year old patient was admitted to our clinic complaining about walking problems and weakness in fingers of both hands. The patient history showed that he had been diagnosed with AS around 30 years ago, and

Emrullah Hayta<sup>1</sup>, Ahmet Karadağ<sup>1</sup>, Cesur Gumus<sup>2</sup>

**Affiliations:** <sup>1</sup>Assistant Professor, Cumhuriyet University, Faculty of Medicine, Department of Physical Medicine and Rehabilitation, Sivas, Turkey; <sup>2</sup>Professor, Cumhuriyet University, Faculty of Medicine, Department of Radiology, Sivas, Turkey.

**Corresponding Author:** Emrullah Hayta, Cumhuriyet University, Faculty of Medicine, Department of Physical Medicine and Rehabilitation 58141 Sivas / Turkey; E-mail: dremay@gmail.com

Received: 15 September 2015

Accepted: 20 November 2015

Published: 01 February 2016

used sulfasalazine and non-steroidal anti-inflammatory drugs due to this diagnosis. He had been admitted to hospital complaining about weakness in his right hand fingers resulting from a car accident. Computed tomography (CT) scan conducted in neurosurgery service showed a fracture in his C6-C7 vertebral corpus, posterior subluxation of C7 corpus and line in his spinous process C6, and he was recommended hospitalization for a clinical monitoring (Figure 1).

On his second day in the hospital, he received a skull traction application for two hours after which a halo orthosis was mounted on him. Immediately after skull traction, the patient developed weakness (tetraplegia) in fingers of both extremities and bilateral lower extremities. Our clinic recommended consultation for the patient whose musculoskeletal examination showed anteflexion deformity in his cervical spine and thoracic kyphosis. The patient had 2.5 cm of thoracic expansion. Muscle strength examination showed that his right finger flexion was 2/5, and left finger flexion was 3/5, and finger abduction on the right was 2/5, and finger abduction on the left was 4/5, and bilateral lower extremity had the strength of 0/5. Sensory examination showed that left T4 had hypoesthesia starting from right T6, and anal sensation was positive. The patient did not have urinary or fecal incontinence. He had radiological level C/7, and his neurological level and C/7 functional independence measure (FIM) score was 55. Magnetic resonance imaging (MRI) scan of the patient indicated non-displaced fracture line in his vertebral corpus C7, and a non-displaced fracture line in his spinous process C6, and non-displaced fracture line in his vertebral facet joint level, spinal cord compression and edema signal (Figure 2). The patient was diagnosed with ASIA-B according to deformity scale by American Spinal Cord Injury Association (ASIA) as a result of the examination and radiological visualization. His neck was immobilized with a halo orthosis throughout his stay in the clinic. He was implemented tilt-table procedure in the acute period. As a part of rehabilitation program, we started to give the patient whole body range of motion exercises, exercises strengthening upper extremity, exercises for improving hand functions, stretching spastic muscles and medical treatment, and pulmonary rehabilitation program treatment. The patient did not have any secondary problem during his stay in our clinic. The last examination of the patient after his seven-month rehabilitation program in our clinic showed that his upper extremity muscle strength was 5/5, and bilateral hip flexors were 5/5, and bilateral knee flexors were 3/5, and bilateral feet dorsiflexors were 5/5, and extensor hallucis longus was 5/5 on the right and 4/5 on the left, and bilateral foot plantar flexors were 5/5. In the lower extremity, hip adductors had bilateral grade II spasticity, and hip flexors had grade II spasticity, and knee flexors had grade I spasticity, and Achilles tendon had bilateral grade II spasticity. Having been advised about requirements of his social life along with training about balance coordination, the patient was discharged with SPI ASIA D diagnosis.

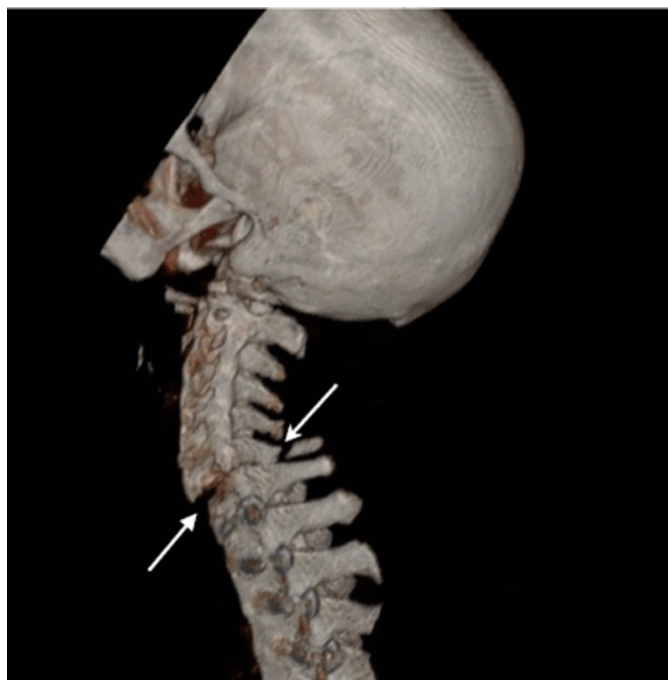

Figure 1: Computed tomography scan showed a fracture in C6-C7 vertebral corpus, posterior subluxation of C7 corpus and line in spinous process C6.

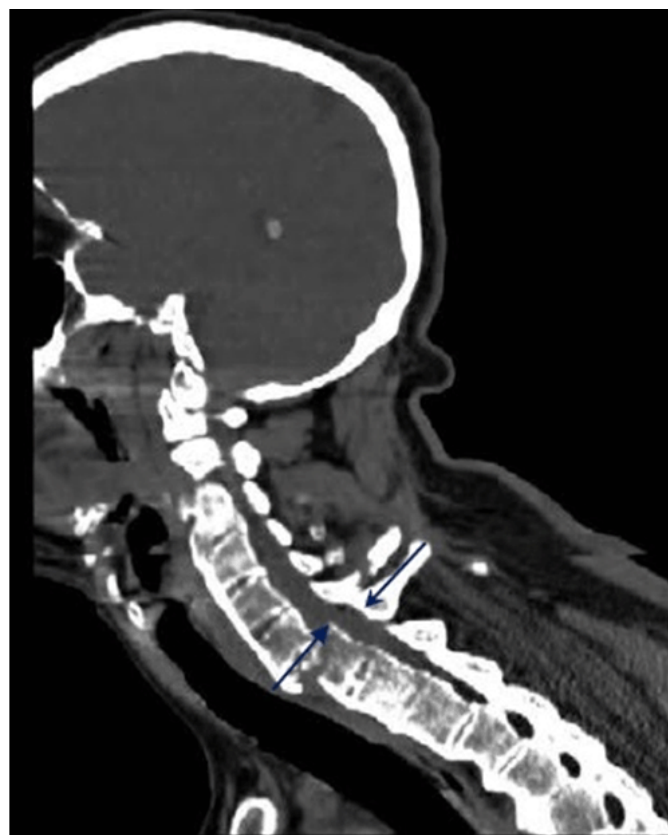

Figure 2: Magnetic resonance imaging (MRI) of the patient indicated non-displaced fracture line in vertebral corpus C7, and a non-displaced fracture line in spinous process C6, and non-displaced fracture line in vertebral facet joint level, spinal cord compression and edema signal.

## DISCUSSION

We have presented this case in order to increase the awareness about being more careful against the risk of increased fractures in the spine of patients with AS when scheduling their fracture treatment in response to spinal injury resulting from trauma. Skull traction on 62-year-old patient with a 30-year history of AS diagnosis with isolated muscle strength loss following a traffic accident developed tetraplegia as a result of skull traction implementation after fracture.

As the period of illness increases in patients with AS, compression-associated complications such as instability in spine, fractures, inflammation, posterior longitudinal ligament ossification, disc lesions and spinal stenosis might develop [4]. Clinical studies have shown that the risk of spinal cord injury is 11.4 times higher in patients with AS compared to the healthy population, and that fractures most frequently occur in cervical region despite the fact that they might occur in any part of the spine as well [5]. Cervical spine fracture is a serious life-threatening complication. The fracture might occur in any level of the spine, yet it is reported that it is particularly more frequent between cervical vertebrae [6]. The reason behind this is that osteoporosis which develops secondary to AS causes the spine to fail to absorb the energy of trauma leading to an intense buckling in the spine acting as a long lever arm [7]. Alaranta et al. reported that cervical spine injury in patients with ankylosing spondylitis is 17 times higher compared to the overall population [8].

The most widespread reason of SCI in patients with AS is falling. Patients with ankylosing spondylitis fall due to reasons such as deformation of their biomechanics, bad posture caused by vertebra loss, and displacement of balance center [9]. Another significant reason for SCI in patients with AS is traffic accident. Flexion injury in patients with AS causes fractures in vertebral bodies, while hyperextension injuries cause fractures penetrating into intervertebral discs [10]. Fractures in patients with AS occur, as the case with our subject, following hyperextension. Since spine elasticity is deformed in patients with AS, fractures such as burst fracture and compression fracture are rather rare [11].

Making a diagnosis based on direct radiographs in patients with AS, where minor trauma is present, might lead to wrong or delayed diagnosis due to the difficulty of visualizing lower cervical spinal cord and cervicothoracic junction, and due to the fact that ossified spinous ligaments deforms normal anatomy [12, 13]. CT and MRI scans are two of the appropriate diagnostic visualization options in patients with AS. Wrong choice of visualization method in diagnosis of fracture develop as a result of minor trauma in patients with AS doubles the risk of SCI [12].

Where there is suspicion of cervical injury in patients with AS, the neck must not be moved, and particularly collar and sand bags which force the neck to extension must not be used. Where there is suspicion of cervical

fracture in patients with AS, first aid team should take measures ensuring positioning of the neck in slight flexion. Particular care must be exercised in visualization methods such as CT and MRI scans which forces the neck to hyperextension. As, extension positions might cause increase in neurological deficit [14]. As the case with our subject, implementing skull traction in these patients causes extension of vertebra applying a force on the vertebra similar to lever arm, leading to reduction of vertebral flexibility. This was a reason behind the patient's developing SCI similar to osteotomy in his cervical vertebra.

Medical methods for treatment of vertebral fractures in patients with AS range from surgical fusion to protective halo use. A study comparing medical methods for vertebral fractures in patients with AS found no difference in terms of neurological and functional outcomes. Apple et al. reported in their study that hospital stay in patients who received non-surgical techniques for treatment of vertebral fractures was shorter.

## CONCLUSION

The way first aid team responds to patients with ankylosing spondylitis (AS) when they experience a trauma, and choice of radiological imaging, forcing to hyperextension during radiological visualization or factors which increase the load on bone, such as skull traction, during medical treatment increase neurological loss in these patients. The way to protect patients with AS against spinal cord injury is obtaining a detailed patient history, and requiring patients to wear medical tag, and creating awareness among first aid and radiology teams, and avoiding all practices which force these patients to hyperextension in any stage of medical intervention.

\*\*\*\*\*

## Author Contributions

Emrullah Hayta – Substantial contributions to conception and design, Acquisition of data, Analysis and interpretation of data, Drafting the article, Revising it critically for important intellectual content, Final approval of the version to be published

Ahmet Karadağ – Analysis and interpretation of data, Revising it critically for important intellectual content, Final approval of the version to be published

Cesur Gümüş – Analysis and interpretation of data, Revising it critically for important intellectual content, Final approval of the version to be published

## Guarantor

The corresponding author is the guarantor of submission.

## Conflict of Interest

Authors declare no conflict of interest.



## Copyright

© 2016 Emrullah Hayta et al. This article is distributed under the terms of Creative Commons Attribution License which permits unrestricted use, distribution and reproduction in any medium provided the original author(s) and original publisher are properly credited. Please see the copyright policy on the journal website for more information.

## REFERENCES

1. Van der Linden. Ankylosing spondylitis. In: Kelley WN, Harris ED, Ruddy S, Sledge CB eds. Textbook of Rheumatology. Philadelphia: WB Saunders Company; 1997. p. 969–82.
2. Prieto-Alhambra D, Muñoz-Ortego J, De Vries F, et al. Ankylosing spondylitis confers substantially increased risk of clinical spine fractures: a nationwide case-control study. *Osteoporos Int* 2015 Jan;26(1):85–91.
3. Gilard V, Curey S, Derrey S, Perez A, Proust F. Cervical spine fractures in patients with ankylosing spondylitis: Importance of early management. *Neurochirurgie* 2014 Oct;60(5):239–43.
4. Alaranta H, Luoto S, Konttinen YT. Traumatic spinal cord injury as a complication to ankylosing spondylitis. An extended report. *Clin Exp Rheumatol* 2002 Jan-Feb;20(1):66–8.
5. Thumbikat P, Hariharan RP, Ravichandran G, McClelland MR, Mathew KM. Spinal cord injury in patients with ankylosing spondylitis: a 10-year review. *Spine (Phila Pa 1976)* 2007 Dec 15;32(26):2989–95.
6. Ruf M, Rehm S, Poeckler-Schoeniger C, Merk HR, Harms J. Iatrogenic fractures in ankylosing spondylitis--a report of two cases. *Eur Spine J* 2006 Jan;15(1):100–4.
7. Alaranta H, Luoto S, Konttinen YT. Traumatic spinal cord injury as a complication to ankylosing spondylitis. An extended report. *Clin Exp Rheumatol* 2002 Jan-Feb;20(1):66–8.
8. Bot SD, Caspers M, Van Royen BJ, Toussaint HM, Kingma I. Biomechanical analysis of posture in patients with spinal kyphosis due to ankylosing spondylitis: a pilot study. *Rheumatology (Oxford)* 1999 May;38(5):441–3.
9. Kewalramani LS, Taylor RG, Albrand OW. Cervical spine injury in patients with ankylosing spondylitis. *J Trauma* 1975 Oct;15(10):931–4.
10. Iplikcioglu AC, Bayar MA, Kökes F, Gökçek C, Doganay OS. Magnetic resonance imaging in cervical trauma associated with ankylosing spondylitis: report of two cases. *J Trauma* 1994 Mar;36(3):412–3.
11. Einsiedel T, Schmelz A, Arand M, et al. Injuries of the cervical spine in patients with ankylosing spondylitis: experience at two trauma centers. *J Neurosurg Spine* 2006 Jul;5(1):33–45.
12. Berne JD, Velmahos GC, El-Tawil Q, et al. Value of complete cervical helical computed tomographic scanning in identifying cervical spine injury in the unevaluable blunt trauma patient with multiple injuries: a prospective study. *J Trauma* 1999 Nov;47(5):896–902; discussion 902–3.
13. Papadopoulos MC, Chakraborty A, Waldron G, Bell BA. Lesson of the week: exacerbating cervical spine injury by applying a hard collar. *BMJ* 1999 Jul 17;319(7203):171–2.
14. Apple DF Jr, Anson C. Spinal cord injury occurring in patients with ankylosing spondylitis: a multicenter study. *Orthopedics* 1995 Oct;18(10):1005–11.

Access full text article on  
other devices



Access PDF of article on  
other devices



## Edorium Journals: An introduction

Edorium Journals Team

### About Edorium Journals

Edorium Journals is a publisher of high-quality, open access, international scholarly journals covering subjects in basic sciences and clinical specialties and subspecialties.

#### Invitation for article submission

We sincerely invite you to submit your valuable research for publication to Edorium Journals.

### But why should you publish with Edorium Journals?

In less than 10 words - we give you what no one does.

#### Vision of being the best

We have the vision of making our journals the best and the most authoritative journals in their respective specialties. We are working towards this goal every day of every week of every month of every year.

#### Exceptional services

We care for you, your work and your time. Our efficient, personalized and courteous services are a testimony to this.

#### Editorial Review

All manuscripts submitted to Edorium Journals undergo pre-processing review, first editorial review, peer review, second editorial review and finally third editorial review.

#### Peer Review

All manuscripts submitted to Edorium Journals undergo anonymous, double-blind, external peer review.

#### Early View version

Early View version of your manuscript will be published in the journal within 72 hours of final acceptance.

#### Manuscript status

From submission to publication of your article you will get regular updates (minimum six times) about status of your manuscripts directly in your email.

### Our Commitment

#### Six weeks

You will get first decision on your manuscript within six weeks (42 days) of submission. If we fail to honor this by even one day, we will publish your manuscript free of charge.

#### Four weeks

After we receive page proofs, your manuscript will be published in the journal within four weeks (31 days). If we fail to honor this by even one day, we will publish your manuscript free of charge and refund you the full article publication charges you paid for your manuscript.

### Most Favored Author program

Join this program and publish any number of articles free of charge for one to five years.

### Favored Author program

One email is all it takes to become our favored author. You will not only get fee waivers but also get information and insights about scholarly publishing.

### Institutional Membership program

Join our Institutional Memberships program and help scholars from your institute make their research accessible to all and save thousands of dollars in fees make their research accessible to all.

### Our presence

We have some of the best designed publication formats. Our websites are very user friendly and enable you to do your work very easily with no hassle.

### Something more...

We request you to have a look at our website to know more about us and our services.

We welcome you to interact with us, share with us, join us and of course publish with us.



Edorium Journals: On Web



Browse Journals

CONNECT WITH US

