

## Bipartite patella separation with quadriceps tendon avulsion: A rare surgical case

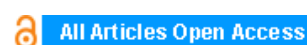**Hasan Raza Mohammad, S Bitar, I Mc Laughlin-Symon, A Henry, G Batra**

### ABSTRACT

**Introduction:** The occurrence of bipartite patellar disruption simultaneously with quadriceps tendon avulsion is an extremely rare injury. A literature review found three documented cases in which only two repaired both the patella and tendon. We present a case report outlining this unusual injury and propose a method of surgical treatment.

**Case Report:** A 45-year-old male presented following a fall directly onto his knee, with no significant medical history or previous injury. He was diagnosed with both separation of a type III bipartite patella and a clinical suspicion of a quadriceps tendon rupture. Intra-operatively, we found a complete tear of the quadriceps tendon at its insertion to the patella with disruption of the synchondrosis and significant separation of the bipartite patella. The displaced fragment was reduced and held using two cannulated screws, the quadriceps tendon was reattached to the superior pole of the patella using two anchor sutures and the retinaculum repaired.

**Conclusion:** We could find no documented cases of using both cannulated screws and anchor sutures as a fixation method for this injury. We recommend this technique as we found that it gave a stronger fixation and was associated with a good functional outcome for our patient.



## International Journal of Case Reports and Images (IJCRI)



International Journal of Case Reports and Images (IJCRI) is an international, peer reviewed, monthly, open access, online journal, publishing high-quality, articles in all areas of basic medical sciences and clinical specialties.

Aim of IJCRI is to encourage the publication of new information by providing a platform for reporting of unique, unusual and rare cases which enhance understanding of disease process, its diagnosis, management and clinico-pathologic correlations.

IJCRI publishes Review Articles, Case Series, Case Reports, Case in Images, Clinical Images and Letters to Editor.

**Website: [www.ijcasereportsandimages.com](http://www.ijcasereportsandimages.com)**

CASE REPORT

OPEN ACCESS

# Bipartite patella separation with quadriceps tendon avulsion: A rare surgical case

Hasan Raza Mohammad, S Bitar, I Mc Laughlin-Symon, A Henry, G Batra

## ABSTRACT

**Introduction:** The occurrence of bipartite patellar disruption simultaneously with quadriceps tendon avulsion is an extremely rare injury. A literature review found three documented cases in which only two repaired both the patella and tendon. We present a case report outlining this unusual injury and propose a method of surgical treatment. **Case Report:** A 45-year-old male presented following a fall directly onto his knee, with no significant medical history or previous injury. He was diagnosed with both separation of a type III bipartite patella and a clinical suspicion of a quadriceps tendon rupture. Intra-operatively, we found a complete tear of the quadriceps tendon at its insertion to the patella with disruption of the synchondrosis and significant separation of the bipartite patella. The displaced fragment was reduced and held using two cannulated screws, the quadriceps tendon was reattached to the superior pole of the patella using two anchor sutures and the retinaculum repaired.

**Conclusion:** We could find no documented cases of using both cannulated screws and anchor sutures as a fixation method for this injury. We recommend this technique as we found that it gave a stronger fixation and was associated with a good functional outcome for our patient.

**Keywords:** Bipartite patella, Quadriceps avulsion, Surgical repair.

### How to cite this article

Mohammad HR, Bitar S, Laughlin-Symon IM, Henry A, Batra G. Bipartite patella separation with quadriceps tendon avulsion: A rare surgical case. *International Journal of Case Reports and Images* 2014;5(2):155–159.

doi:10.5348/ijcri-2014-02-462-CR-14

Hasan Raza Mohammad<sup>1</sup>, S Bitar<sup>2</sup>, I Mc Laughlin-Symon<sup>3</sup>, A Henry<sup>4</sup>, G Batra<sup>5</sup>

**Affiliations:** <sup>1</sup>MRes Medical Student, Orthopedics Department, Salford Royal Foundation Trust; <sup>2</sup>MD, MRCSEd Senior Fellow in Trauma and Orthopedics, Orthopedics Department, Salford Royal Foundation Trust; <sup>3</sup>MRCSEd Fellow in Trauma and Orthopedics, Orthopedic department, Salford Royal Foundation Trust; <sup>4</sup>FRCS(Orth), FRCS(Glas), M.Ch.Orth Consultant Orthopedic Surgeon, Trauma Unit, Salford Royal Foundation Trust; <sup>5</sup>FRCS (Tr and Orth) Consultant Trauma and Orthopedic Surgeon, Orthopedics Department, Salford Royal Foundation Trust.

**Corresponding Author:** Hasan Raza Mohammad, 304 Brooklands Road, Sale, Cheshire, M23 9HB; Ph: 07841873244, Fax: N/A; Email: hasan.mohammad@postgrad.manchester.ac.uk

Received: 20 September 2013

Accepted: 18 October 2013

Published: 01 February 2014

## INTRODUCTION

The occurrence of bipartite patellar disruption simultaneously with quadriceps tendon avulsion is an extremely rare injury which is often misdiagnosed as a patellar avulsion fracture. We present our case of bipartite patellar disruption and quadriceps avulsion which we treated in our institution with open reduction and internal fixation of the bipartite component and anchor repair of the tendon component.

## CASE REPORT

A 45-year-old male, fence erector (weight: 108 kg, height: 178 cm) presented to Accident and Emergency Department after slipping on a mat and impacting his left knee on a concrete step. He had no significant medical history. His main complaints were anterior knee pain, swelling and inability to weight bear. He scored 5/10

for both subjective and objective pain scores. It was an isolated injury and on examination, his knee injury was closed. The knee was significantly swollen and tender, more so over the pre-patellar and supra-patellar regions. The patient was able to actively flex his knee but could not demonstrate straight leg raise. However, any movement was very painful, (scored 3 on the baseline score admission on moving). Left hip and ankle examination were normal and no neurological abnormalities were detected. The patient received 60 mg codeine phosphate, 1 g paracetamol and 400 mg ibuprofen orally as pain relief.

Anterior posterior and lateral radiographs of his left knee were obtained and these showed a superolateral patellar bipartite fracture (Figure 1A–B). The patient denied having any injury to his patella prior to the

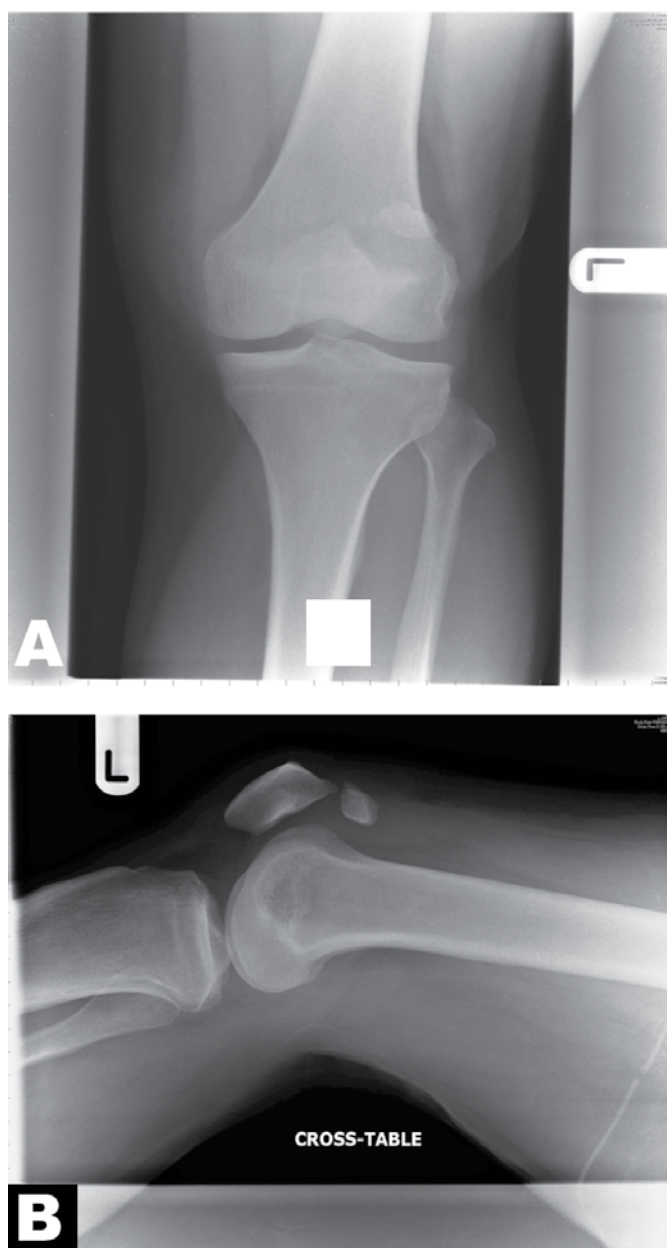


Figure 1: (A) Antero-posterior radiograph of left knee. Indicates superolateral patellar bipartite separation, (B) Lateral radiograph of left knee showing the bipartite separation.

incident. The patient was diagnosed with quadriceps tendon avulsion and bipartite patella through clinical examination and radiographic evidence.

Operative treatment was discussed with the patient and informed consent was obtained. The patient was treated surgically under general anaesthetic in the supine position. Tourniquet was used for 90 minutes during the operation. A longitudinal midline incision approach was used. Operative findings included a complete tear of quadriceps tendon at its insertion to the patella with disruption of the bipartite patella which had displaced a result of the injury (Figure 2). The displaced fragment of the bipartite patella was judged to be significant in size therefore reduced to its anatomical position and internally fixed to the main patellar fragment using two 4.0 mm ASNIS screws under direct intraoperative X-ray control (Figure 3). The distal quadriceps tendon then was repaired into the superior pole of patella using two 5.0 mm Miteck anchors. Repair of the retinaculum on the sides was completed using 2.0 Vicryl. The wound was closed in layers with Vicryl and Monocryl with the knee in slight flexion. The knee was then placed into a cylinder splint and he was scheduled to a follow-up clinic. Meanwhile he was encouraged to do range of motion ankle exercises.

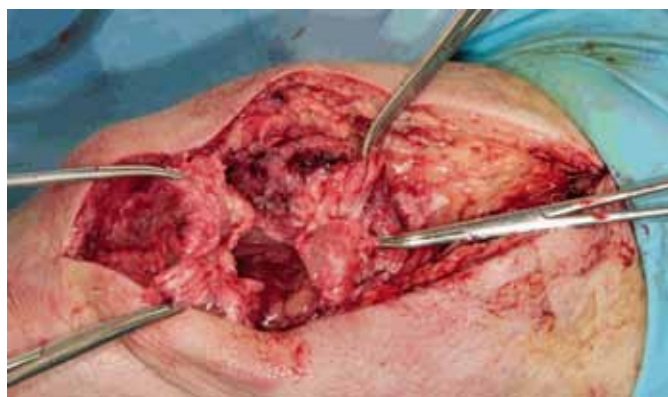

Figure 2: Intraoperative photo of left knee showing the complete tear of quadriceps tendon at its insertion to the patella along with disrupted, displaced bipartite patella.

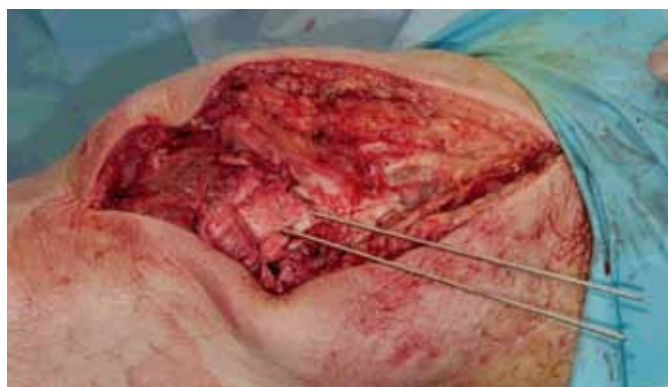

Figure 3: Intraoperative photo of left knee showing reduction of displaced fragment of bipartite patella to its anatomical position.

Follow-up at nine month revealed that the patient was back at work which involves heavy lifting. The patient described painless walking on flat surfaces but described slight pain on walking quickly. On examination patient appeared to walk normally. There were no palpable gaps around the suprapatellar region or along the extensor mechanism and no bony tenderness over the patella or over the tendon. He could fully straighten his knee and do active straight leg raise comparable to the contra lateral side. Fully flexion of his knee was possible without discomfort and there was no joint effusion or joint line tenderness. Anterior drawer test and Lachman test were negative and the posterior cruciate ligament and collaterals were clinically stable. McMurray test was negative for both menisci. Check X-rays were also normal (Figure 4A–B). There was also no evidence of distal neurovascular deficit. However, the patient did have an area the size of a penny over the lateral aspect of the scar that was hypersensitive. This is likely to be due to the midline knee approach.

## DISCUSSION

The occurrence of bipartite patella simultaneously with quadriceps avulsion is an uncommon injury which is often misdiagnosed as a patellar avulsion fracture [1].

Bipartite patella occurs when the secondary ossification centre of the patella fails to fuse with the primary center [1]. It has an incidence of 2-6%, with males having a higher predisposition rate (8:1) [2]. It occurs bilaterally in 43% of patients with bipartite patella [2]. However, usually it is asymptomatic (98% of cases) [3–4]. Bipartite patella is often diagnosed incidentally by plain radiographs [3, 5].

Direct trauma may disrupt the synchondroses, causing irritation and inflammation which manifests with fracture like symptoms. Onset either occurs gradually or immediately after the injury [6].

Common symptoms of inflamed/irritated bipartite due to trauma include; anterior knee pain, swelling of the synchondrosis and painful range of motion of the knee [5].

In 1943, Saupe developed a classification system describing the three types of bipartite patella (Table 1) [7, 8].

For fractured bipartite patella, if there is an extra articular fragment it can be excised, however if there is an intra articular fragment open reduction and internal fixation is advised [2, 9–11]. Different methods of internal fixation are described in literature including tension band wiring, using parallel interfragmentary lag screws and the combination of tension band wiring with cannulated lag screws. Biomechanical evaluation of different approaches has reported that patellar fractures stabilized with screws were significantly less likely to displace than the tension band technique [12]. The preferred method for this patient by the operating surgeon was fixation with interfragmentary screws.

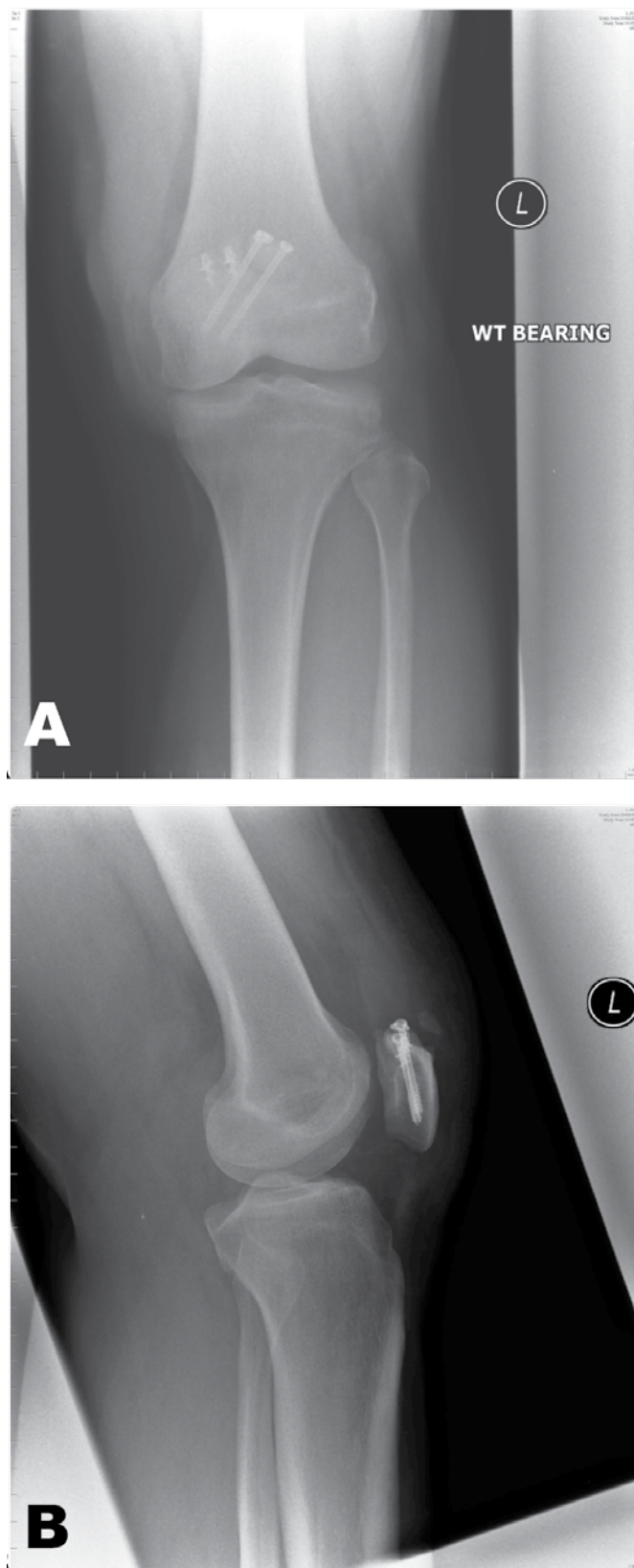


Figure 4: (A) Anterior-posterior radiograph of left knee postoperatively showing satisfactory reduction and screw fixation of the separation as well as anchors to reattach the quadriceps tendon. (B) Lateral radiograph of the left knee postoperatively.

Table 1: Saupe's classification of bipartite patella. Adapted from [1, 7, 8]

Type	Part of patella affected	Relative prevalence
I	Inferior pole	5%
II	Lateral margin type	20%
III	Superolateral nature	75%

A diagnosis of quadriceps avulsion is obtained through a full history and examination. It characteristically presents with a triad of pain, supra patellar gap and a loss of extensor mechanism of the affected leg [13].

There are several diagnostic imaging mediums such as plain radiographs, magnetic resonance imaging (MRI) and ultrasound. Plain radiographs should be the initial tool used as they demonstrate a good overall view, show loss of quadriceps and supra patellar mass etc. MRI scan is the most effective in establishing injury pattern [14].

The treatment for incomplete quadriceps avulsion is non operative, immobilization in extension followed by a physiotherapy program [14, 15].

Complete rupture/avulsion indicates prompt surgical management within 72 hours, which yields best results according to literature [15–17]. Most patients obtain a good range of motion but some may have persistent weakness preventing them from carrying out strenuous exercise [17].

Delay in surgery of more than 72hrs gives suboptimal results due to quadriceps tendon retraction and patella bafa [18].

## CONCLUSION

Although bipartite patella and quadriceps avulsion is rare, repairing the avulsed tendon with fixation of the bipartite fragment in our case resulted in a good outcome. Therefore we can recommend this method of treatment in such an injury.

\*\*\*\*\*

## Author Contributions

Hasan Raza Mohammad – Substantial contributions to conception and design, Acquisition of data, Analysis and interpretation of data, Writing the article and revising the content, Final approval of the version to be published

S Bitar – Substantial contributions to conception and design, Acquisition of data, Analysis and interpretation of data, Patient assessment and follow up, Revising the content of the article and proofreading, Final approval of the version to be published

I Symon – Substantial contributions to conception and design, Revising article for intellectual content and proofreading, Final approval of the version to be published

A Henry – Substantial contributions to conception and design, Helped to obtain images, Revising the content of the article, Final approval of the version to be published.  
G Batra – Substantial contributions to conception and design, Operating surgeon, Revising the content of the article, Final approval of the version to be published

## Guarantor

The corresponding author is the guarantor of submission.

## Conflict of Interest

Authors declare no conflict of interest.

## Copyright

© Hasan Raza Mohammad et al. 2014; This article is distributed under the terms of Creative Commons attribution 3.0 License which permits unrestricted use, distribution and reproduction in any means provided the original authors and original publisher are properly credited. (Please see [www.ijcasereportsandimages.com/copyright-policy.php](http://www.ijcasereportsandimages.com/copyright-policy.php) for more information.)

## REFERENCES

1. Gorva AD, Siddique I, Mohan R. An Unusual Case of Bipartite Patella Fracture with Quadriceps Rupture. *European Journal of Trauma* 2006;32:411–3.
2. Bourne MH, Bianco AJ Jr. Bipartite patella in the adolescent: Result of surgical excision. *J Pediatr Orthop* 1990;10(1):69–73.
3. Atesok K, Doral MN, Lowe J, Finsterbush A. Symptomatic bipartite patella: Treatment alternatives. *J Am Acad Orthop Surg* 2008;16(8):455–61.
4. Weaver JK. Bipartite patella as a cause of disability in the athlete. *Am J Sports Med* 1977;5(4):137–43.
5. Gaheer RS, Kapoor S, Rysavy M. Contemporary management of symptomatic bipartite patella. *Orthopaedics* 2009;32(11):843–9.
6. Ogata K. Painful bipartite patella. A new approach to operative treatment. *J Bone Joint Surg Am* 1994;76(4):573–8.
7. Saupe H. Primäre Krochenmark serlerung der kniescheibe. *Deutsche Z Chir* 1943;258:386–92.
8. Lee WJ, T Te AL, Cheng YZ. Pain in both knees. *CMAJ* 2008;179(11):1227.
9. Canizares GH, Selesnick FH. Bipartite patella fracture. *Arthroscopy* 2003;19(2):215–7.
10. Mori Y, Okumo H, Iketani H, Kuroki Y. Efficacy of lateral retinacular release for painful bipartite patella. *Am J Sports Med* 1995;23(1):13–8.
11. Ireland ML, Chang JL. Acute fracture bipartite patella: Case report and literature review. *Med Sci Sports Exerc* 1995;27(3):299–302.
12. Carpenter JE, Kasman RA, Patel N, Lee ML, Goldstein SA. Biomechanical evaluation of current patella fracture fixation techniques. *J Orthop Trauma* 1997;11(5):351–6.
13. Tietjens B, Aitken G, Walsh S. Symptomatic bipartite patella. *J Bone Joint Surg Am* 1992;74(suppl):267.

14. Thomas AL, Wilson RH, Thompson TL. Quadriceps Avulsion Through a Bipartite Patella. *Orthopedics* 2007;30(6):491–2.
15. MacEachern AG, Plewes JL. Bilateral simultaneous spontaneous rupture of the quadriceps tendons. Five case reports and a review of the literature. *J Bone Joint Surg Br* 1984;66(1):81–3.
16. Konrath GA, Chen D, Lock T, et al. Outcomes following repair of quadriceps tendon ruptures. *J Orthop Trauma* 1998;12(4):273–9.
17. Bimmel R, Reddy K. Quadriceps tendon rupture and periosteal sleeve avulsion fracture of the proximal patella pole in an active adolescent. *Orthopedics* 2008;31(7):716.
18. Scuderi C. Ruptures of the quadriceps tendon; study of twenty tendon ruptures. *Am J Surg* 1958;95(4):626–34.

Access full text article on  
other devices



Access PDF of article on  
other devices



## Edorium Journals: An introduction

Edorium Journals Team

### About Edorium Journals

Edorium Journals is a publisher of high-quality, open access, international scholarly journals covering subjects in basic sciences and clinical specialties and subspecialties.

#### Invitation for article submission

We sincerely invite you to submit your valuable research for publication to Edorium Journals.

### But why should you publish with Edorium Journals?

In less than 10 words - we give you what no one does.

#### Vision of being the best

We have the vision of making our journals the best and the most authoritative journals in their respective specialties. We are working towards this goal every day of every week of every month of every year.

#### Exceptional services

We care for you, your work and your time. Our efficient, personalized and courteous services are a testimony to this.

#### Editorial Review

All manuscripts submitted to Edorium Journals undergo pre-processing review, first editorial review, peer review, second editorial review and finally third editorial review.

#### Peer Review

All manuscripts submitted to Edorium Journals undergo anonymous, double-blind, external peer review.

#### Early View version

Early View version of your manuscript will be published in the journal within 72 hours of final acceptance.

#### Manuscript status

From submission to publication of your article you will get regular updates (minimum six times) about status of your manuscripts directly in your email.

### Our Commitment

#### Six weeks

You will get first decision on your manuscript within six weeks (42 days) of submission. If we fail to honor this by even one day, we will publish your manuscript free of charge.

#### Four weeks

After we receive page proofs, your manuscript will be published in the journal within four weeks (31 days). If we fail to honor this by even one day, we will publish your manuscript free of charge and refund you the full article publication charges you paid for your manuscript.

#### Mentored Review Articles (MRA)

Our academic program "Mentored Review Article" (MRA) gives you a unique opportunity to publish papers under mentorship of international faculty. These articles are published free of charges.

#### Most Favored Author program

Join this program and publish any number of articles free of charge for one to five years.

#### Favored Author program

One email is all it takes to become our favored author. You will not only get fee waivers but also get information and insights about scholarly publishing.

#### Institutional Membership program

Join our Institutional Memberships program and help scholars from your institute make their research accessible to all and save thousands of dollars in fees make their research accessible to all.

#### Our presence

We have some of the best designed publication formats. Our websites are very user friendly and enable you to do your work very easily with no hassle.

#### Something more...

We request you to have a look at our website to know more about us and our services.

We welcome you to interact with us, share with us, join us and of course publish with us.



Edorium Journals: On Web



Browse Journals

CONNECT WITH US

