

Maternal death as a complication of uterine perforation with associated bowel prolapse per vaginum following attempted termination of pregnancy at a peripheral hospital: A case report

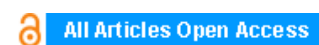
Labaran D Aliyu, Makama B Salihu

ABSTRACT

Introduction: Induced abortion is a procedure carried out to terminate a pregnancy for varied indications. It can, however, be complicated by severe complications including bowel injury and in some cases death. Complications are common when the procedure is carried out by the untrained or poorly trained personnel.

Case Report: This is a case of uterine perforation associated with bowel prolapsed through the vagina following an attempted termination of a missed abortion at eighth week and six days in a 25-year-old G3P2+0 (with 2 living children). The procedure was carried out by paramedics at a local General Hospital. Misoprostol was first used to induce abortion. When it failed, oxytocin infusion was used and when it also failed, dilatation and curettage was attempted which resulted in the complications mentioned and the patient subsequently died on the fourth postoperative day of an exploratory laparotomy. This case showed how poorly or untrained personnel are still using all means available to terminate pregnancies even in our hospitals resulting in serious complications.

Conclusion: Complications of induced abortions in our environment are still common as untrained or poorly trained personnel engage in such procedures with grave consequences. To reduce these complications there is a need for proper training and provision of proper equipment and ensuring proper supervision of medical facilities.



International Journal of Case Reports and Images (IJCRI)



International Journal of Case Reports and Images (IJCRI) is an international, peer reviewed, monthly, open access, online journal, publishing high-quality, articles in all areas of basic medical sciences and clinical specialties.

Aim of IJCRI is to encourage the publication of new information by providing a platform for reporting of unique, unusual and rare cases which enhance understanding of disease process, its diagnosis, management and clinico-pathologic correlations.

IJCRI publishes Review Articles, Case Series, Case Reports, Case in Images, Clinical Images and Letters to Editor.

Website: www.ijcasereportsandimages.com

CASE REPORT

OPEN ACCESS

Maternal death as a complication of uterine perforation with associated bowel prolapse per vaginum following attempted termination of pregnancy at a peripheral hospital: A case report

Labaran D Aliyu, Makama B Salihu

ABSTRACT

Introduction: Induced abortion is a procedure carried out to terminate a pregnancy for varied indications. It can, however, be complicated by severe complications including bowel injury and in some cases death. Complications are common when the procedure is carried out by the untrained or poorly trained personnel. **Case Report:** This is a case of uterine perforation associated with bowel prolapsed through the vagina following an attempted termination of a missed abortion at eighth week and six days in a 25-year-old G3P2+0 (with 2 living children). The procedure was carried out by paramedics at a local General Hospital. Misoprostol was first used to induce abortion. When it failed, oxytocin infusion was used and when it also failed, dilatation and curettage was attempted which resulted in the complications mentioned and the patient subsequently died on the fourth postoperative day of an exploratory laparotomy. This case showed how poorly or untrained personnel are still using all means available to terminate pregnancies even in our hospitals resulting in serious complications. **Conclusion:** Complications of induced abortions in our

environment are still common as untrained or poorly trained personnel engage in such procedures with grave consequences. To reduce these complications there is a need for proper training and provision of proper equipment and ensuring proper supervision of medical facilities.

Keywords: Uterine perforation, Induced abortion, Bowel injury, Maternal death

How to cite this article

Aliyu LD, Salihu MB. Maternal death as a complication of uterine perforation with associated bowel prolapse per vaginum following attempted termination of pregnancy at a peripheral hospital: A case report. International Journal of Case Reports and Images 2014;5(2):104–107.

doi:10.5348/ijcri-2014-02-451-CR-3

INTRODUCTION

Unsafe abortion is defined as a procedure for termination of unwanted pregnancy either by persons lacking the necessary skills or in an environment lacking the minimal medical standard or both [1]. It is an important cause of maternal morbidity and mortality. It contributes 40% of maternal mortality in Nigeria [2]. Uterine perforation is a recognized complication of unsafe abortion. It occurs in 0.4–15 cases per 1000 induced abortions depending on the study population [3]. Bowel injury is uncommonly reported yet serious complication of induced abortion which is often performed illegally by persons without any medical training in developing countries [4, 5]. This is clearly demonstrated in this case. A sudden increase in cases of bowel injury as a consequence of induced abortion prompted researchers in India to conduct a study into the problem [5]. Many

Labaran D Aliyu¹, Makama B Salihu²

Affiliations: ¹Department of Obstetrics & Gynaecology, Abubakar Tafawa Balewa University Teaching Hospital, Bauchi, Nigeria; ²Department of Surgery Department, Abubakar Tafawa Balewa University Teaching Hospital, Bauchi, Nigeria.

Corresponding Author: Dr. Labaran Dayyabu Aliyu, Department of Obstetrics & Gynaecology, Abubakar Tafawa Balewa University Teaching Hospital, Bauchi, Nigeria; Mob: (234)08037054199; Email: zainalabidinaliyu@yahoo.com

Received: 19 July 2012

Accepted: 25 October 2012

Published: 01 February 2014

studies were carried out in Cameroon, Nigeria and Ghana on this deraided complication of induced abortion [4, 6, 7]. The fact that in this particular case the pregnancy was not unwanted, the procedure was done because of a missed abortion in a public hospital, under anesthesia, having failed to terminate the pregnancy with misoprostol and oxytocin infusion make the case an interesting one to report. It clearly demonstrates the pathetic state of our health care delivery system where seeking care in a health facility does not necessarily guaranty that patients are safe from unnecessary and potentially life-threatening complications because such facilities are poorly equipped and manned by ill trained personnel.

CASE SERIES

A 25-year-old G3P2+0 (with 2 living children) patient came into the Gynae emergency room of our hospital with a referral letter from a public hospital in her locality. She had been amenorrhic for about eight weeks prior to presentation and had intermittent episodes of bleeding per vaginum. At presentation at a local hospital a pelvic ultrasound scan was done which revealed a missed abortion at eighth week and six days. She was informed of the result and told that the pregnancy has to be removed which she consented to. Initially, misoprostol was used vaginally to induce abortion. When this failed, oxytocin infusion was used which also failed. Two days later she was told that since these two methods did not work she will undergo dilatation curettage (D&C) to remove the pregnancy.

The D&C procedure was carried out and she later started experiencing severe lower abdominal pain and was bleeding through the vagina. The relatives were told also there that the pregnancy could not be removed completely and part of it is protruding through the vagina and the patient will be referred to the Teaching Hospital in the city where the rest will be removed. She presented more than 24 hours after the procedure because they had difficulty getting money and transportation.

At presentation, she was drowsy with offensive smell around her. She was pale, febrile (38.10°C), anicteric and dehydrated. Respiratory rate 26/min, her chest was clinically clear. Pulse rate was 104/minute, blood pressure was 90/60 mmHg. Her abdomen was slightly distended and there was generalized tenderness, bowel sounds were hypoactive. Pelvic examination revealed vulva and vagina smeared with blood. A vaginal pack was removed and dark pink intestines started coming out through the vaginal introitus with slight bleeding.

An intravenous line was secured and two liters of normal saline were rushed and another liter was kept running at slower rate. She was immediately placed on intravenous ceftriazone and metronidazole. Nasogastric tube was inserted and she was catheterized. Samples were taken for complete blood count, random blood sugar, serum electrolytes and urea and 4 pints of blood

were cross matched. Her hemoglobin was 8 g/dL and other results were not available before surgery. A surgical team was called to review the patient. A joint decision was taken to carry out an exploratory laparotomy. The patient was counselled and her consent obtained. About 10 hours after presentation she was taken to the theatre for surgery.

Findings at Operation

Offensive hemoperitoneum of about 1000 mL, a bulky uterus of about 16 weeks size, a posterior uterine perforation about 4 cm in diameter with rugged edges with dark pink ileal tissue passing through the perforation about 30 cm long, the tubes and ovaries were enlarged and hyperemic. A linear laceration on the anterior aspect of the upper 1/3 of the rectum with devitalized edges, distal sigmoid colon lacerated with irregular devitalized edges. The uterine perforation was enlarged and placental tissues evacuated gently and the perforation repaired after excising the devitalized edges. Refashioning and anastomosis of the sigmorectoid and ileocecal junctions were done. The peritoneal cavity was copiously lavaged and a corrugated drain passed into pouch of Douglas and fixed to the skin. The abdomen was closed in layers. Two pints of blood were transfused intraoperatively, IV ceftriazone and metronidazole were also given. Intraoperative blood loss was estimated to be 750 mL. Patient was transfused two more pints of blood postoperatively (Figures 1 and 2).

Patient fared fairly well postoperatively with relatively stable vital signs and was making adequate urine. On the fourth postoperative day she started running temperature and her condition suddenly deteriorated and she died the same day.

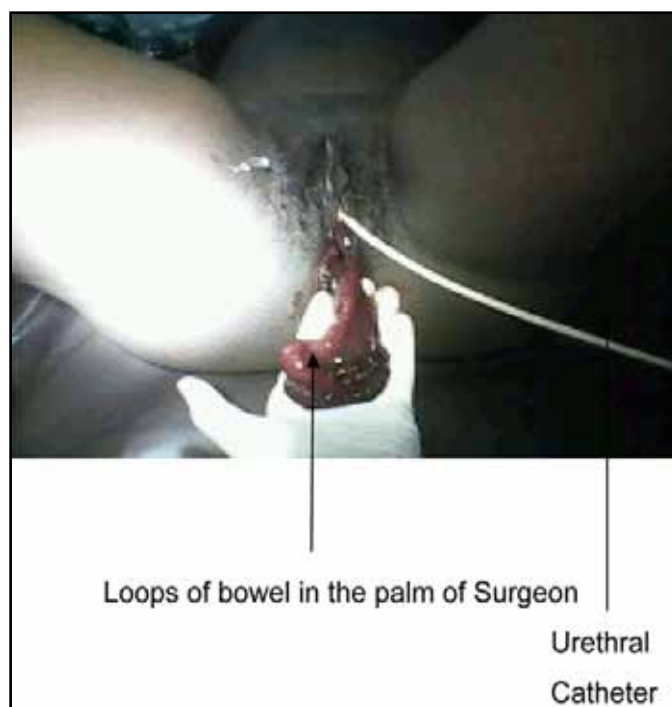

Figure 1: Bowel protruding per vaginum.

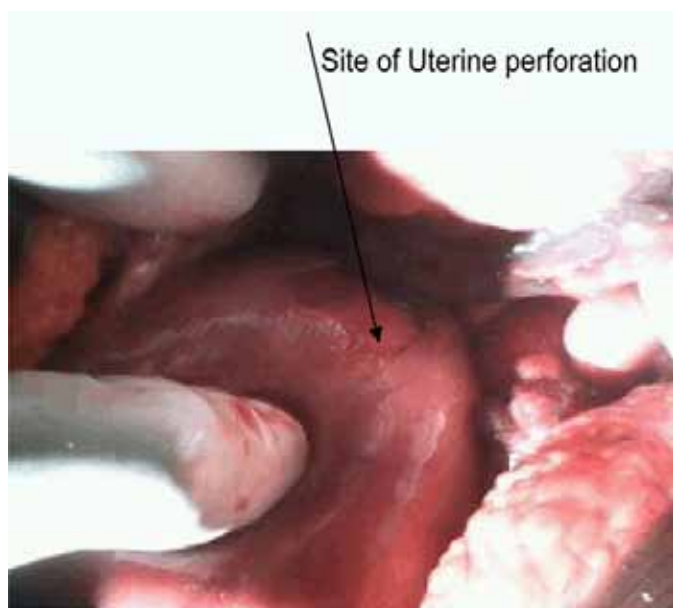


Figure 2: The uterus with the perforated area.

DISCUSSION

Induced abortion has remained a source of serious concern to all gynecologist worldwide especially those in the developing world. This is so because in our environment there are still factors militating against the performance of safe abortion. Most worrisome are untrained quacks whose motive may be financial and their skills negligible [8]. A major barrier to care in many developing countries is the lack of basic equipment and drugs for all gynecological care [9]. Restrictive abortion laws is another important hindrance to safe abortion because women seeking abortion are left with no alternative other than procuring it through the backdoor which make them vulnerable to all complications including death. Legalization of abortion although important is insufficient. India has had legal abortion on the books for several decades as has Zambia, however the devil is in the details [10]. Without skilled providers, adequate facilities and early access, the promise of safe, legal abortion will remain unfulfilled, as in the case of India and Zambia [11]. Bowel injury is a common consequence of uterine perforation either with pointed instruments or grasping forceps. The distal ileum appears to be most vulnerable followed by the sigmoid [12]. The patient in question had similar injuries. Such injuries are associated with peritoneal soilage with fecal material containing virulent intestinal bacteria, which invariably leads to peritonitis and generalized septicemia; this will lead to serious morbidity and in extreme cases death will result as in this case. Early recognition of the injury, adequate resuscitation and experienced surgical intervention may be the only solution if the life of the patient is to be saved. These are usually not possible in developing countries and as a result patients die. Our patient could not come

immediately because of financial difficulty and challenges of transportation. This delay must have compounded her clinical condition at presentation.

To arrest this pathetic situation, Governments in partnership with nongovernmental organizations, religious groups and women groups should embark on extensive community awareness campaigns on the issue of abortion and its consequences. Governments should improve the health care delivery system through training, provision of equipment and facilities to be made available and accessible at all times and to most communities no matter how remote they may be. There is also the need to review our abortion laws so that morbidity and mortality attributed to abortion will be drastically reduced.

CONCLUSION

Complications of induced abortions in our environment are still common as untrained or poorly trained personnel engage in such procedures with grave consequences. To reduce these complications there is a need for proper training and provision of proper equipment and ensuring proper supervision of medical facilities. There is also a need for public enlightenment on induced abortion and its consequences.

Author Contributions

Labaran D Aliyu – Substantial contributions to conception and design, Acquisition of data, Analysis and interpretation of data, Drafting the article, Revising it critically for important intellectual content, Final approval of the version to be published

Makama B Salihu – Substantial contributions to conception and design, Acquisition of data, Analysis and interpretation of data, Drafting the article, Revising it critically for important intellectual content, Final approval of the version to be published

Guarantor

The corresponding author is the guarantor of submission.

Conflict of Interest

Authors declare no conflict of interest.

Copyright

© Labaran D Aliyu et al. 2014; This article is distributed under the terms of Creative Commons attribution 3.0 License which permits unrestricted use, distribution and reproduction in any means provided the original authors and original publisher are properly credited. (Please see www.ijcasereportsandimages.com/copyright-policy.php for more information.)

REFERENCES

1. Ahman E, Sha I. Unsafe abortion: worldwide estimates for 2000. *Reprod Health matters* 2002;10(19):13–7.
2. Okonofua F. prevention of unsafe abortion in Nigeria. *Afri J Reprod Health* 1997;1(1):25-36.
3. Nathanson BN. Management of uterine perforation suffered at elective abortion. *Am J Obstet Gynaecol* 1972;114(8):1054–9.
4. Nana PN, Fomulu JN, Mbu RE, et al. A four year retrospective review of postabortal surgical complications at a Central Maternity Yaounde, Cameroon. *Clinics in Mother and Child Health* 2005;2(2):349–63.
5. Jhobta RS, Attri AK, Jhobta A. Bowel injury following induced abortion. *Int J Gynaecol Obstet* 2007;96(1):24–7.
6. Ntia IO, Ekele BA. Bowel prolapsed through perforated uterus following induced abortion. *West Afr J Med* 2000;19(3):209–11.
7. Obed SA, Wilson JB. Uterine perforation from induced abortion in Korle Bu Teaching Hospital Accra Ghana; A five year review. *West Afr J Med* 1999;18(4):286–9.
8. Rogo KO. Induced abortion in Sub-Saharan Africa. *East Afri Med J* 1993;70(6):386–95.
9. Rogo KO, Aloo-Obunga C, Ombaka C, et al. Maternal mortality in Kenya: The state of health facilities in A rural district. *East Afri Med J* 2001;78(9):468–72.
10. Berer M. Making abortion safe: a matter of good public policy. *Bull World Health Organization* 2000;78(5):580–92.
11. Grimes DA. Unsafe abortion: the silent scourge. *British Med J Bulletin* 2003;67(1):99–113.
12. Imodemhe DA, Ezimokhai M, Okpere EE, Aboh IF. Intestinal injuries following induced abortion. *Int J Gynaecol Obstet* 1984;22(4):303–6.

Access full text article on
other devices



Access PDF of article on
other devices



Edorium Journals: An introduction

Edorium Journals Team

About Edorium Journals

Edorium Journals is a publisher of high-quality, open access, international scholarly journals covering subjects in basic sciences and clinical specialties and subspecialties.

Invitation for article submission

We sincerely invite you to submit your valuable research for publication to Edorium Journals.

But why should you publish with Edorium Journals?

In less than 10 words - we give you what no one does.

Vision of being the best

We have the vision of making our journals the best and the most authoritative journals in their respective specialties. We are working towards this goal every day of every week of every month of every year.

Exceptional services

We care for you, your work and your time. Our efficient, personalized and courteous services are a testimony to this.

Editorial Review

All manuscripts submitted to Edorium Journals undergo pre-processing review, first editorial review, peer review, second editorial review and finally third editorial review.

Peer Review

All manuscripts submitted to Edorium Journals undergo anonymous, double-blind, external peer review.

Early View version

Early View version of your manuscript will be published in the journal within 72 hours of final acceptance.

Manuscript status

From submission to publication of your article you will get regular updates (minimum six times) about status of your manuscripts directly in your email.

Our Commitment

Six weeks

You will get first decision on your manuscript within six weeks (42 days) of submission. If we fail to honor this by even one day, we will publish your manuscript free of charge.

Four weeks

After we receive page proofs, your manuscript will be published in the journal within four weeks (31 days). If we fail to honor this by even one day, we will publish your manuscript free of charge and refund you the full article publication charges you paid for your manuscript.

Mentored Review Articles (MRA)

Our academic program "Mentored Review Article" (MRA) gives you a unique opportunity to publish papers under mentorship of international faculty. These articles are published free of charges.

Most Favored Author program

Join this program and publish any number of articles free of charge for one to five years.

Favored Author program

One email is all it takes to become our favored author. You will not only get fee waivers but also get information and insights about scholarly publishing.

Institutional Membership program

Join our Institutional Memberships program and help scholars from your institute make their research accessible to all and save thousands of dollars in fees make their research accessible to all.

Our presence

We have some of the best designed publication formats. Our websites are very user friendly and enable you to do your work very easily with no hassle.

Something more...

We request you to have a look at our website to know more about us and our services.

We welcome you to interact with us, share with us, join us and of course publish with us.



Edorium Journals: On Web



Browse Journals

CONNECT WITH US

