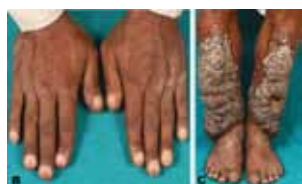


International Journal of Case Reports and Images



Cover Figure:



All Articles:



Contents

Vol. 4, No. 12 (December 2013)

Cover Image

Figure 1: (B) Grade 3 clubbing of fingers, and (C) Bilateral pretibial nodular hyperpigmented, asymmetrical and non-pitting lesions non-pitting with plaques between and over the nodules.

Review Article

- 666** Effect of *Crocus sativus* and its active compounds for the treatment of several diseases: A review
Rafie Hamidpour, Soheila Hamidpour, Mohsen Hamidpour, Mina Shahlari
- 671** Sage: The functional novel natural medicine for preventing and curing chronic illnesses
Rafie Hamidpour, Soheila Hamidpour, Mohsen Hamidpour, Mina Shahlari

Case Report

- 678** Collagenous gastritis: Gastroesophageal reflux disease in an adult patient without collagenous colitis
Yousef Usta, Denise Millstine, Fredrick Kenny
- 682** Prostatic ductal adenocarcinoma presenting with hemospermia
Tafadzwa P Makarawo, Jeffrey L O'Connor
- 686** Chest X-Ray appearance of total opacification of the hemithorax following central venous line insertion: A cautionary tale
Victor Kong, Leah Naidoo, Damon Jeetoo, George Oosthuizen, Grant Laing, Damian Clarke
- 691** Idiopathic double telescoping intussusception in an adult
Manash Ranjan Sahoo, Manoj Srinivas Gowda, Raghavendra Mohan Kaladagi
- 695** Pretibial myxedema mimicking elephantiasis
Pinaki Dutta, Viral N Shah
- 698** Amphetamine abuse and acute thrombosis of left circumflex coronary artery
Eyad Khattab, Asaad Shujaa
- 702** Pseudotumor cerebri caused by uncontrolled Graves' disease in an adolescent
Ashutosh Kumar, Sasikumar Kilaikode, Paul Saenger
- 705** Gastric malignancy presenting as adrenal insufficiency: A case report
Harsh Vardhan Tevethia, Baskaran S, Tony Mathew Kadavanu, Riyaz M Panchbhaya, Sunny DAN, Siva PK

- 709** Talon cusp in primary dentition: A case report
Ravi Prakash Sasankoti Mohan, Sankalp Verma, Udit Singh, Neha Agarwal, Soumi Ghanta, Kuber Tyagi
- 714** Unique case of dual gynecological malignancies co-existing with an uncommon thyroid lymphoma
Ravi Prakash Sasankoti Mohan, Sankalp Verma, Udit Singh, Neha Agarwal, Soumi Ghanta, Kuber Tyagi
- 719** Unexpected brain atrophy following administration of intratumoral interferon alpha-2b for cystic craniopharyngioma: A case report
Khadiga Elfadil Ahmed Mohammed, Kellie R Alleyne Mike, Jeannette Parkes
- 723** Cholesterol granuloma of the breast suspected as breast carcinoma
Takaaki Fujii, Reina Yajima, Hiroki Morita, Satoru Yamaguchi, Soichi Tsutsumi, Takayuki Asao, Hiroyuki Kuwano
- 727** Severely ectatic left circumflex coronary artery with fistula to coronary sinus presenting with acute coronary syndrome
Ahmed Sayed
- 731** Bronchogenic cyst: A case report
Aniruddha Sarkar, Narayan Pandit
- 735** Reversible cerebral vasoconstriction syndrome in HELLP syndrome
Shinji Katsuragi, Masato Osaki, Rieko Suzuki, Tomoaki Ikeda, Kazunori Toyoda, Jun Yoshimatsu
- 739** Air bubble in the heart: An unrecognized complication of IV contrast injector
Carlos Gonzalez, Dioben Aquino, Balavenkatesh Kanna

Case in Images

- 742** Unexpected Crohn's Disease after a Free Gastrointestinal Perforation
René Rodríguez-Gutiérrez, Mario Rodarte-Shade, José Gerardo González-González
- 745** Hemophilic Arthropathy
Babajide O Olubaniyi, Olubukola Ajala, David C Howlett

Letter to Editors

- 748** Plasma cell leukemia of IgG secreting type: A rare case
Parth Anil Desai, Sagar Dholariya, Sanjeev Gupta, Tejinder Singh

SUBMISSION INSTRUCTIONS

All manuscripts, including illustrations, should be submitted at: www.ijcasereportsandimages.com/submit or email to: submit@ijcasereportsandimages.com

Author Guidelines: www.ijcasereportsandimages.com/submit/instructions-for-authors.php

For any questions contact the Editorial Office via e-mail at: info@ijcasereportsandimages.com or Fax: 1-773-409-5040