

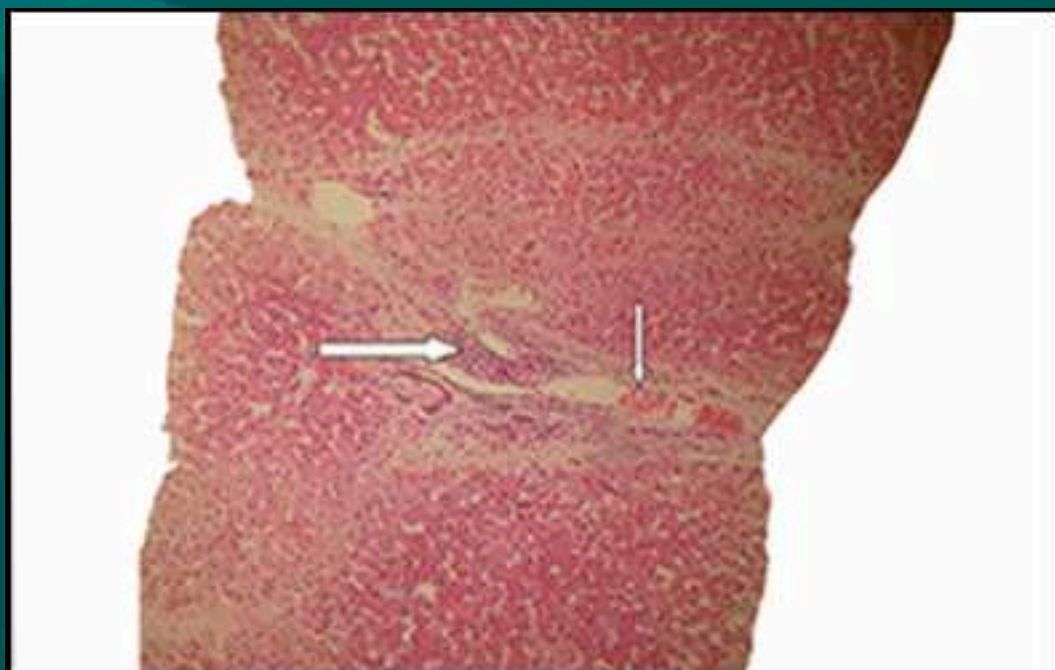
# IJCRI

[www.ijcasereportsandimages.com](http://www.ijcasereportsandimages.com)

---

International Journal of  
**CASE REPORTS AND IMAGES**

---



Online submission at:

[www.ijcasereportandimages.com/submit](http://www.ijcasereportandimages.com/submit)

ISSN: 0976-3198

## EDITORIAL BOARD

International Journal of Case Reports and Images (IJCRI)

Dr. Achuta Kumar Guddati	USA	Dr. Sanju George	UK
Dr. Aditya Gupta	USA	Dr. Saurabh Khakharia	USA
Dr. Antonio La Cava	USA	Dr. Sergio Gabriel Susmallian	Israel
Dr. Asher Bashiri	Israel	Dr. Shashideep Singhal	USA
Dr. Claudio Feliciani	Italy	Dr. Shilpa Jain	USA
Dr. Emre Karasahin	Turkey	Dr. Siddharth Mathur	USA
Dr. Deepa Rastogi	USA	Dr. Sirinrath Sirivisoot	USA
Dr. Deepak Sharma	USA	Dr. Stefan Hagmann	USA
Dr. Gavin A. Falk	USA	Dr. Tapas Saha	USA
Dr. Gil Atzmon	USA	Dr. Teguh Haryo Sasongko	Malaysia
Dr. Gokulakrishna Subhas	USA	Dr. Tun Hing Lui	China
Dr. Hajimi Orita	Japan	Dr. Yupeng Chen	USA
Dr. Imtiaz Wani	India		
Dr. James Cheng-Yi Lin	Taiwan		
Dr. Jonathan D. Solomon	USA		
Dr. Makoto Adachi	USA		
Dr. Mohamed Radhi	USA		
Dr. Naila Khalil	USA		
Dr. Oner Dikensoy	Turkey		
Dr. Pengcheng Luo	China		
Dr. Radhika Muzumdar	USA		
Dr. Rajesh Pareta	USA		
Dr. Ricardo Correa	USA		

### Contact Details:

#### Editorial Office

Email: [meditor@ijcasereportsandimages.com](mailto:meditor@ijcasereportsandimages.com)

Fax: +1-773-409-5040

Website: [www.ijcasereportsandimages.com](http://www.ijcasereportsandimages.com)


### Guidelines for Authors

Full instructions are available online at:  
[www.ijcasereportsandimages.com/submit/instructions-for-authors](http://www.ijcasereportsandimages.com/submit/instructions-for-authors)

Manuscript submission:  
[www.ijcasereportsandimages.com/submit](http://www.ijcasereportsandimages.com/submit)

### Disclaimer

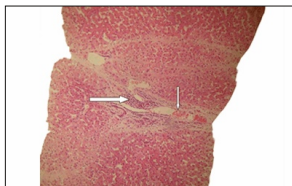
Neither International Journal of Case Reports and Images (IJCRI) nor its editors, publishers, owners or anyone else involved in creating, producing or delivering International Journal of Case Reports and Images (IJCRI) or the materials contained therein, assumes any liability or responsibility for the accuracy, completeness, or usefulness of any information provided in International Journal of Case Reports and Images (IJCRI), nor shall they be liable for any direct, indirect, incidental, special, consequential or punitive damages arising out of the use of International Journal of Case Reports and Images (IJCRI) or its contents. While the advice and information in this journal are believed to be true and accurate on the date of its publication, neither the editors, publisher, owners nor the authors can accept any legal responsibility for any errors or omissions that may be made or for the results obtained from the use of such material. The editors, publisher or owners, make no warranty, express or implied, with respect to the material contained herein. (<http://www.ijcasereportsandimages.com/disclaimer.php>)



## Contents

Vol. 3, No. 11 (November 2012)

### Cover Figure:



### Cover Figure

Figure 2: Focal Nodular Hyperplasia: Photomicrograph showing central scar with blood vessels and fibrous septa separating cirrhosis-like nodules of hepatocytes. There is a large central artery (vertical arrow) with inflammatory cell infiltrates (horizontal arrow) and numerous ductules (H&E  $\times 40$ ).

### Case Report

- 1 Situs inversus and metastatic renal cell carcinoma: A case report of a rare disease  
*Rangarajan S, Sunil B, Shet AS*
- 5 Advanced live intraabdominal pregnancy with good fetomaternal outcome: A case report  
*Sharma R, Puri M, Madan M, Trivedi SS*
- 8 Hepatic hemangioma and focal nodular hyperplasia in a Nigerian patient with hepatitis B virus infection  
*Oluyemi AO, Adeyomoye AO, Awolola NA*
- 11 Intraparotid lymph node with metastatic angiosarcoma: A rare tumor with a routine presentation  
*Hiten Joshi, David McPartlin*
- 14 Octreotide induced thrombocytopenia  
*Yousaf H, Saddique I*
- 17 An uncommon cause of apparent life-threatening event  
*Waseem M, Soontharothai D, Pinkert H, Erickson E, Trotman M*
- 21 Postpartum spontaneous coronary artery dissection: A rare occurrence  
*Mendez JR, Gerner J, Andrews-Reynolds K, Dharmarajan L*
- 25 Congenital nephrogenic diabetes insipidus presented after acute pyelonephritis  
*Castillo C, Bherwani P, Erickson E, Prosper G*
- 28 Numb Chin in thyroid carcinoma: A rare clinical presentation  
*Kalburge JV, Kini YK, Kalburge VJ*

- 32 Ileocecal burkitt's lymphoma presenting as acute appendicitis: A case report  
*Gonçalves JP, Cerqueira A, Antunes H, Maia Í, Carvalho S*
- 35 Primary duodenal adenocarcinoma of the fourth portion diagnosed using double-balloon enteroscopy and surgically resected: A case report  
*Kawano S, Sato K, Maekawa H, Sakurada M, Orita H, Wada R*
- 40 Unique presentation with trimodal transfer of a patient with traumatic bilateral anterior (obturator) hip dislocation  
*Manikam R, Kumar CS, Kunalan G, Latha ABS, Mohamad N*
- 43 Knowing your lab test well: Expanding the differential for elevated alkaline phosphatase  
*Jain SKA, Patel K, Ismail Y, Williams M*
- 47 Inguinal dermoid cyst masquerading as irreducible inguinal hernia : Case report  
*Das S, De D, Das D, Sarkar S*
- 50 Selenium adjuvant therapy in central nervous system infection  
*Kocan L, Vašková J, Firment J, Vaško L*

### Clinical Images

- 56 Silicone gel breast implant rupture by MR imaging  
*Elzaki AA, Hamid HO, Babiker IEB*
- 58 Apparent right mid-lung mass in a dyspneic man: The phantom lung tumor  
*Kavitha B, Balasubramanian R*
- 60 Paraduodenal hernia presenting as acute intestinal obstruction on CT imaging  
*Flexer SM, Scullion D*

### Letter to Editor

- 62 Monosomy 18p and hepatosplenomegaly  
*Ponchai K, Erickson E, Marrero EA*

### All Articles:



### SUBMISSION INSTRUCTIONS

All manuscripts, including illustrations, should be submitted at: [www.ijcasereportsandimages.com/submit](http://www.ijcasereportsandimages.com/submit) or email to: [submit@ijcasereportsandimages.com](mailto:submit@ijcasereportsandimages.com)

Author Guidelines: [www.ijcasereportsandimages.com/submit/instructions-for-authors.php](http://www.ijcasereportsandimages.com/submit/instructions-for-authors.php)

For any questions contact the Editorial Office via e-mail at: [info@ijcasereportsandimages.com](mailto:info@ijcasereportsandimages.com) or Fax: 1-773-409-5040

CASE REPORT

OPEN ACCESS

# Situs inversus and metastatic renal cell carcinoma: A case report

Sunil Rangarajan, Bhuvana Sunil, Arun S Shet

## ABSTRACT

**Introduction:** Situs Inversus Totalis is a rare congenital condition with an autosomal recessive inheritance. Most of the people with SIT are asymptomatic, making its diagnosis a challenge. Although many cases of cancers co-existing with SIT have been reported in medical literature, the co-existence of RCC with SIT is extremely rare. We are presenting the 5th reported case in the published medical literature. **Case Report:** We report a case of a 65-year-old male who was presented with intractable back pain, difficulty in performing daily activities and unintentional weight loss. Evaluation of these symptoms revealed SIT, a right renal mass and widespread metastatic deposits. Immunohistochemical analysis confirmed the diagnosis of clear cell type of renal cell carcinoma. **Conclusion:** Situs Inversus is a rare congenital abnormality which may be associated with renal anomalies, Kartagener syndrome, and several types of malignancies. Further study is needed to characterize the

genetic basis of SI and establish whether there is a causal basis between SI and the development of malignancy or not.

**Keywords:** Situs inversus totalis, Renal cell carcinoma, Malignancy

\*\*\*\*\*

Rangarajan S, Sunil B, Shet AS. Situs inversus and metastatic renal cell carcinoma: A case report. International Journal of Case Reports and Images 2012;3(11):1–4.

\*\*\*\*\*

doi:10.5348/ijcri-2012-11-208-CR-1

## INTRODUCTION

Situs inversus totalis (SIT) refers to a congenital condition in which the thoracic and the abdominal viscera are transposed through the sagittal plane. It is an autosomal recessive condition with 0.01–0.02% prevalence in general population [1]. Most of the people with SIT are asymptomatic, making its diagnosis a challenge. Among all diagnosed cancers, only 2–3% belong to renal cell carcinoma (RCC), which has a greater occurrence in males, [2]. Although many cases of cancers co-existing with SIT have been reported in medical literature, the co-existence of RCC with SIT is extremely rare. We are presenting a rare case of metastatic RCC with SIT, which is the 5th reported case in the published medical literature.

## CASE REPORT

A 65-year-old male was presented to the hospital with four months history of fatigue, difficulty in getting up, walking and performing daily activities. He had

Sunil Rangarajan<sup>1</sup>, Bhuvana Sunil<sup>2</sup>, Arun S Shet<sup>3</sup>

**Affiliations:** <sup>1</sup>Junior Resident, Department of Medical Oncology, St. John's Medical College and Hospital, Bangalore, Karnataka, India; <sup>2</sup>Research Associate, St. John's Research Institute, Bangalore, Karnataka, India; <sup>3</sup>Professor & Head, Department of Medical Oncology, St. John's Medical College and Hospital, Bangalore, Karnataka, India.

**Corresponding Author:** Arun S Shet, Department of Medical Oncology, St. John's Medical College and Hospital, The St. John's National Academy of Health Sciences, Sarjapur Road, Bangalore 560034, India; Ph: 91-80-22065744; Fax: 91-80-25532037; Email: arunshet1@gmail.com

Received: 21 February 2012

Accepted: 07 May 2012

Published: 01 November 2012



severe right flank and back pain, unintentional and significant weight loss of 12 kg. There were occasional episodes of fever and hematuria over this four-month period. A limited cut magnetic resonance imaging (MRI) of the spine and abdomen to evaluate the back pain revealed SIT, a right renal mass, and multiple osseous lesions in L1, and L2 vertebrae and in sacrum, (Figure 1). The patient admitted to a chronic history of tobacco (64 pack years of smoking) and alcohol consumption. On physical examination, the patient was cachectic (weight: 43 kg, height: 1.6 m, Body Mass Index: 16.8 kg/m<sup>2</sup>). Pertinent positive findings on systemic examination revealed findings of SIT in the chest and abdomen. Respiratory system examination revealed that the trachea was deviated to the right, and dull percussion sounds were noted in the right infra-axillary, infrascapular areas. Breath sounds and vocal resonance were diminished in the right mammary, infra-axillary, infrascapular areas and there were scattered occasional rhonchi. Apart from dextrocardia, the cardiac examination was unremarkable. Neurological examination revealed extreme tenderness on palpation over the L1, and L2 vertebrae, and mild weakness on the left half of the body.

Aside from hypoalbuminemia, and elevations in the ESR and LDH, the other hematological and biochemical parameters were normal. Of note, the serum calcium was normal. Urinalysis revealed hematuria but the sediment was otherwise normal. A contrast enhanced computerized axial tomogram (CAT) scan of the abdomen performed to evaluate the extent of the disease revealed abdominal viscera transposed through the sagittal plane, and an ill-defined right renal mass measuring 4x3.5 cm with multiple para aortic lymph nodes, and multiple vertebral deposits, (Figure 2). CAT scan of the thorax revealed dextrocardia, a 6.5x5 cm solitary irregular mass in the apicoposterior segment of the anatomical right lung engulfing the anatomical right pulmonary artery, mediastinal lymphadenopathy, and multiple rib deposits, (Figure 3). A bone scan was not performed as the patient declined further testing.

CAT scan guided tru-cut biopsy of the most accessible metastatic deposit in the sacrum revealed

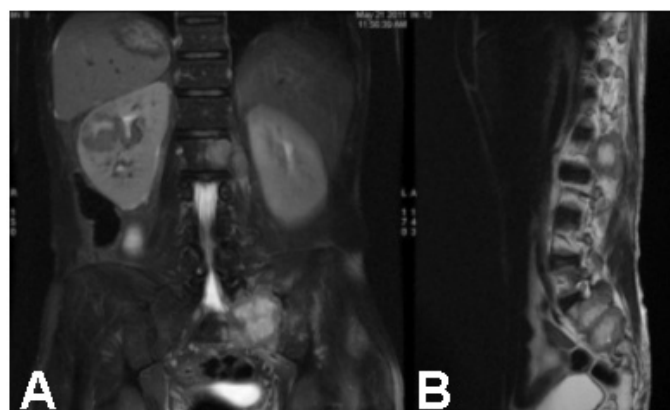


Figure 1: MRI of the Spine, (A) Renal mass in the anatomical right kidney; (B) Multiple metastatic deposits in the vertebrae, largest being the one in the sacrum.

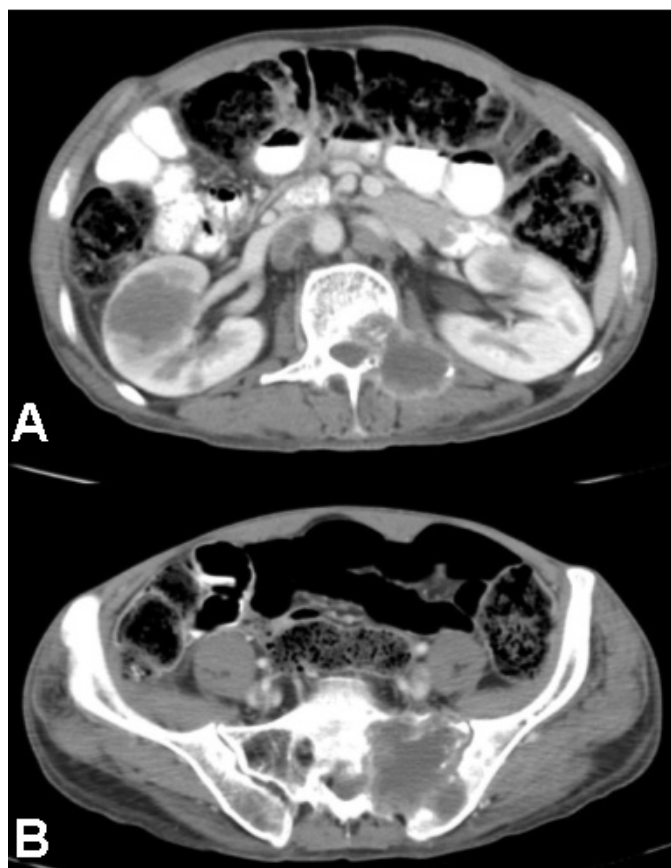

Figure 2: Contrast CT of Abdomen: (A) Mass in the anatomical right kidney with a metastatic lesion in the L1 vertebra; no extension of the mass into the renal vein. (B) Metastatic deposit in the sacrum.

neoplastic cells arranged in a glandular pattern. Immunohistochemical analysis revealed the malignant cells to be positive for pancytokeratin (3+, 95%), cytokeratin (CK) 5 and CK 7 (3+, 95%), CD 10 and vimentin (3+, 100%), and negative for thyroid transcription factor-1 (TTF-1) and prostate-specific antigen (PSA) (Figure 4). Based on the clinical, radiological, and histopathological findings, a diagnosis of metastatic clear cell type of RCC was made and the patient was counseled regarding his disease [3]. The patient was offered palliative radiation therapy but elected to receive opioid analgesia as the sole pain control modality. Over the next few days his overall condition deteriorated and he elected to get discharged from the hospital for home hospice care.

## DISCUSSION

Situs inversus (SI) is a rare disorder where most patients are asymptomatic leading to difficulty in assessing its true prevalence. It can be broadly classified based on the extent of the inversion of the viscera into SIT, situs solitus (isolated dextrocardia) and situs inversus viscerum, which is almost always associated

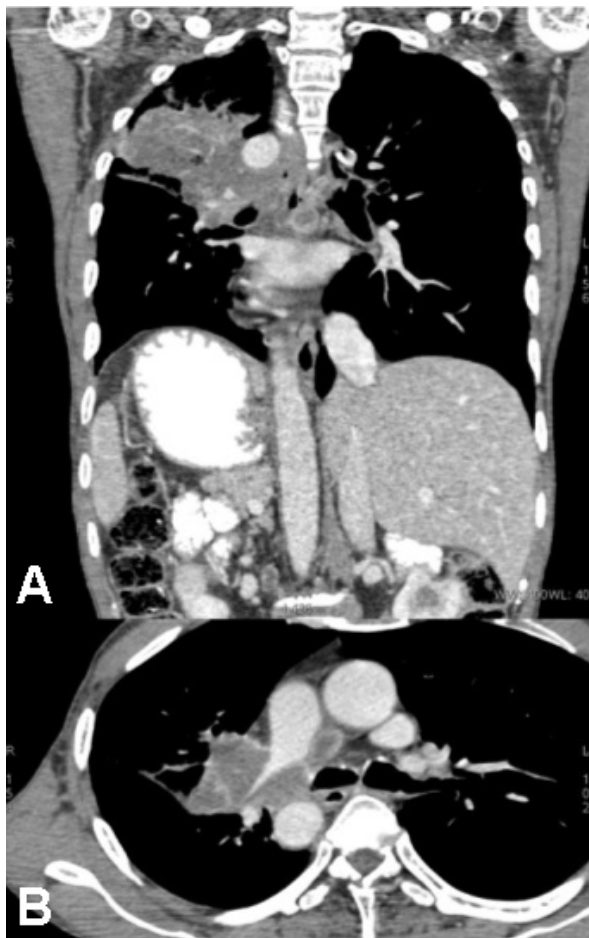


Figure 3: (A): Contrast CT of the thorax and abdomen: Image reveals the mass in the anatomical right lung with mediastinal lymph node involvement. It also reveals situs inversus of the abdomen, (B): Contrast CT of Thorax: Mass in the anatomical right lung engulfing the right division of the Pulmonary Artery. The inversion of the location of the great vessels showing Situs Inversus in the thoracic viscera.

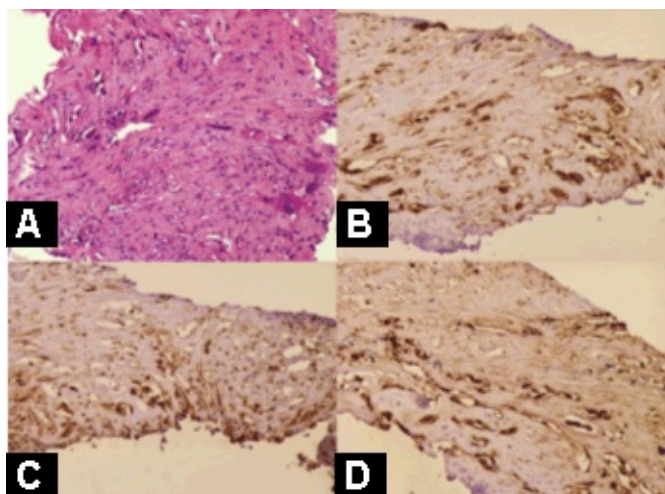


Figure 4: (A) Hematoxylin and Eosin staining of the biopsy tissue revealing the presence of thick fibrocollagenous tissue with an infiltrating neoplasm composed of neoplastic cells arranged in glandular pattern, (B) CD 10 staining positive, (C) Vimentin staining positive, and (D) CK 7 staining positive.

with congenital heart disease, [4, 5]. Other rare form of SI, situs ambiguus typically manifests as either asplenia syndrome (right isomerism) or polysplenia syndrome (left isomerism). Many cardiovascular and renal anomalies have been reported in patients with SIT. Though the exact mechanism of the abnormal heart tube orientation and development is not fully understood there are documented linkages to chromosomal abnormalities (balanced reciprocal translocation  $t(5;11)(q32;q24.2)$ , [6] and microdeletion of chromosome 2q37.3, [7]). Nearly 20–25% of the patients with SIT have syndrome of primary ciliary dyskinesia called Kartagener syndrome manifesting as repeated infections, bronchiectasis, and male infertility along with SIT, [4, 8].

There are several reported cases of cancers in patients with SI. A significantly high number of all the cancers that have been reported in patients with SIT have been from the gastrointestinal tract. Some of those have had much rarer forms of SIT like situs ambiguus, and polysplenia syndrome. There are also a handful of reports of double cancer involving different parts of the gut in patients with SIT. Amongst the patients with Kartagener syndrome there was a higher prevalence of lung cancer.

Although RCC is more commonly associated with other congenital syndromes such as Von Hippel-Lindau syndrome [9], hereditary papillary RCC [10], Birt-Hogg-Dube syndrome [11], there have been only four reported cases with SIT. Three of the previously reported RCC patients with SIT were cured with radical nephrectomy [12, 13]. Meticulous preoperative anatomical and vascular mapping and special precautions for airway management can overcome the surgical challenge posed by the presence of multiple anatomical anomalies and altered position of the blood vessels. Only one patient previously has received adjuvant chemotherapy with intramuscular interferon alfa and external beam radiation [14]. The presence of extensive metastatic disease, poor performance status and patient choices precluded more aggressive treatment choices in our case. There are no reports that confirm or refute the hypothesis that there is a causal association between situs inversus and the development of cancer.

## CONCLUSION

Situs inversus is a rare congenital abnormality with an autosomal recessive inheritance pattern. In addition to renal anomalies and Kartagener syndrome, several types of malignancies co-exist in patients with situs inversus. RCC occurring in patients with situs inversus is a rare phenomenon and the association between these two conditions is unclear. Further study is needed to characterize the genetic basis of SI and establish whether there is a causal basis between SI and the development of malignancy.

\*\*\*\*\*

## Acknowledgement

The authors are grateful to Dr. Julian Crasta, M.D. Pathology for assistance with the pathological slides.

## Author Contributions

Sunil Rangarajan – Conception, design, and acquisition of data, Drafting of the article, Final approval of the version to be published

Bhuvana Sunil – Conception, design, and acquisition of data, Drafting of the article, Final approval of the version to be published

Arun S Shet – Conception and design, Critical revision of the article, Final approval of the version to be published

## Guarantor

The corresponding author is the guarantor of submission.

## Conflict of Interest

Authors declare no conflict of interest.

## Copyright

© Sunil Rangarajan et al. 2012; This article is distributed under the terms of Creative Commons Attribution 3.0 License which permits unrestricted use, distribution and reproduction in any means provided the original authors and original publisher are properly credited. (Please see [www.ijcasereportsandimages.com/copyright-policy.php](http://www.ijcasereportsandimages.com/copyright-policy.php) for more information.)

## REFERENCES

1. Abossolo T, Alessandri JL, Saltet A, Dancoisne P, Pilorget H, Sommer JC. [In utero diagnosis of situs abnormalities. A case of prenatal diagnosis of visceral situs inversus with corrected transposition of great vessels]. *J Gynecol Obstet Biol Reprod (Paris)* 1996;25(3):267–3.
2. European Network of Cancer Registries. Eurocim version 4.0. European incidence database V2.3, 730 entity dictionary 2001.
3. Lina Liu, Junqi Qian, Harpreet Singh, Isabelle Meiers, Xiaoge Zhou, David G Bostwick. Immunohistochemical analysis of chromophobe renal cell carcinoma, renal oncocytoma, and clear cell carcinoma: an optimal and practical panel for differential diagnosis. *Arch Pathol Lab Med* 2007 Aug;131(8):1290–7.
4. Casanova MS, Tuji FM, Yoo HJ, Haiter-Neto F. Kartagener syndrome. Dentomaxillofac. *Radiol* 2006;35(5):386–9.
5. Chmura K, Chan ED, Noone PG, et al. A middle-aged woman with recurrent respiratory infections. *Respiration* 2005;72(4):427–30.
6. Karaman A, Binici DN, Günes N, Doru I, Kabalar ME, Kurt A. A case with balanced reciprocal translocation t(5;11)(q32;q24.2) and situs inversus viscerum. *Genet Couns* 2010;21(2):237–42.
7. Reddy KS, Flannery D, Farrer RJ. Microdeletion of chromosome sub-band 2q37.3 in two patients with abnormal situs Viscerum. *Am J Med Genet* 1999 Jun 11;84(5):460–8.
8. Carlen B, Stenram U. Primary ciliary dyskinesia: a review. *Ultrastructural Pathology* 2005;29(3-4):217–20.
9. Lonser RR, Glenn GM, Walther M, et al. von Hippel-Lindau disease. *Lancet* 2003;361(9374):2059–67.
10. Zbar B, Tory K, Merino M, et al. Hereditary papillary renal cell carcinoma. *J Urol* 1994;151(3):561–6.
11. Birt AR, Hogg GR, Dube WJ. Hereditary multiple fibrofolliculomas with trichodiscomas and acrochordons. *Arch Dermatol* 1977;113(12):1674–7.
12. Adler HL, Lerner SP. Renal cell carcinoma and situs inversus viscerum. *J Urol* 1998 Dec;160(6 Pt 1):2141–2.
13. Treiger BF, Khazan R, Goldman SM, Marshall FF. Renal cell carcinoma with situs inversus totalis. *Urology* 1993 May;41(5):455–7.
14. Bertini JE Jr, Boileau MA. Renal cell carcinoma in a patient with situs inversus totalis. *J Surg Oncol* 1987 Jan;34(1):29–31.



CASE REPORT

OPEN ACCESS

# Advanced live intra-abdominal pregnancy with good fetomaternal outcome: A case report

Ritu Sharma, Manju Puri, Monika Madan, SS Trivedi

## ABSTRACT

**Introduction:** An incidence of abdominal pregnancy is 1 in 10,000 live births accounting for 1.4% of all ectopic pregnancies. Abdominal pregnancy occurs due to secondary implantation from an aborted tubal pregnancy or as a result of intra-abdominal fertilization. **Case Report:** This is a rare case report of a 20-year-old primigravida who presented to our hospital at 38 weeks of gestation with advanced live intra-abdominal pregnancy. After confirming the diagnosis, the patient was taken up for emergency laparotomy and a live baby was extracted. Mother and baby were discharged in good health without any perioperative complications. **Conclusion:** The management of advanced abdominal pregnancy remains controversial. Diagnosis and management of advanced abdominal pregnancy is still a challenge to today's medical world. But high index of suspicion aided with imaging studies can help in timely diagnosis of this rare

obstetrical occurrence thereby preventing the associated life-threatening complications.

**Keywords:** Abdominal pregnancy, Advanced abdominal pregnancy, Ectopic pregnancy

\*\*\*\*\*

Sharma R, Puri M, Madan M, Trivedi SS. Advanced live intra-abdominal pregnancy with good fetomaternal outcome: A case report. International Journal of Case Reports and Images 2012;3(11):5–7.

\*\*\*\*\*

doi:10.5348/ijcri-2012-11-209-CR-2

## INTRODUCTION

Abdominal pregnancy, a rare form of ectopic pregnancy, results from implantation in peritoneal cavity exclusive of tubal, ovarian or intraligamentary implantation [1]. It occurs due to secondary implantation from an aborted tubal pregnancy or as a result of intra-abdominal fertilization. According to Centres for Disease Control and Prevention, the estimated incidence of abdominal pregnancy is 1 in 10,000 live births accounting for 1.4% of all ectopic pregnancies [2, 3]. Advanced abdominal pregnancy refers to a situation where the pregnancy continues beyond 20 weeks with a fetus living, or showing signs of having once lived and developed, in mother's abdominal cavity [4]. Despite the availability of medical health facilities worldwide, the cases of advanced abdominal pregnancy associated with high fetomaternal morbidity and mortality are still encountered. Estimated maternal mortality rate is 5 per 1000 cases, about seven to eight times the mortality rate for ectopic in general [2]. The most important causes of maternal death are hemorrhagic shock, pulmonary embolism, coagulopathy, infection and bowel obstruction [5]. In a

Ritu Sharma<sup>1</sup>, Manju Puri<sup>2</sup>, Monika Madan<sup>3</sup>, SS Trivedi<sup>4</sup>  
**Affiliations:** <sup>1</sup>Research Associate, Department of Obs & Gynae, Lady Hardinge Medical College, New Delhi, India; <sup>2</sup>Professor, Department of Obs & Gynae, Lady Hardinge Medical College, New Delhi, India; <sup>3</sup>Ex Assist. Professor, Department of Obs & Gynae, Lady Hardinge Medical College, New Delhi, India; <sup>4</sup>Professor and Head, Department of Obs & Gynae, Lady Hardinge Medical College, New Delhi, India  
**Corresponding Author:** Dr Ritu Sharma, Department of Obstetrics and Gynae, Lady Hardinge Medical College, Shaheed Bhagat Singh Marg, City New Delhi, Pin Code 110001, India, Ph: +919717001590; Email: drritu661@gmail.com

Received: 02 March 2012  
Accepted: 27 April 2012  
Published: 01 November 2012

review, the survival of infants born after 30 weeks was found to be 63% [6] with 20–40% [6, 7] incidence of birth defects due to compression because of the absence of amniotic fluid buffer. Limb deficiencies and central nervous system anomalies are most common malformations while facial or cranial asymmetries and joint abnormalities are most common deformations. The management of advanced abdominal pregnancy remains controversial.

## CASE REPORT

A 20-year-old primigravida presented to emergency department of our hospital at 38 weeks of gestation with complaints of pain in her abdomen off and on and an ultrasound report showing an abdominal pregnancy of 33 weeks. Patient got her regular antenatal check-up at a remote area. She felt quickening at 16th week of gestation. During her antenatal period she had occasional episodes indigestion and dull pain in abdomen. She was admitted at 22nd week of pregnancy for pain in abdomen associated with difficulty in micturition and was managed conservatively. She underwent an abdominal ultrasound examination at 19th week of gestation which showed live intrauterine pregnancy with placenta covering the internal os. A repeat abdominal ultrasound examination was done at 37th week of gestation. During this examination, abdominal pregnancy was suspected and she was referred to a tertiary hospital. General physical examination and systemic examination other than abdominal examination were unremarkable. On clinical examination of abdomen, fundal height was 34 weeks with longitudinal lie and breech presentation. Fetal parts were palpable superficially. Pelvic grip was empty and fetal heart rate was 140/min and regular.

A repeat abdominal ultrasound examination was done in our hospital which showed empty uterus deviated to left side with a single live fetus seen outside uterine cavity in transverse lie with adequate amniotic fluid in the amniotic sac surrounding it. Placenta was lying next to uterus with marked increase in vascularity in it and adjacent myometrium. Patient's hemoglobin was 11 g/dL with normal liver and kidney function tests. Four units of packed red blood cells were kept cross matched. Patient was taken up for emergency exploratory laparotomy under general anaesthesia on the same day. Abdomen was opened by right para median vertical incision extending above umbilicus. Per operatively omentum was seen covering an amniotic sac. The membranes were thick and were ruptured. Meconium stained liquor was drained out. A live baby girl was extracted as breech (Figures 1 and 2). The cord was doubly clamped, cut and tied close to its placental attachment. Birth weight was 1.5 kg and Apgar score was 9 and 9 at 1 and 5 minutes respectively. The exploration of abdomen for exact placental localization was avoided as this could have incited torrential hemorrhage. Placenta was left undisturbed. Thorough saline wash was done. Abdomen was closed in layers.

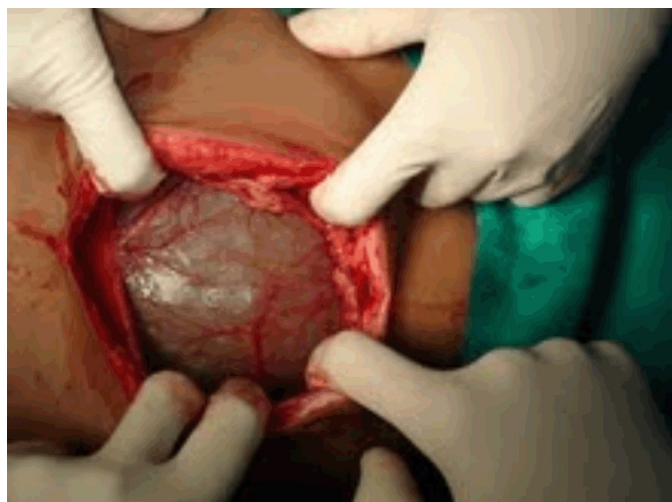

Figure 1: Intact amniotic sac containing fetus in abdominal cavity.

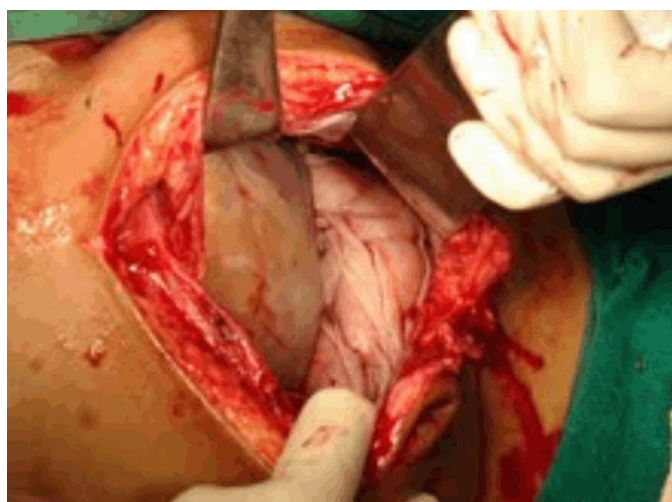


Figure 2: Membranes covering abdominal organs after extracting fetus.

The amount of surgical blood loss did not warrant any blood transfusion.

Patient stood the procedure well and remained hemodynamically stable. Her postoperative period was uneventful. Mother and baby were discharged in good health. Patient came for follow-up after one month with no fresh complaints. Abdominal ultrasound examination during follow-up visit showed involuting placental mass lying in the abdominal cavity surrounded by intestines. Postoperative counseling of the couple was done giving emphasis on contraception and need for early antenatal check ups in subsequent pregnancies.

## DISCUSSION

Diagnosis and management of advanced abdominal pregnancy is still a challenge to today's medical world. But high index of suspicion aided with imaging studies can help in timely diagnosis of this rare obstetrical occurrence thereby preventing the associated life-



threatening complications. Patient may present with complaints of vaginal bleeding, persistent abdominal pain and painful fetal movements. On examination, there may be abnormal presentation, easily palpable fetal parts, uneffaced and displaced cervix and palpation of abdominal mass separate from uterus [8]. High index of suspicion is first step in the diagnosis. Increased maternal serum alpha fetoprotein levels add to the suspicion [4]. Ultrasonography and MRI are diagnostic modalities for confirmation of abdominal pregnancy [8]. Ultrasound will show empty uterus, absence of amniotic fluid between placenta and fetus, absence of myometrium between bladder and gestation and abnormal lie with fetal parts close to abdominal wall [4, 8, 9]. But sonographic diagnosis is missed in half of the cases [4]. Despite all, the diagnosis in most of the cases is made at time of surgery only.

Advanced abdominal pregnancy is difficult to manage. If the fetus is mature, immediate laparotomy is the definitive management but if fetus is immature and mother is in good health, one can opt for conservative management with strict surveillance giving mother's safety the primary importance. After delivering baby, the management of placenta is also controversial due to diffuse and unidentifiable blood supply of abnormally implanted placenta. Life-threatening hemorrhage during laparotomy is the main concern. If one cannot identify and ligate the vascular supply of placenta, it is preferable to leave it as such for natural regression [5] which can be monitored by  $\beta$ -hCG levels and ultrasonography—the process taking several months. Methotrexate administration can lead to massive necrosis and subsequent infection [5]. Angiographic embolisation can be used to block placental vessels [10].

## CONCLUSION

It needs emphasis again that both obstetricians and radiologists should improve their skills further to diagnose these cases in time so that they do not reach to such an advanced stage where management itself becomes difficult.

\*\*\*\*\*

## Author Contributions

Ritu Sharma – Substantial contributions to conception and design, Acquisition of data, Analysis and interpretation of data, Drafting the article, Revising it critically for important intellectual content, Final approval of the version to be published

Manju Puri – Substantial contributions to conception and design, Acquisition of data, Analysis and interpretation of data, Drafting the article, Revising it critically for important intellectual content, Final approval of the version to be published

Monika Madan – Substantial contributions to conception and design, Acquisition of data, Analysis and interpretation of data, Drafting the article, Revising it

critically for important intellectual content, Final approval of the version to be published

SS Trivedi – Substantial contributions to conception and design, Acquisition of data, Analysis and interpretation of data, Drafting the article, Revising it critically for important intellectual content, Final approval of the version to be published

## Guarantor

The corresponding author is the guarantor of submission.

## Conflict of Interest

Authors declare no conflict of interest.

## Copyright

© Ritu Sharma et al. 2012; This article is distributed under the terms of Creative Commons Attribution 3.0 License which permits unrestricted use, distribution and reproduction in any means provided the original authors and original publisher are properly credited. (Please see [www.ijcasereportsandimages.com/copyright-policy.php](http://www.ijcasereportsandimages.com/copyright-policy.php) for more information.)

## REFERENCES

1. Cunningham, Levono. William's Obstetrics. Twenty third edition, 2010; Ectopic pregnancy, chapter 10, p 249.
2. Atrash HK, Friede A, Hogue CJR. Abdominal pregnancy in United States: Frequency and Maternal Mortality. *Obstetrics Gynecology* March 1987;63(3):333–7.
3. Bouyer J, Coste J, Fernandez H, Pouly JL, Job-Spira N. Sites of ectopic pregnancy: a 10 year population based study of 1800 cases. *Human Reproduction* 2002;17:3224–30.
4. Worley KC, Hnat MD, Cunningham FG. Advanced extra-uterine pregnancy; diagnostic and therapeutic challenges. *Am J Obstet Gynecol* 2008 Mar;198(3):297.e1–7.
5. Jonathan S. Berek, MD, MMS. Early pregnancy loss and ectopic pregnancy. Berek and Novak's *Gynecology*, fifteenth edition 2012. Chapter 20;644:628.
6. Stevens CA. Malformations and deformations in abdominal pregnancy. *American Journal of medical genetics* 1993;47(8):1189–5.
7. Rahman MS, Al-Suleiman SA, Rahman J, Al-Sibai MH. Advanced abdominal pregnancy—observations in 10 cases. *Obstetrics Gynecology* 1982;59:366–72.
8. AY Isah, Y Ahmed, EL Newbode, BA Ekele. Abdominal pregnancy with a full term live fetus: case report. *Annals of African Medicine* 2008;4(7):198–9.
9. Bertrand G, Le Ray C, Simard-Emond L, Dubois J, Leduc L. Imaging in the management of abdominal pregnancy: A case report and review of literature. *J Obstet Gynaecol Can* 2009 Jan;31(1):57–62.
10. Cardosi RJ, Nackley AC, Londono J, Hoffman MS. Embolisation for advanced abdominal pregnancy with a retained placenta. A case report. *Reproductive medicine* 2002 Oct;47(10):861–3.

CASE REPORT

OPEN ACCESS

# Hepatic hemangioma and focal nodular hyperplasia in a Nigerian patient with hepatitis B virus infection

Aderemi O Oluyemi, Adekunle O Adeyomoye, Nicholas A Awolola

## ABSTRACT

**Introduction:** Hepatic hemangiomas (HH) and focal nodular hyperplasia (FNH) are, by far singly and combined together, the most frequently occurring benign liver lesions. The association between these two tumors is well documented in literature. The association has been suggested to spring from a common etiopathogenetic mechanism. **Case Report:** A 42-year-old male presented for evaluation as a routine pre-blood donation screen had shown that he was hepatitis B surface antigen (HBsAg) positive. An abdominal ultrasonography showed two distinct hyperechogenic intrahepatic masses. One mass was diagnosed with doppler ultrasound as hemangioma and a ultrasound-guided biopsy of the other mass revealed hepatocellular hyperplasia. **Conclusion:** This case for the first time documents the interesting HH/FNH association from Nigeria. It also details what, to the best of our knowledge, is the first time that these diseases are being documented as coexisting with hepatitis B virus (HBV) infection.

**Keywords:** Focal nodular hyperplasia, Hepatic hemangioma, Hepatitis B infection, Nigeria

Aderemi O Oluyemi<sup>1</sup>, Adekunle O Adeyomoye<sup>2</sup>, Nicholas A Awolola<sup>3</sup>

**Affiliations:** <sup>1</sup>General Hospital, Ikorodu, Lagos State, Nigeria; <sup>2</sup>Department of Radiodiagnosis, College of Medicine, University of Lagos, Idi-Araba, Lagos State, Nigeria; <sup>3</sup>Department of Morbid Anatomy, College of Medicine, University of Lagos, Idi-Araba, Lagos State, Nigeria.

**Corresponding Author:** Dr. Aderemi O Oluyemi, General Hospital, Ikorodu, Lagos State, Nigeria; Email: remioluyemi@yahoo.com

Received: 03 March 2012

Accepted: 17 May 2012

Published: 01 November 2012

\*\*\*\*\*

Oluyemi AO, Adeyomoye AO, Awolola NA. Hepatic hemangioma and focal nodular hyperplasia in a Nigerian patient with hepatitis B virus infection. International Journal of Case Reports and Images 2012;3(11):8–10.

\*\*\*\*\*

doi:10.5348/ijcri-2012-11-210-CR-3

## INTRODUCTION

Hepatic hemangiomas (HH) and focal nodular hyperplasia (FNH) are, singly and combined, by far the most frequently occurring benign liver lesions. The common presence of these two hepatic lesions is well documented in literature and it has been suggested that this association springs from a common etiopathogenetic mechanism of growth and development. However, such documentations have not been common in data from the Western sub-region of Africa. This interesting association has not been documented from Nigeria and to the best of our knowledge, nor has there been a previous report of HH and FNH as coexisting with hepatitis B virus (HBV) infection anywhere in literature.

## CASE REPORT

A 42-year-old male presented for evaluation as a routine pre-blood donation screen had shown that he was hepatitis B surface antigen (HBsAg) positive. He did not have a previous history of liver disease nor diabetes mellitus and was asymptomatic at presentation. His body mass index was 22.6 kg/m<sup>2</sup> and other examination findings were unremarkable. Liver function tests including serum  $\alpha$ -fetoprotein and carcinoembryonic antigen levels were normal. The quantification of HBV

deoxyribonucleic acid (DNA) levels from patient's serum was less than 20 IU/per mL (COBAS TaqMan kit) and a screen for hepatitis C virus was negative. Fasting samples were drawn for blood glucose and lipid profile and results were normal. An abdominal ultrasonography (USG) showed two distinct hyperechogenic intrahepatic masses. The first was an 8.7 mm in diameter nodule in segment VIII which on color flow Doppler ultrasound mode showed flow into and within the mass. These features were in keeping with a hemangioma. The second lesion seen in segment II was 12 mm in diameter and on color Doppler, demonstrated no flow within the mass (Figure 1). The differentials of the second mass included early hepatocellular carcinoma, a focal fatty infiltration, hepatic adenoma and focal nodular hyperplasia.

The histologic assessment of tissue obtained from a ultrasound-guided liver biopsy of the second mass revealed nodules of proliferating hepatocytes arranged in two cell layers which were supported by well developed reticulin framework. The hepatocytes were pale but showed no evidence of fatty change. The hepatic nodules were separated by fibrous septa containing several vessels, including small arteries and veins as well as numerous ductules (Figures 2 and 3). Hence, a diagnosis was made of Hemangioma and Focal Nodular Hyperplasia in a patient with HBV infection was made. The patient was subsequently informed and appropriately counseled. He is presently on regular follow up at a hepatology outpatient unit.

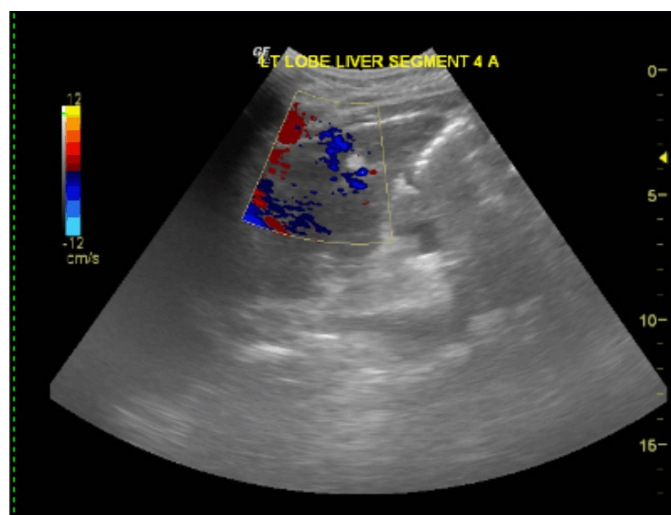


Figure 1: Color flow Doppler showing hyperechoic nodule in left lobe of the liver (segment 2). Note that there is no flow within the nodule.

## DISCUSSION

Hepatic hemangioma and FNH lesions are the two most common liver cell-derived benign tumors and are estimated to be present in 0.4–20% and 8% of general adult population from the western world [1–3]. While each of these lesions are found commonly as isolated entities, an association between HH and FNH has also

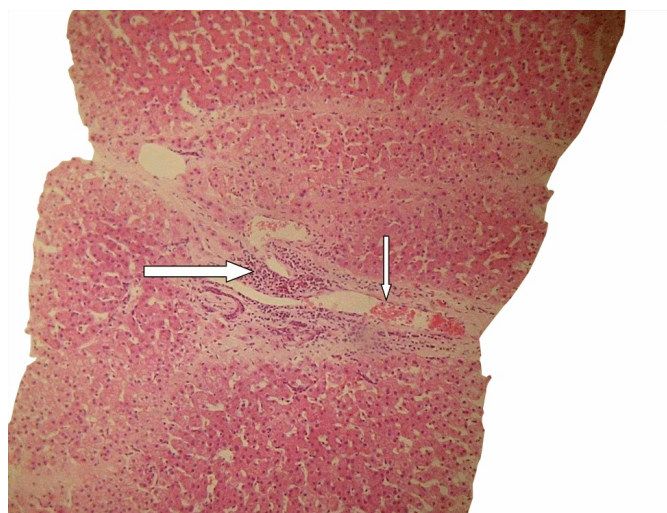

Figure 2: Focal Nodular Hyperplasia: Photomicrograph showing central scar with blood vessels and fibrous septa separating cirrhosis-like nodules of hepatocytes. There is a large central artery (vertical arrow) with inflammatory cell infiltrates (horizontal arrow) and numerous ductules (H&E ×40).

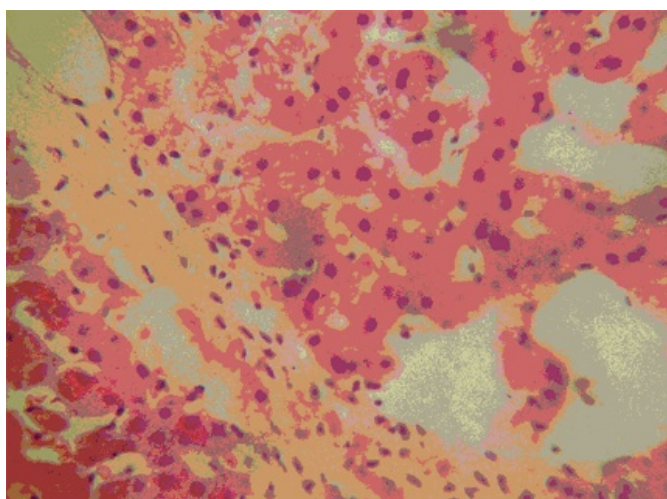


Figure 3: Focal Nodular Hyperplasia: Photomicrograph showing bile stasis (black arrow) at junction between septa and liver parenchyma (H&E ×400).

been well documented in literature [1, 4, 5]. While coexisting third lesions such as adenomas [6] and liver cysts [7] have been reported in association with these two pathologies, to the best of our knowledge this is the first documented case of such association from Nigeria and is the first time that these two lesions are being presented in association with HBV infection.

The association between HH and FNH hinges around the presumed etiopathogenetic mechanisms that relates to local abnormalities in hepatic blood supply that somehow facilitate the hyperplastic development of these benign lesions [4]. Their shared property of development/growth with the intake of oral contraceptives has also been pointed out in support of this relationship [6, 8]. Literature is, however, void of a



suggestion of explanation of a possible association between HBV infection and these tumors.

## CONCLUSION

We surmise that this relationship may simply represent a fortuitous one as Nigeria is a region of high endemicity for HBV infection (> 8%) with an estimated lifetime risk of infection being greater than 50% [9]. The probability such of coincidental coincidence is high. Granted that the presence of HBV infection may or may not be important from an etiopathogenetic standpoint, it is, however, pertinent to note that this relationship can exist in patients with HBV infection. A piece of information that could have various ramifications in the evaluation of hepatic lesions in HBV infection particularly in regions of high endemicity.

\*\*\*\*\*

## Acknowledgements

The article has been read by the patient and written consent obtained for publication. We would like to thank the management of Foremost Radiology, and The Specialist Labs both in Surulere, Lagos State, Nigeria for carrying out the ultrasonography and histopathologic assessment respectively.

## Author Contributions

Aderemi Oluyemi – Initial conception and design, Drafting the article, Critical revision of the article  
Adekule Adeyomoye – Contributed substantially in the design of the report. He provided the abdominal ultrasonography, guided the liver biopsy and Critical revision of this case report

Nicholas Awolola – Contributed substantially in the design of the report. He provided the histology for the report and made critical revisions to the article content

## Guarantor

The corresponding author is the guarantor of submission.

## Conflict of Interest

Authors declare no conflict of interest.

## Copyright

© Aderemi Oluyemi et al. 2012; This article is distributed under the terms of Creative Commons Attribution 3.0 License which permits unrestricted use, distribution and reproduction in any means provided the original authors and original publisher are properly credited. (Please see [www.ijcasereportsandimages.com/copyright-policy.php](http://www.ijcasereportsandimages.com/copyright-policy.php) for more information.)

## REFERENCES

1. Wanless IR. Micronodular transformation (nodular regenerative hyperplasia) of the liver: a report of 64

cases among 2,500 autopsies and a new classification of benign hepatocellular nodules. *Hepatology* 1990;11(5):787–97.

2. Edmondson HA. Tumors of the liver and intrahepatic bile ducts. In: Atlas of tumor pathology. First series. Washington, DC: Armed Forces Institute of Pathology 1958.
3. Karhunen PJ. Benign hepatic tumors and tumor like conditions in men. *J Clin Pathol* 1986;39(2):183–8.
4. Mathieu D, Zafrani ES, Anglade MC, Dhumeaux D. Association of focal nodular hyperplasia and hepatic hemangioma. *Gastroenterology* 1989;97(1):154–7.
5. Vilgrain V, Uzan F, Brancatelli G, Federle MP, Zappa M, Menu Y. Prevalence of Hepatic Hemangioma in Patients with Focal Nodular Hyperplasia: MR Imaging Analysis. *Radiology* 2003;229(1):75–9.
6. Di Carlo I, Urrico GS, Ursino V, Russello D, Puleo S, Latteri F. Simultaneous occurrence of adenoma, focal nodular hyperplasia, and hemangioma of the liver: are they derived from a common origin? *J Gastroenterol Hepatol* 2003;18(2):227–30.
7. Toshikuni N, Kawaguchi K, Miki H, et al. Focal nodular hyperplasia coexistent with hemangioma and multiple cysts of the liver. *J Gastroenterol* 2001;36(3):206–11.
8. Scalori A, Tavani A, Gallus S, La Vecchia C, Colombo M. Oral contraceptives and the risk of focal nodular hyperplasia of the liver: a case-control study. *Am J Obstet Gynecol* 2002;186(2):195–7.
9. Lavanchy D. Hepatitis B Virus Epidemiology, Disease Burden, Treatment, and Current and Emerging Prevention and Control Measures. *J Viral Hepat* 2004;11(2):97–107.

CASE REPORT

OPEN ACCESS

# Intraparotid lymph node with metastatic angiosarcoma: A rare tumor with a routine presentation

Hiten Joshi, David McPartlin

## ABSTRACT

**Introduction:** We present an unusual case presenting as a parotid tumor in a Caucasian man, including our management and a review of literature. **Case Report:** A 83-year-old male was referred to the ENT department with a non-painful swelling in front of his right ear. This was diagnosed as a likely Warthin's tumor and this was further supported by ultrasound imaging. Fine needle aspiration cytology was non-diagnostic. The patient underwent superficial parotidectomy for histological confirmation. Histology identified an intraparotid lymph node with metastatic angiosarcoma. The primary source was not identified. The patient was further treated with adjuvant radiotherapy and at a 10-month post-therapy review there is no evidence of reoccurrence. **Conclusion:** An angiosarcoma is a rare malignant neoplasm of endothelial-type that is characterized by rapidly proliferating and infiltrating anaplastic cells. Angiosarcoma's account for less than 0.1% of all head and neck cancers and it is extremely rare for the major salivary glands to be affected; 80% of all parotid tumors are benign. Metastatic angiosarcoma arising in an intraparotid lymph node has not previously been reported in English journals. This presented case is unusual in its location and its mode of presentation.

Hiten Joshi<sup>1</sup>, David McPartlin<sup>2</sup>

**Affiliations:** <sup>1</sup>ENT ST2 Trainee, ENT Department, Queen Elizabeth Hospital, King's Lynn, United Kingdom; <sup>2</sup>ENT Consultant, ENT Department, Queen Elizabeth Hospital, King's Lynn, United Kingdom.

Corresponding Author: ENT Department, Queen Elizabeth Hospital, King's Lynn, United Kingdom, PE30 4ET; Ph: 0044 7736046373, Email: hitenjoshi@doctors.org.uk

Received: 19 March 2012

Accepted: 07 May 2012

Published: 01 November 2012

**Keywords:** Intraparotid, Angiosarcoma, Warthin's, Metastatic

\*\*\*\*\*

Joshi H, McPartlin D. Intraparotid lymph node with metastatic angiosarcoma: A rare tumor with a routine presentation. International Journal of Case Reports and Images 2012;3(11):11–13.

\*\*\*\*\*

doi:10.5348/ijcri-2012-11-211-CR-4

## INTRODUCTION

An angiosarcoma is a rare malignant neoplasm of endothelial-type that is characterized by rapidly proliferating and infiltrating anaplastic cells. Angiosarcoma affecting the soft tissues commonly affects the extremities, retroperitoneum and abdominal wall and cutaneous angiosarcoma of the scalp and face is the most common form of angiosarcoma [1, 2]. Although approximately 50% of angiosarcomas occur in the head and neck region, they represent less than 0.1% of all head and neck malignancies and there are very few published cases occurring within the parotid gland [3]. Often these tumors are initially mistaken for other pathology on clinical grounds with diagnosis only made after surgical resection is complete.

## CASE REPORT

An 83-year-old male was initially referred to the oral and maxillofacial surgeons with a swelling on the right side of his mouth and in front of his ear. The patient's complaint was of a painless swelling that was growing over a period of two months. There was no history of discharge in the mouth, weight loss or anorexia. He was referred to the ENT department with an initial diagnosis



of a pleomorphic adenoma. ENT review identified a right parotid swelling and there was no facial nerve palsy (House-Brackmann grade I). Following this, the patient was given a diagnosis of a likely Warthin's tumor on clinical grounds. His past medical history consisted of two basal cell carcinomas (BCC); one on the chest and one on the right lower leg in the last 6 years. He also suffered from type 2 diabetes, hypertension, and angina.

The patient underwent an ultrasound scan which identified features consistent with a Warthin's tumor and a fine-needle aspirate (FNA) performed was reported as highly suggestive of neoplasia of an indeterminate type. The patient was consented for a superficial parotidectomy for histological diagnosis and this was performed successfully with full preservation of facial nerve function. The patient was discharged on the first postoperative day and reviewed in clinic with results of the histology. Provisional histology results identified an encapsulated neoplasm with lymphoid tissue present at the edges and thus identifying an intraparotid lymph node. Microscopy identified appearances of an unusual malignant spindle cell neoplasm. Immunohistochemical staining was positive for CD34 and vimentin. The specimen was reviewed at the regional head and neck unit and confirmed a diagnosis of an intraparotid lymph node with metastatic angiosarcoma (Figure 1).

The patient was reviewed by the oncologists and further investigations in the form of staging CT scanning identified no primary site. He underwent 20 doses of adjuvant radiotherapy over a four-week period and a 10-month post-radiotherapy there is no clinical evidence of recurrence.

## DISCUSSION

The parotid gland is the most common site for salivary gland tumors of which 80% are benign. The commonest benign tumors are the pleomorphic adenoma (80%), followed by Warthin's tumor [4]. Malignant parotid tumors are rare with pathologies including mucoepidermoid carcinoma, adenoid cystic carcinoma, adenocarcinoma, malignant degeneration of a pleomorphic adenoma and, squamous cell carcinoma.

Angiosarcomas most commonly occur in skin and soft tissue [2]. They account for less than 0.1% of all head and neck malignancies and it is extremely rare for the major salivary glands to be affected [3]. These tumors are rare malignant neoplasms of endothelial-type cells that line vessel walls; characterized by rapidly proliferating anaplastic cells that infiltrate extensively. Presentation often consists of a moderately paced growing mass associated with compression of adjacent neurovascular structures. There may be systemic features. For example, bleeding and thrombocytopenia, characteristic of a malignant vascular proliferation [5, 6]. This case is unique in that the patient had no other symptoms apart from the swelling occurring over a five month period. On review of literature, we identified

seven cases of angiosarcoma involving the parotid gland and no cases of metastatic angiosarcoma arising in an intraparotid lymph node [7, 8, 9].

The diagnosis of a vascular tumor can often be made with the aid of CT or MRI imaging and biopsy in the form of a FNA or core biopsy [10]. Imaging can also aid in the detection of metastases which can occur in up to 50% of cases. Metastases are most commonly seen locally in the regional lymph nodes or distantly in the lungs, liver, or spleen, and sometimes in the both regions.

Studies have shown the 5-year survival of angiosarcoma can vary from 12–41% [5, 6, 11]. The mainstay of therapy is surgical resection with either pre- or postoperative radiotherapy. Tumor site has shown to be prognostically significant in several studies, for example, Morrison et al. demonstrated poor survival in patients with angiosarcoma of the scalp [12]. There is little evidence available demonstrating survival rates in patients presenting with an unknown primary but survival rates have been shown to be associated with early surgical resection prior to local or distant spread [5].

At present there are no clear guidelines on the management of head and neck metastatic angiosarcoma from an unknown primary. Surgical resection and radiotherapy are currently the treatment options with the role of chemotherapy not fully established in the various forms of angiosarcoma [1, 13]. Due to the rarity

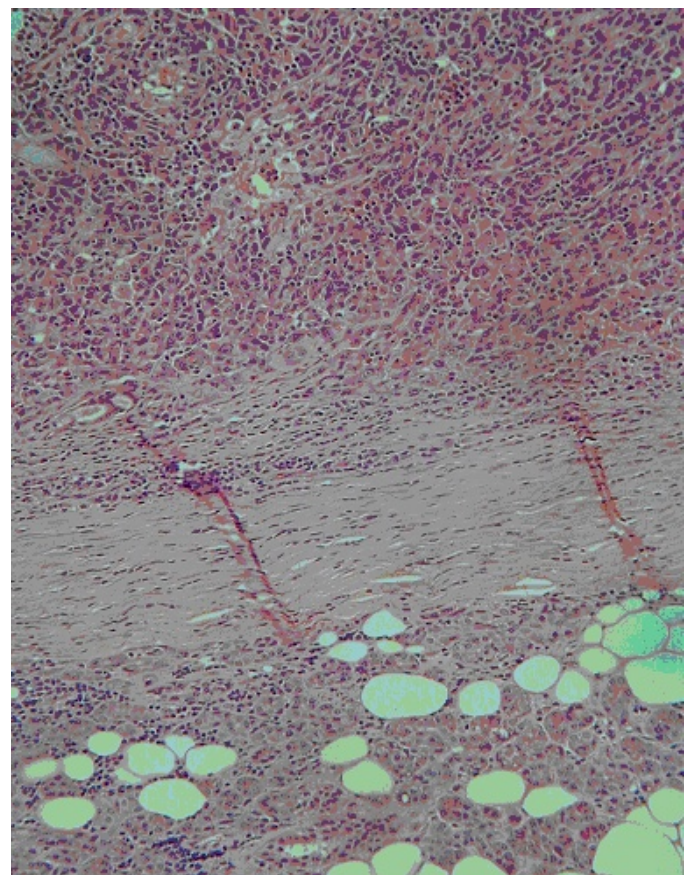


Figure 1: Histology slide of the angiosarcoma at high power using H&E staining.

of the pathology, we sought advice from the UK National Sarcoma Unit and our patient underwent adjuvant radiotherapy.

## CONCLUSION

Intraparotid angiosarcoma is a very rare pathology which may present through a routine head and neck lump clinic. We present an unusual presentation of such a lesion.

\*\*\*\*\*

## Author Contributions

Hiten Joshi – Conception and design, Acquisition of data, Analysis and interpretation of data, Drafting the article, Critical revision of the article, Final approval of the version to be published

David McPartlin – Critical revision of the article, Final approval of the version to be published

## Guarantor

The corresponding author is the guarantor of submission.

## Conflict of Interest

Authors declare no conflict of interest.

## Copyright

© Hiten Joshi et al. 2012; This article is distributed under the terms of Creative Commons Attribution 3.0 License which permits unrestricted use, distribution and reproduction in any means provided the original authors and original publisher are properly credited. (Please see [www.ijcasereportsandimages.com/copyright-policy.php](http://www.ijcasereportsandimages.com/copyright-policy.php) for more information.)

## REFERENCES

1. Meis-Kindblom JM, Kindblom LG. Angiosarcoma of soft tissue: a study of 80 cases. *Am J Surg Pathol* 1998;22(6):683–97.
2. Morgan MB, Swann M, Somach S, et al. Cutaneous angiosarcoma: a case series with prognostic correlation. *J Am Acad Dermatol* 2004;50(6):867–4.
3. Sturgis EM, Potter BO. Sarcomas of the head and neck region. *Curr Opin Oncol* 2003;15(3):239–52
4. Lalwani AK. Current diagnosis & treatment otolaryngology head and neck surgery. In: Lalwani AK editors, 3rd ed. McGraw Hill 2012:p 328–9.
5. Mark RJ, Poen JC, Tran LM, Fu YS, Juillard GF. Angiosarcoma. A report of 67 patients and a review of the literature. *Cancer* 1996;77(11):2400–6.
6. Maddox JC, Evans HL. Angiosarcoma of skin and soft tissue: a study of forty-four cases. *Cancer* 1981;48:1907–21.
7. Julie C. Fanburg-Smith, Mary A. Furlong, Esther LB. Childers. Oral and Salivary Gland Angiosarcoma: A Clinicopathologic Study of 29 Cases *Mod Pathol* 2003;16(3):263–71
8. Mullick SS, Mody DR, Schwartz MR. Angiosarcoma at unusual sites: a report of two cases with aspiration cytology and diagnostic pitfalls. *Acta Cytol* 1997;41:839–44.
9. Perez del Rio MJ, Garcia-Garcia J, Diaz-Iglesias JM, Frasnó MF. Radiation-associated angiosarcoma involving the parotid gland. *Histopathology* 1998;33:586–7.
10. Sugita R, Takezawa M, Itinohasama R. Primary angiosarcoma of the chest wall: CT and MR findings. *Radiation Medicine* 2002;20(2):101–3.
11. Aust MR, Olsen KD, Lewis JE, et al. Angiosarcomas of the head and neck: clinical and pathologic characteristics. *Ann Otol Rhinol Laryngol* 1997;106:943–51.
12. Morrison WH, Byers RM, Garden AS, Evans HC, Ang KK, Peters LJ. Cutaneous angiosarcoma of the head and neck: a therapeutic dilemma. *Cancer* 1995;76:319–27.
13. Budd GT. Management of Angiosarcoma. *Curr Oncol Rep* 2002;4(6):515–9.

CASE REPORT

OPEN ACCESS

# Octreotide induced thrombocytopenia

Haroon Yousaf, Irfan Saddique

## ABSTRACT

**Introduction:** Thrombocytopenia due to octreotide is a rare but known phenomenon. Only three cases of octreotide induced thrombocytopenia have been reported so far. **Case Report:** Here we report a case of a 76-year-old diabetic male who was brought to the emergency room after being found unconscious. In the ER, his blood glucose level was 43 mg/dL. He was taking glyburide 5 mg by mouth daily prior to admission. Escalated dextrose infusion with repeated doses of D50W failed to sustain his blood glucose, which remained in the range of 30 to 50 mg/dL. Salvage treatment with intravenous octreotide was implemented successfully; only one dose of D50W was required after octreotide initiation and blood glucose normalized within several hours. However, a significant drop in patient's platelet count was noted after initiation of octreotide therapy, that persisted until the drug was discontinued. Rapid recovery was observed after discontinuation of octreotide. **Conclusion:** High degree of suspicion is warranted on the part of physicians to suspect octreotide as a causative factor for thrombocytopenia. We suggest that octreotide be discontinued when thrombocytopenia occur, once other known causes of thrombocytopenia have been excluded.

**Keywords:** Octreotide, Thrombocytopenia, Drug toxicity

\*\*\*\*\*

Yousaf H, Saddique I. Octreotide induced thrombocytopenia. International Journal of Case Reports and Images 2012;3(11):14–16.

\*\*\*\*\*

doi:10.5348/ijcri-2012-11-212-CR-5

## INTRODUCTION

Thrombocytopenia due to octreotide is a rare but known phenomenon. Only three cases of octreotide induced thrombocytopenia have been reported so far [1–3]. The diagnosis of this critical condition is based on clinical suspicion and is a diagnosis of exclusion. We report a case of octreotide-induced reversible thrombocytopenia in a diabetic patient who presented with hypoglycemia.

## CASE REPORT

A 76-year-old male was in his usual state of health until three days prior to presentation when he had an episode of documented hypoglycemia with loss of consciousness. His medical history consisted of diabetes mellitus, for which he was taking glyburide 1 mg by mouth daily for two years, prior to admission. The day of the event he went on a walk with wife. Six hours after his breakfast of cereal he began to feel lightheaded and then lost consciousness, which was witnessed by his wife. The patient has no recollection of the event, but denies any preceding vision changes, warmth, sweating anxiety, weakness, nausea or palpitations. His wife denies witnessing any muscle contractions or seizure

Haroon Yousaf<sup>1</sup>, Irfan Saddique<sup>2</sup>

**Affiliations:** <sup>1</sup>Theda Clark Hospital, Neenah, WI, USA;

<sup>2</sup>Interfaith Medical Center, Brooklyn, New York, USA.

**Corresponding Author:** Haroon Yousaf, Theda Clark Hospital, 130 2nd Street, Neenah, WI 54956 USA; Ph: 920-729-3100; Email: drhy@hotmail.com

Received: 08 August 2011

Accepted: 03 March 2012

Published: 01 November 2012



activity during the episode. Emergency medical services were called in. When the paramedics arrived, the patient had a serum glucose value of 54 mg/dL. He was taken to the emergency room of a local hospital and found to have a serum glucose of 43 mg/dL. He was given one ampule of 50% dextrose, resulting in significant improvement in his mental status. His initial vital signs revealed blood pressure of 111/73 mmHg, heart rate of 99/minute, respiratory rate of 22/minute, and 100% oxygen saturation on room air. His neck was supple. Examination of the lungs revealed bilateral good air entry. Cardiac examination demonstrated normal first and second heart sounds with a regular rhythm and no murmurs. His abdomen was soft and non tender and his extremities were warm and dry. His relevant laboratory findings were hemoglobin 13 g/dL, platelets 160,000/mm<sup>3</sup>, International Normalized Ratio 1.1, and mean corpuscular volume 80.9 fL/red blood cell. The patient was then admitted to the hospital for further evaluation of his hypoglycemia. Serum sulfonyleurea screen was noted to be positive. Hypoglycemia persisted over the next 24 hours during the course of her hospital stay despite continuous infusion of 10% dextrose. Salvage treatment with intravenous continuous octreotide 50 mcg/hr infusion was implemented successfully after 24 hours of his hospital stay; only one dose of D50W was required after octreotide initiation and blood glucose normalized within several hours. Nine hours after, starting octreotide infusion the patient's platelet count had decreased to 77,000/mm<sup>3</sup>. Peripheral blood smear did not show any abnormalities. As part of his thrombocytopenia work-up, blood cultures, a disseminated intravascular coagulation panel and heparin-induced antiplatelet antibodies were obtained, all of which came back negative. Octreotide was discontinued 16 hours after admission, with a presumptive diagnosis of drug-induced thrombocytopenia. A quick recovery in the patient's platelet count occurred (Figure 1), and he remained stable and was discharged on sixth day after admission with a platelet count of 104,000/mm<sup>3</sup>. During a follow-

up examination after one week patient denied any bleeding or bruising and his platelet count was noted to be 155,000/mm<sup>3</sup>. The decline in platelet count was only seen after octreotide initiation, with immediate improvement when it was discontinued, leading to our diagnosis of octreotide-induced reversible thrombocytopenia.

## DISCUSSION

In its short-acting preparation, octreotide has been used safely in humans since 1998. Thrombocytopenia is an extremely rare side effect of octreotide therapy. Only three cases of this condition have previously been reported in literature [1, 2, 3]. Platelet count typically falls from 50% of the normal value on exposure to the drug and returns to normal after drug withdrawal. Octreotide causes thrombocytopenia most likely through immunologic phenomena [4], that is, by drug-dependent antibodies causing accelerated platelet destruction by binding to platelet surface glycoproteins [5]. It usually takes one week for platelets to recover following drug discontinuation [6].

## CONCLUSION

We suggest that octreotide be discontinued when thrombocytopenia occur, once other known causes of thrombocytopenia have been excluded.

\*\*\*\*\*

## Author Contributions

Haroon Yousaf – Substantial contributions to conception and design, Acquisition of data, Drafting the article, Revising it critically for important intellectual content, Final approval of the version to be published  
Irfan Saddique – Substantial contributions to conception and design, Analysis and interpretation of data, Drafting the article, Final approval of the version to be published

## Guarantor

The corresponding author is the guarantor of submission.

## Conflict of Interest

Authors declare no conflict of interest.

## Copyright

© Haroon Yousaf et al. 2012; This article is distributed under the terms of Creative Commons Attribution 3.0 License which permits unrestricted use, distribution and reproduction in any means provided the original authors and original publisher are properly credited. (Please see [www.ijcasereportsandimages.com/copyright-policy.php](http://www.ijcasereportsandimages.com/copyright-policy.php) for more information.)

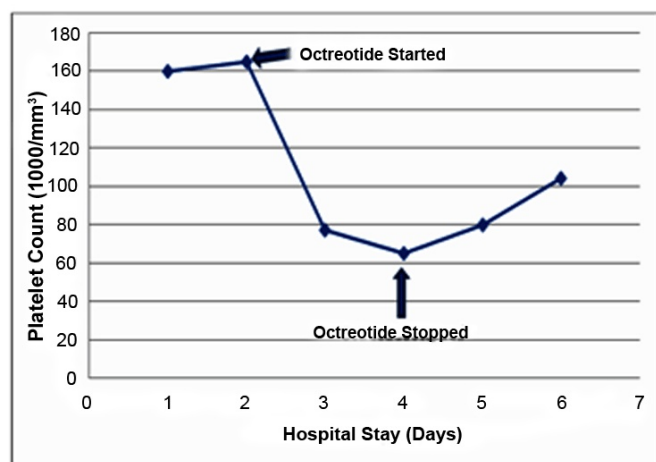


Figure 1: Platelet count during the course of hospitalization.

## REFERENCES

1. Chisholm S, Gummadi B, Vega KJ, House J. Sandostatin causing reversible thrombocytopenia. *Eur J Gastroenterol Hepatol* 2009;21(4):474–5.
2. Demirkan K, Fleckenstein JF, Self TH. Thrombocytopenia associated with octreotide. *Am J Med Sci* 2000;320(4):296–7.
3. Rashidi A, Rizvi N. Octreotide-induced thrombocytopenia: a case report. *J Med Case Reports* 2011 Jul 5;5:286.
4. Aster RH, Bougie DW. Drug-induced immune thrombocytopenia. *N Engl J Med* 2007;357(6):580–7.
5. Christie DJ, Mullen PC, Aster RH. Fab-mediated binding of drug-dependent antibodies to platelets in quinidine- and quinine-induced thrombocytopenia. *J Clin Invest* 1985;75(1):310–4.
6. Pedersen-Bjergaard U, Andersen M, Hansen PB. Drug-induced thrombocytopenia: clinical data on 309 cases and the effect of corticosteroid therapy. *Eur J Clin Pharmacol* 1997;52(3):183–9.



CASE REPORT

OPEN ACCESS

# An uncommon cause of apparent life-threatening event

Muhammad Waseem, Dee Soontharothai, Heidi Pinkert,  
Evelyn Erickson, Michael Trotman

## ABSTRACT

**Introduction:** An apparent life threatening event (ALTE) in infancy is a common reason for presentation to the emergency department (ED). We report a case of a breast-fed infant who presented with an ALTE secondary to hypocalcemia from undiagnosed rickets. **Case Report:** A 9-month-old girl was brought to the ED because she stopped breathing. The parents reported that she stopped breathing for more than 20 seconds and was gasping for air. During the event, she became unresponsive and her eyes rolled back. There was a history of cough and nasal congestion with subjective fever for two days. Further questioning revealed that over the last few months, she had had episodes of 'gasping', and 'strange noisy breathing sounds.' Her mother reported an 'odd cough' for several months. The baby had been exclusively breast-fed and was noted by her mother to be feeding well. No solid foods had been introduced to the patient. The past medical history was significant for developmental delay. The patient was born full-term via normal spontaneous vaginal delivery. The pregnancy, however, had been

complicated by oligohydramnios. The parents reported no family history of vitamin D deficiency, rickets or seizure disorder. A chest radiograph showed flaring of the costochondral junctions consistent with rickets. Her vitamin D 25-OH level was 5 ng/mL (20–100) and D3 level was less than 5 ng/mL. **Conclusion:** Hypocalcemia is a difficult to diagnose in infants because there may present with a wide range of non-specific clinical symptoms, or they may be asymptomatic. It is important for the emergency physician to recognize the association of hypocalcemia with ALTE in infants. Rickets is a re-emerging health problem in infants and children. Physicians should therefore maintain a high index of suspicion for hypocalcemia especially in a breast-fed infant. We suggest including serum calcium level as part of the evaluation of ALTE.

**Keywords:** Rickets, Hypocalcemia, Seizures; ALTE

\*\*\*\*\*

Waseem M, Soontharothai D, Pinkert H, Erickson E, Trotman M. An uncommon cause of apparent life-threatening event. International Journal of Case Reports and Images 2012;3(11):17–20.

\*\*\*\*\*

doi:10.5348/ijcri-2012-11-213-CR-6

Muhammad Waseem<sup>1</sup>, Dee Soontharothai<sup>1</sup>, Heidi Pinkert<sup>1</sup>, Evelyn Erickson<sup>2</sup>, Michael Trotman<sup>1</sup>

**Affiliations:** <sup>1</sup>Department of Emergency Medicine, Lincoln Medical & Mental Health Center, Bronx, NY, United States; <sup>2</sup>Department of Pediatrics, Lincoln Medical & Mental Health Center, Bronx, NY, United States.

**Corresponding Author:** Muhammad Waseem, Department of Emergency Medicine, Lincoln Medical & Mental Health Center, 234 East 149th Street, Bronx, NY, United States-10451; Ph: (718) 579-6010; Email: muhammad.waseem@nychhc.org

Received: 22 November 2011

Accepted: 12 January 2012

Published: 01 November 2012

## INTRODUCTION

An apparent life threatening event (ALTE) is a common reason for presentation to the emergency department (ED). Although the occurrence of seizures due to hypocalcemia in early infancy is well known [1], its association with an acute ALTE is rare [2]. We report

a case of a breast-fed infant who presented with ALTE secondary to hypocalcemia from undiagnosed rickets.

## CASE REPORT

A 9-month-old female baby was brought to the ED because she stopped breathing. Parents reported that she stopped breathing for more than 20 seconds, and was gasping for air. During the event, she became unresponsive and her eyes rolled back. There was a prior history of cough and nasal congestion with subjective fever for two days. Further questioning revealed that over the last few months, she had episodes of ‘gasping’, and ‘strange noisy breathing sounds.’ Her mother reported an ‘odd cough’ for several months. Although at nine months this infant should have been introduced to solid foods, this baby had been exclusively breast-fed and was noted by her mother to be feeding well.

Her past medical history was significant for developmental delay. The patient was born full-term, via normal spontaneous vaginal delivery. The pregnancy, however, had been complicated by oligohydramnios. The parents reported no family history of vitamin D deficiency, rickets or seizure disorder.

On arrival, the patient was alert and awake. The vital signs on arrival were as follows: temperature 102.8°F, heart rate 155/minute, respiratory rate 34/minute, and oxygen saturation 100% on room air. The growth parameters were as follows: weight 9.4 kg (75%), length 73 cm (75%), and head circumference 47 cm (95%).

During the physical examination in the ED, however, the patient had a brief episode of seizure-like activity. The episode lasted a few seconds with desaturation of 88–90% on room air. Mother also reported similar episodes at home. She had no signs of trauma. The neck was supple, and pupils were 3 mm and equally responsive to light with normal extra-ocular movements. Tympanic membranes were normal, and the throat was unremarkable. Clear rhinorrhea was present. She had increased work of breathing with obvious retractions, and an increased respiratory rate with frequent stridor, but no rales or wheezing present. The heart sounds were normal. The abdominal exam was unremarkable. The neurological exam revealed normal tone and reflexes, and a normal sensory examination. No nystagmus was present. The infant was moving all extremities. No rashes or skin lesions were noted. The remainder of her physical examination was unremarkable.

Laboratory investigations revealed a hemoglobin level of 10.7 g/L, a platelet count of 330,000/mm<sup>3</sup>, and a WBC count of 15,700 /mm<sup>3</sup> with 64% neutrophils, 34% lymphocytes, and 0.9% monocytes. The serum electrolytes were as follows: sodium 137 mEq/L, potassium 4.3 mEq/L, chloride 103 mEq/L, bicarbonate 14 mg/dL, blood urea nitrogen 6 mg/dL, creatinine 0.4 mg/dL, glucose 113 mg/dL, and total calcium 4.9 mg/dL. Her magnesium was 1.9 mg/dL. Repeat total calcium

was 6.5 mg/dL, and phosphate 3.2 mg/dL (Nasal secretions for respiratory syncytial virus, and influenza A and B antigens were negative. A chest radiograph showed bilateral pulmonary opacities consistent with pneumonia and flaring of the costochondral junctions consistent with rickets (Figure 1). Findings on radiographs of her wrists also supported the diagnosis of rickets (Figure 2). Her vitamin D 25-OH level was 5 ng/mL (20–100) and D3 level was less than 5 ng/mL.

The patient responded to intravenous calcium replacement with rapid resolution of symptoms. Her calcium level returned to normal and she was discharged home in a stable condition.

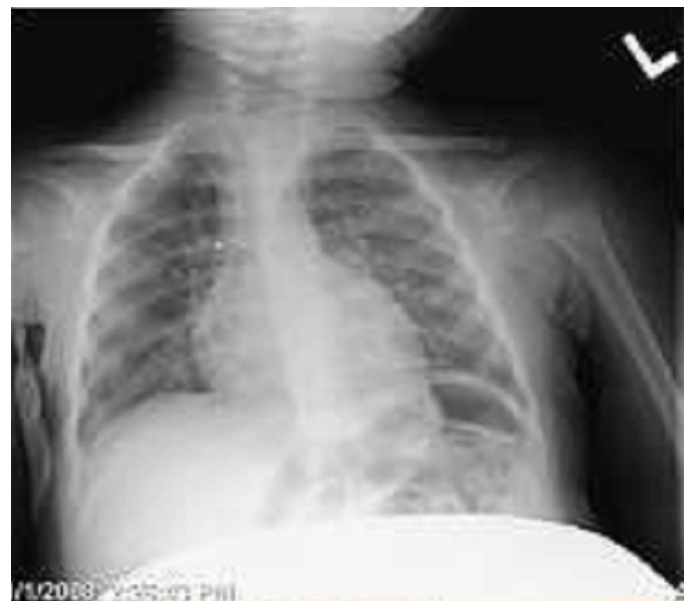

Figure 1: A chest radiograph showing bilateral pulmonary opacities of pneumonia and flaring of the costochondral junctions consistent with rickets.

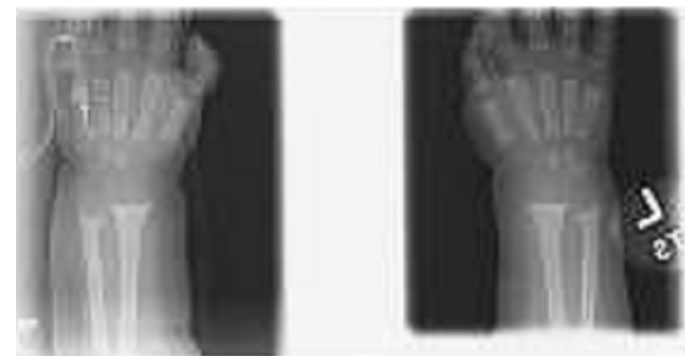


Figure 2: Findings on radiographs of her wrists also supporting the diagnosis of rickets.

## DISCUSSION

An ALTE is defined as ‘an episode that is frightening to the observer and is characterized by some combination of apnea, color change, change in muscle tone, and choking’ [3]. It accounts for 0.6–0.8% of emergency department visits in infants [4].

Hypocalcemia is a difficult to diagnose in infants because there may be a wide range of non-specific clinical symptoms, or patients may be asymptomatic. A high index of suspicion is needed to diagnose hypocalcemia and it is important for the emergency physician to recognize hypocalcemia as a cause of ALTE in infants. These patients may present with non-specific symptoms of weakness, feeding problems, facial spasms, jitteriness or seizures. Other symptoms of hypocalcemia may include lethargy, irritability, and vomiting. Commonly, infants present with hypocalcemic tetany or seizures, whereas older children present with failure to thrive or skeletal abnormalities. Laryngospasm also can occur during seizure-like activity but may itself be a symptom of hypocalcemia [5]. Therefore, determination of serum calcium may be important in an infant with this presentation.

Rickets is the failure of growing bone to mineralize. There are many types of rickets, including nutritional and familial forms. Nutritional rickets due to vitamin D deficiency is the most common form. Vitamin D is critical for skeletal development and is converted to its physiologically active form, cholecalciferol, by exposure to ultraviolet radiation in sunlight. Activated vitamin D then helps bones absorb calcium and phosphorus from food. Vitamin D deficiency impairs mineralization of bone tissue and growth plates, manifesting as rickets. Nutritional rickets may result from inadequate sunlight exposure, or inadequate intake of dietary vitamin D, calcium, or phosphorus [6]. Classically, nutritional rickets manifests after six months of age. Therefore, in addition to checking calcium levels, magnesium, phosphorus, PTH and vitamin D metabolites should be measured. This determination should be made prior to initiation of treatment in order to delineate the cause of rickets.

The most common laboratory findings in nutritional rickets are decreases in serum calcium, serum phosphorus, calcidiol, calcitriol, and urinary calcium. Parathyroid hormone, alkaline phosphatase, and urinary phosphorus levels are however, elevated. The radiographs of rapidly growing skeletal areas, such as the knee or wrist are helpful in making the diagnosis.

Nutritional rickets due to vitamin D deficiency has become rare in the US due to the addition of Vitamin D to milk. However, with an increase in breast-feeding, which offers no Vitamin D fortification, this preventable disease is re-emerging [7]. Although breast milk is indisputably the ideal food for infants, it typically contains about 25 IU or less vitamin D per liter [8], which is not sufficient for the prevention of rickets. It is, therefore, important to consider the screening of patients at risk of developing vitamin D deficiency [9]. In addition, supplementation should also be encouraged in breastfed babies of African-American mothers, who are at higher risk. In our patient, a number of factors pointed to nutritional rickets as the diagnosis. African-American race in an exclusively breast fed infant was the first indication, that nutritional rickets should be considered. This, coupled with an urban life style with inadequate sun exposure made the scenario

likely for a nutritional basis for rickets. This remains a classic presentation for nutritional (vitamin D deficiency) rickets.

## CONCLUSION

Rickets is a re-emerging health problem in infants and children. Physicians should therefore maintain a high index of suspicion when confronted with unexplained seizures in a breast-fed infant. Early diagnosis is essential because morbidity can be minimized with early treatment. The determination of vitamin D status should be considered in the diagnostic evaluation of hypocalcemia in infants.

\*\*\*\*\*

## Author Contributions

Muhammad Waseem – Substantial contributions to conception and design, Acquisition of data, Analysis and interpretation of data, Drafting the article, Revising it critically for important intellectual content, Final approval of the version to be published

Dee Soontharothai – Analysis and interpretation of data, Revising it critically for important intellectual content, Final approval of the version to be published

Heidi Pinkert – Analysis and interpretation of data, Revising it critically for important intellectual content, Final approval of the version to be published

Evelyn Erickson – Analysis and interpretation of data, Revising it critically for important intellectual content, Final approval of the version to be published

Michael Trotman – Analysis and interpretation of data, Revising it critically for important intellectual content, Final approval of the version to be published

## Guarantor

The corresponding author is the guarantor of submission.

## Conflict of Interest

Authors declare no conflict of interest.

## Copyright

© Muhammad Waseem et al. 2012; This article is distributed under the terms of Creative Commons Attribution 3.0 License which permits unrestricted use, distribution and reproduction in any means provided the original authors and original publisher are properly credited. (Please see [www.ijcasereportsandimages.com/copyright-policy.php](http://www.ijcasereportsandimages.com/copyright-policy.php) for more information.)

## REFERENCES

1. Hatun S, Ozkan B, Orbak Z, et al. Vitamin D deficiency in early infancy. *J Nutr* 2005 Feb;135(2):279–82.
2. Mosalli R, Yasser E, Ali AM, Al Harbi S. Congenital vitamin D deficiency: a rare etiology of an acute life

- threatening event in early infancy. Saudi J Kidney Dis Transpl 2010 May;21(3):511–4.
3. National Institutes of Health Consensus Development Conference on Infantile Apnea and Home Monitoring, Sept 29 to Oct 1, 1986. Pediatrics 1987;79(2):292–9.
  4. Gray C, Davies F, Molyneux E. Apparent life-threatening events presenting to a pediatric emergency department. Pediatr Emerg Care 1999;15(3):195–9.
  5. Murphy G, Bartle S. Hypocalcemic laryngospasm and tetany in a child with renal dysplasia. Pediatr Emerg Care 2006;22(7):507–9.
  6. Nield LS, Mahajan P, Joshi A, Kamat D. Rickets: not a disease of the past. Am Fam Physician 2006;74(4):619–26.
  7. Balasubramanian S, Shivbalan S, Kumar PS. Hypocalcemia due to vitamin D deficiency in exclusively breastfed infants. Indian Pediatr 2006 Mar;43(3):247–51.
  8. Nakao H. Nutritional significance of human milk vitamin D in the neonatal period. Kobe J Med Sci 1988;34(3):121–8.
  9. Williams AL, Cox J, Gordon CM. Rickets in an otherwise healthy 11-month-old. Clin Pediatr (Phila) 2008;47(4):409–12.



CASE REPORT

OPEN ACCESS

# Postpartum spontaneous coronary artery dissection: A rare occurrence

Juan Roa Mendez, Jenny Gerner, Kimberly Andrews-Reynolds,  
Lekshmi Dharmarajan

## ABSTRACT

**Introduction:** Postpartum spontaneous coronary artery dissection is a rare but well described presentation of acute coronary syndrome. Acute phase mortality is 5–10%. The majority of dissections occur within two weeks postpartum. Risk factors include advanced age, multiparity, hormonal changes, activities that increase coronary shear stress and hemodynamic factors such as hypertension, cocaine use and weight lifting. Dissections typically involve proximal segment of coronary arteries. Angiographic studies confirm etiology of postpartum MI to be: dissection 35%, stenosis 30%, thrombus 15%, spasm <5%, and 10% with normal coronaries. **Case Report:** A 30-year-old female, 10 days postpartum presented with recurrent oppressive retro-sternal chest pain, radiating to left arm and back, with orthopnea and vomiting. She reported lifting weights the day prior to admission. Apart from elevated blood pressure, physical examination was otherwise unremarkable. **Diagnosis of**

**spontaneous coronary artery dissection was confirmed through laboratory and radiographic testing which showed elevated cardiac enzymes and both an abnormal echocardiogram and angiogram, respectively. Patient was managed medically due to difficult anatomy for percutaneous coronary intervention. Conclusion:** SCAD is a rare life threatening condition that affects predominantly young, healthy women, particularly during pregnancy or postpartum period. The pathogenesis is still unclear. The mechanism, however, is increased shear stress in the coronaries by severe systolic hypertension, cocaine use, activities such as snow shoveling, weight lifting. Contributing factors in our young patient with dissection causing acute MI may have resulted from: lifting weights a day earlier, underlying CAD, parity and typical age/time frame for postpartum dissection.

**Keywords:** Spontaneous coronary artery dissection, Postpartum, SCAD

\*\*\*\*\*

Juan Roa Mendez<sup>1</sup>, Jenny Gerner<sup>2</sup>, Kimberly Andrews-Reynolds<sup>3</sup>, Lekshmi Dharmarajan<sup>4</sup>

**Affiliations:** <sup>1</sup>PGY2, Internal Medicine, Lincoln Medical and Mental Health Center, Bronx, New York, USA; <sup>2</sup>PGY3, Internal Medicine, Lincoln Medical and Mental Health Center, Bronx, New York, USA; <sup>3</sup>Research Assistant, Internal Medicine, Lincoln Medical and Mental Health Center, Bronx, New York, USA; <sup>4</sup>MD, Cardiology Attending, FACP, FACC, Internal Medicine, Lincoln Medical and Mental Health Center, Bronx, New York, USA  
**Corresponding Author:** Juan Roa Mendez, 234 East 149th Street, Bronx, New York USA. 10451; Ph: 1-718-579-5016/5278; Fax: 1-718-579-4836; Email: juancroa3@gmail.com

Received: 04 October 2011  
Accepted: 10 April 2012  
Published: 01 November 2012

Mendez JR, Gerner J, Andrews-Reynolds K, Dharmarajan L. Postpartum spontaneous coronary artery dissection: A rare occurrence. International Journal of Case Reports and Images 2012;3(11):21–24.

\*\*\*\*\*

doi:10.5348/ijcri-2012-11-214-CR-7

## INTRODUCTION

Spontaneous coronary artery dissection (SCAD) is a rare cause of acute coronary syndrome or sudden cardiac death (Figure 1). The etiology is unclear. The first case of SCAD was reported in 1931 [1]. Since then,



more than 300 cases have been documented [2]. The mean age of onset is 30–45 years. More than 70% of SCAD cases are women (Figure 2), 30% occurs during the peripartum period [2, 3]. One-third of all SCAD cases in women occur in this period, one-third occur in late pregnancy and two thirds in the early postpartum period. [4, 5]. The peak incidence is at the first two weeks after delivery. Identified risks factors include advanced age and multiparity [6].

The left anterior descending artery is involved in 78% cases, the left main artery in 24% and multi-vessel dissection occurs in 40% [2]. Spontaneous coronary artery dissection (SCAD) can be divided into the following four subgroups [3]: (i) Underlying atherosclerosis is common in men with a mean age of 55 years; the mechanism of dissection is plaque rupture and intimal disruption that allows dissection to occur. RCA is involved in the majority of cases. (ii) The second group includes arthritis or connective tissue disorders, where integrity of the arterial wall is compromised by inflammation of defective structural proteins like vasculitis, SLE, sarcoidosis, Marfan's syndrome, Ehlers-Danlos syndrome, etc. (iii) The third group includes peripartum or hyperestrogenism states like oral contraceptives and hepatic cirrhosis. The mean age in this group is 33 years and dissection is most common within two weeks postpartum. Eighty-seven percent of peripartum coronary dissection involve the left coronary tree and in 40% cases multiple coronaries are involved. (iv) In the idiopathic SCAD the average age of presentation is 41 years; three fourths of patient are premenopausal women with no cardiac risk factors. The mechanism is increased shear stress in the coronaries by severe systolic hypertension, cocaine use, activities such as snow shoveling, weight lifting, etc [3].

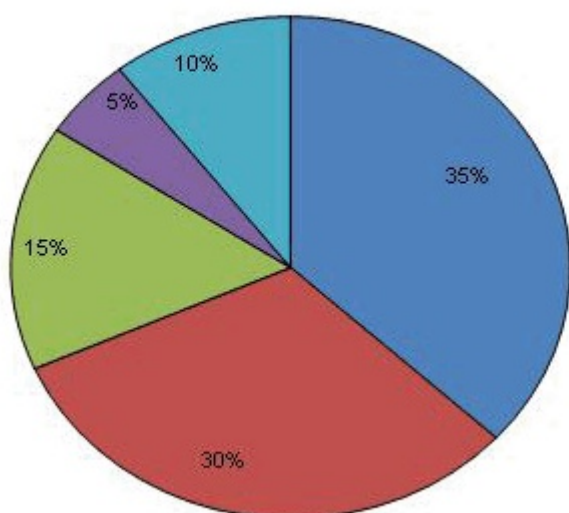


Figure 1: Graph depicting the different causes of postpartum myocardial Infarction confirmed by angiographic studies.

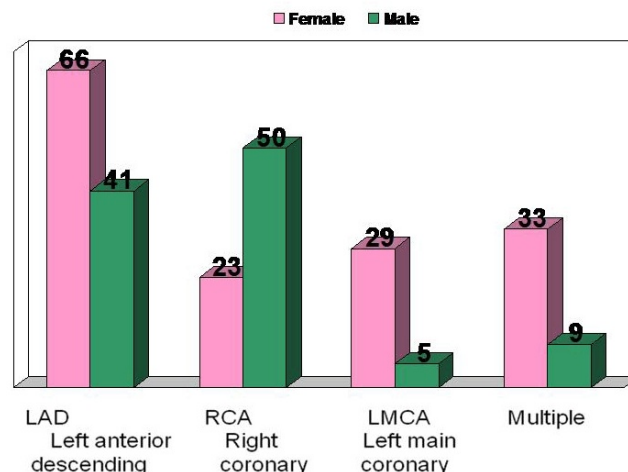


Figure 2: Distribution of anatomic findings of spontaneous coronary artery dissection between men and women.

## CASE REPORT

A 30-year-old African-American female at 10 days postpartum, presented with recurrent oppressive retrosternal chest pain, radiating to the left arm and back, associated with shortness of breath, nausea and vomiting. Patient reported 20 lb weight lifting the day prior to admission after a long period of no exercise. Review of systems was positive for sore throat without additional respiratory symptoms. Her past medical history was unremarkable with no underlying hypertension, diabetes or hypercholesterolemia. Obstetric history was relevant for G3P3 with uncomplicated vaginal delivery and normal prenatal care. She never smoked, used drugs or alcohol. Medications included iron and ibuprofen. Her family history was negative for coronary artery disease (CAD). On ED arrival patient was hypertensive; vitals were: blood pressure 164/104 mmHg, pulse 65/min, temperature 98.2°F and weight 87.7 kg. Cardiovascular examination was normal with no murmurs, jugular vein distention, gallop or carotid bruits. Lungs and chest X-ray were unremarkable. Routine laboratory investigations were within normal limits, including BNP which was 59 pg/mL. Toxicology was also negative. Pulmonary embolism was excluded by chest CT scan. Initial set of cardiac enzymes were elevated, with troponin of 0.181 ng/mL which later peaked to 58.8 ng/mL (CK-MB Index 5.8% with peak CK of 2086 U/L). Electrocardiogram showed low atrial rhythm and minor ST/T changes. Echocardiogram showed mild MR, trace of PI, LV EF of 35%, mid anterior septum inferior and apical hypokinesia. Angiography revealed a mid-left anterior descending (LAD) artery dissection extending into large second diagonal (D2) artery and distal LAD as well as 85% lesion of the first diagonal and 70% lesion of the proximal marginal artery with diffuse disease and preserved flow with severe distal left circumflex artery stenosis (Figure 3). During angiography patient developed ventricular fibrillation requiring direct

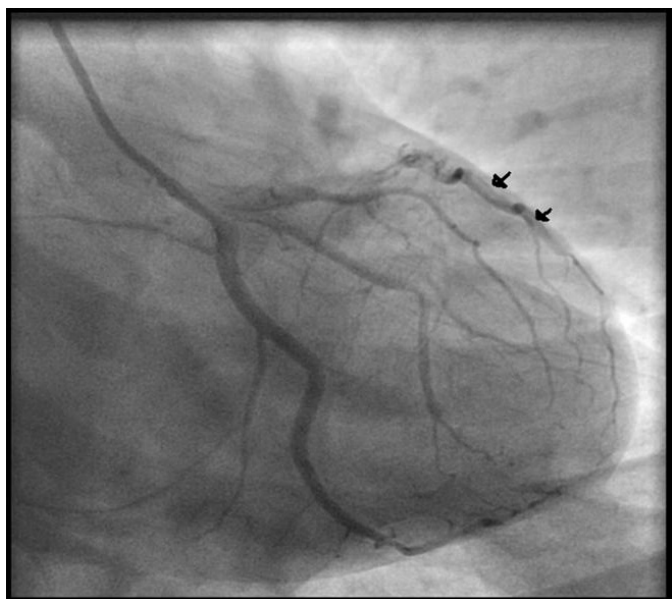


Figure 3: Coronary angiography revealing mid-left anterior descending artery dissection, extending distally with left circumflex artery stenosis.

current cardioversion with lidocaine and amiodarone. Due to severe CAD and distal dissection she was not considered a candidate for percutaneous coronary intervention (PCI) or coronary artery bypass graft (CABG) hence was managed medically with aspirin 81 mg daily, clopidogrel 75 mg daily, metoprolol 50 mg two times per day, lisinopril 10 mg daily and rosuvastatin 20 mg daily.

## DISCUSSION

Spontaneous coronary artery dissection is a rare life threatening condition that affects predominantly young, healthy women, particularly during pregnancy or postpartum period. Mortality rate is about 3% (0–4%) [2] in the acute phase with 95% 2-year survival rate [5]. The overall mortality is of the peripartum group is 38% [2]. Multivariate analysis of 222 patients showed that the strongest predictors of death included female sex (odds ratio (OR) 4.27) and delayed treatment (OR 35.5) [5]. Causes include mechanical factors like coronary artery bypass or post angioplasty, trauma or extension of aortic dissection. Some other factors as given in Figure 4 are also implicated in the pathogenesis. The pathogenesis in the peripartum period is still unclear. A hypothesis proposed to explain the occurrence of spontaneous coronary artery dissection in pregnancy states that hemodynamic factors together within arterial wall smooth muscle cell proliferation, impaired collagen synthesis and alterations in the protein and acid mucopolysaccharide content of the tunica media, oxidative stress secondary to delivery, a lytic action of proteases released from eosinophils and hyperestrogenism altering the normal arterial wall architecture may be responsible for increased

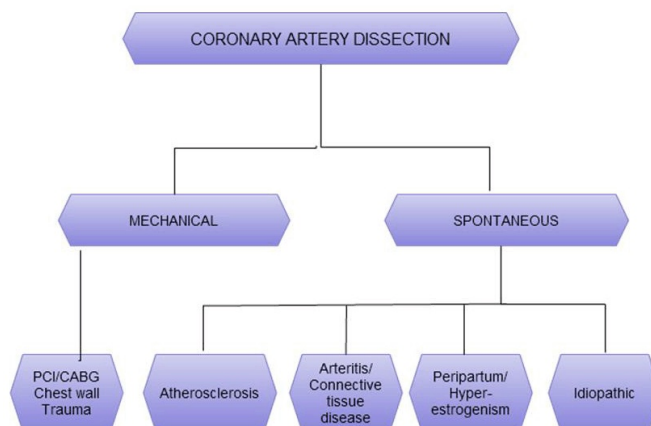


Figure 4: Possible causes of the development of spontaneous coronary artery dissection.

susceptibility. SCAD results from vessel wall hematoma formation creating a false lumen of the tunica media or between the media and the adventitia [6, 7]. The clinical recognition of SCAD is more evident after advent of coronary angiography. Intra-venous ultrasonography can diagnose SCAD, especially those that are angiographically inapparent [2]. Coronary artery dissection is noted in approximately 0.2% of coronary angiographies performed and in up to 3.5% of coronary angiographies with intravascular ultrasonography for acute coronary syndromes. [6]. Dissection typically involves the proximal segment of the coronary artery. Angiography may reveal an intimal flap, but if there is no visible flow into the false lumen or if the dissection develops as a consequence of an intramural hematoma, angiography may reveal only a simulated coronary stenosis due to compression of the true lumen [2]. Treatment options for SCAD include medical therapy with anti-platelet agents and anticoagulants. The decision to manage the patient conservatively with medication or to perform percutaneous coronary intervention (PCI), or coronary artery bypass graft surgery (CABG) must be individualized. Multi-vessel involvement, or failed PCI procedures are treated by CABG. In cases of spontaneous dissections involving a long coronary artery segment, CABG can be very challenging. Reperfusion therapy is mandated if the patient has ongoing symptoms of myocardial ischemia [6]. Our case fits the classic presentation of a patient with postpartum coronary artery dissection including age, parity, postpartum timing and possible contribution to the condition by weight lifting. The additional interesting aspect of this case is that patient not only had postpartum SCAD but also was found to have underlying CAD which is rare in this age group especially with no identifiable risk factors.

## CONCLUSION

High index of suspicion is required when a patient presents with chest pain in the postpartum period to

identify and manage SCAD. Angiography with intravascular ultrasound is the most accurate method for diagnosis and a prompt diagnosis diminishes long- and short-term mortality. Treatment includes medical-management, angioplasty/stenting and CABG; and it should be individualized.

\*\*\*\*\*

### Author Contributions

Juan Roa Mendez – Substantial contributions to conception and design, Acquisition of data, Analysis and interpretation of data, Drafting the article, Revising it critically for important intellectual content, Final approval of the version to be published

Jenny Gerner – Analysis and interpretation of data, Revising it critically for important intellectual content, Final approval of the version to be published

Kimberly Andrews-Reynolds – Analysis and interpretation of data, Revising it critically for important intellectual content, Final approval of the version to be published

Lekshmi Dharmarajan – Analysis and interpretation of data, Revising it critically for important intellectual content, Final approval of the version to be published

### Guarantor

The corresponding author is the guarantor of submission.

### Conflict of Interest

Authors declare no conflict of interest.

### Copyright

© Juan Roa Mendez et al. 2012; This article is distributed under the terms of Creative Commons Attribution 3.0 License which permits unrestricted use, distribution and reproduction in any means provided the original authors and original publisher are properly credited. (Please see [www.ijcasereportsandimages.com/copyright-policy.php](http://www.ijcasereportsandimages.com/copyright-policy.php) for more information.)

## REFERENCES

1. Pretty HC. Dissecting aneurysm of coronary artery in a woman aged 42. *BMJ* 1931;1:667.
2. Vrints CJ. Spontaneous coronary artery dissection. *Heart* 2010;96(10):801–8.
3. Vanzetto G, Berger-Coiz E, Barone-Rochette G, et al. Prevalence, therapeutic management and medium-term prognosis of spontaneous coronary artery dissection: results from a database of 11,605 patients. *Eur J Cardiothoracic Surg* 2009;35(2):250–4.
4. Kamineni R, Sadhu A, Alpert JS. Spontaneous Coronary Artery Dissection: Report of 2 cases and 50 year Review of the Literature. *Cardiology In Review* 2002;10(5):279–84.
5. Thompson EA, Ferraris S, Gress T, Ferraris V. Gender differences and predictors of mortality in spontaneous coronary artery dissection: a review of reported cases. *J Invasive Cardiol* 2005;17(1):59–61.

6. Sabatine MS, Jaffer FA, Staats PN, Stone JR. Case records of the Massachusetts General Hospital. Case 28-2010. A 32-year-old woman, 3 weeks post partum, with substernal chest pain. *N Engl J Med* 2010;363(12):1164–73.
7. Borczuk AC. Review and hypothesis: the eosinophil and peripartum heart disease (myocarditis and coronary artery dissection) coincidence or pathogenetic significance? *Cardiovasc Res* 1997;33(3):527–32.

CASE REPORT

OPEN ACCESS

# Congenital nephrogenic diabetes insipidus presented after acute pyelonephritis

Christian Castillo, Poonam Bherwani, Evelyn Erickson,  
Gerard Prosper

## ABSTRACT

**Introduction:** Diabetes insipidus (DI) is characterized by the inability to concentrate urine. While central DI is caused by failure to release enough functional vasopressin, nephrogenic DI (NDI) is due to the insensitivity of the distal nephron to the effect of antidiuretic hormone (ADH). **Case Report:** A 5-day-old newborn male was admitted for isolated fever and a questionable early right upper lobe infiltrate. He gradually developed hypernatremia and increased osmolality. As part of his work up for fever, he had a urine culture of 30K colonies of *Enterococcus faecalis*. His vasopressin test was negative. **Conclusion:** The polyuria and polydipsia associated with genetic NDI usually presents within the first several weeks of life but may only become apparent after weaning or with longer periods of nighttime fasting. The acute pyelonephritis of this newborn may have been the initial trigger for the congenital NDI. Accurate diagnosis of this patient helped to also diagnose his maternal uncle and provide clues to the current condition of his maternal grandmother. Early diagnosis and management can prevent the development

of neurological and developmental complications associated with NDI.

**Keywords:** Congenital Diabetes Insipidus, Nephrogenic Diabetes Insipidus, Acute Pyelonephritis

\*\*\*\*\*

Castillo C, Bherwani P, Erickson E, Prosper G. Congenital nephrogenic diabetes insipidus presented after acute pyelonephritis. International Journal of Case Reports and Images 2012;3(11):25–27.

\*\*\*\*\*

doi:10.5348/ijcri-2012-11-215-CR-8

## INTRODUCTION

Diabetes insipidus is characterized by the inability to concentrate urine. While central DI is caused by the failure to release enough functional vasopressin (antidiuretic hormone), NDI is due to the insensitivity of the distal nephron to the antidiuretic effect of ADH. If presented at birth, it is considered a genetic mutation called congenital nephrogenic DI [1]. We present here a case of a newborn admitted for acute pyelonephritis with a normal chemistry, who subsequently developed hypernatremia and hyperosmolality. Acute pyelonephritis, being an interstitial nephritis may present with a renal tubular defect affecting the different segments. One of the manifestations is the loss of concentrating ability which is transient and resolves in a few weeks.

## CASE REPORT

A 5-day-old newborn male, product of a full term and uncomplicated pregnancy was admitted to the

Christian Castillo<sup>1</sup>, Poonam Bherwani<sup>2</sup>, Evelyn Erickson<sup>3</sup>, Gerard Prosper<sup>4</sup>

**Affiliations:** <sup>1</sup>Neonatology Fellow, Cook County Hospital, Chicago, Illinois, USA; <sup>2</sup>Department of Pediatrics, Lincoln Medical and Mental Health Center, Bronx, New York, USA;

<sup>3</sup>Research Assistant, Department of Pediatrics, Lincoln Medical and Mental Health Center, Bronx, New York, USA;

<sup>4</sup>Attending of Pediatric Nephrology, Lincoln Medical and Mental Health Center, Bronx, New York, USA

**Corresponding Author:** Evelyn Erickson, 234 East 149th Street, 4C-20, Bronx, NY, USA-10451; Ph: 718-579-5030; Fax: 718-579-4700; Email: evelyn.erickson@nychhc.org

Received: 04 October 2011

Accepted: 29 December 2011

Published: 01 November 2012



hospital for fever without focus. All maternal ancillary tests including Group B *Streptococcus* were negative. On admission, the patient was well hydrated. His vital signs were temperature of 102.8 °F, pulse of 162, blood pressure of 86/47 mmHg and respiratory rate of 51, and O<sub>2</sub> saturation of 95%. The physical examination was unremarkable. A complete sepsis work up was performed. CBC and CSF chemistry, and hematology as well as Blood Urea Nitrogen, and serum creatinine (BUN/Creat) were normal. However, the serum sodium was in the upper limit of normal and the urine specific gravity was less than 1.005.

The patient was on formula feedings supplemented with IV Dextrose 5%/NaCl 0.2 (2/3 maintenance) and started on IV cefotaxime and ampicillin. On the 3rd hospitalization day, it was noted that the patient urine output was greater than 6 cc/kg/hr and the patient serum sodium went up to 159 mEq/L but BUN/Creat were normal. The serum osmolality increased to 417 mOsm and the corresponding urine osmolality was 88 mOsm/kg. The urine culture from a catheterized specimen grew 30K colonies of *Enterococcus faecalis*, which was sensitive to ampicillin. His fluid requirement was changed to IV Dextrose 5%/NaCl 0.2 (free water loss + daily maintenance) and oral feeding. To confirm the concentrating defect and to distinguish the renal form from the central form, a vasopressin test was performed. The test consists of the administration IV of 1 Unit of AVP by m<sup>2</sup>. The urine specific gravity, urine osmolality and output, serum osmolality, and serum sodium were determined pre and post administration of AVP and follow up monitoring at 1, 2 and 3 hours (Table 1). The results suggested the diagnosis of NDI which was later confirmed by an elevated level of AVP (15.2 pg/mL).

## DISCUSSION

Three different inheritance patterns have been recognized. In most cases, approximately 90% are

transmitted as an X-link recessive trait in the families. Female carriers were clinically unaffected, transmitting the disease to their sons who display the complete clinical picture. In 1998, the major NDI locus was mapped in the distal region of the long arm of the X chromosome (Xq28) and in 1992, the gene in VR2 was shown to underline X-linked NDI [2, 3].

In a minority of families, approximately 10% of the transmission and phenotypic characteristics of NDI are not compatible with an X-linked trait. In these families, females display a complete clinical picture of NDI and are clinically indistinguishable from affected males. In addition, linkage analysis in these families has excluded linkage between NDI and polymorphic DNA marker from the Xq28 region, a family pedigree has suggested the existence of both autosomal recessive and dominant forms of NDI. In the recent years, it has been demonstrated that both autosomal forms are caused by a mutation of an AVP sensitive AQP2 water channel [4].

In our patient, the genetic analysis reveals an AVPR2 sequence variant on the chromosome locus associated NDI. His maternal uncle was found to have the same mutation (Figure 1). For the maternal grandmother who was not tested but has clinical evidence of NDI, the most likely explanation for the existence of the phenotype carrier of the AVPR2 mutation varying from no symptom to complete manifestation of the disorder could be attributed to a skewed X inactivation [5].

The polyuria and polydipsia associated with genetic NDI usually presents within the first several weeks of life but may only become apparent after weaning or with longer periods of nighttime fasting. Many infants initially present with fever, vomiting, dehydration and failure to thrive. Acquired NDI may result from hypercalcemia or hypokalemia, and is associated with the following drugs: lithium, demeclocycline, foscarnet, clozapine, amphotericin, methicillin, and rifampin. In our case, the acute pyelonephritis may have been the initial trigger for the congenital NDI [1].

Initially, it was assumed that this case of NDI could have been caused by an acute pyelonephritis which is

Table 1: Results after a vasopressin test using a dose of 1 unit/m<sup>2</sup> (Body Surface Area 0.21 m<sup>2</sup>)

Time	Specific Gravity	Urine Osmolality (mOsm/kg)	Urine Output (Cc/Kg/hr)	Serum Osmolality (mOsm)	Serum Na (mEq/L)	Vital Signs
Pre Test	1.005	88	(5.6)	417	159	Normal
1 hour	1.005	106	(6.6)			Normal
2 hours	1.005	95	(7.4)	321	153	Normal
3 hours	1.005	89	(6.1)			Normal
Administration of HCTZ 4 mg						
8 hours		95	5.07	321	148	Normal
12 hours	1.010	89	9.19	305	138	Normal
24 hours	1.005	112	3.2	296	139	Normal

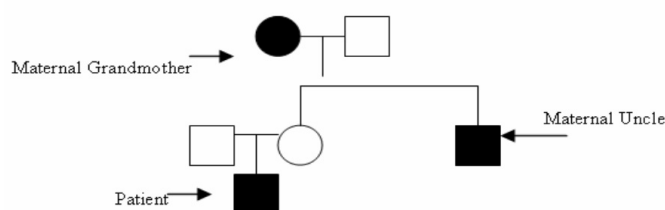


Figure 1: Family pedigree demonstrating a hereditary AVP/AQP2 receptor mutation.

associated with tubular dysfunction as a disturbance of water and electrolytes imbalance. On further investigation, the family medical history revealed that the patient's maternal uncle who is 9 years old, has a history of polyuria and polydipsia. In addition, the maternal grandmother has a similar history since childhood, and reports that she drinks about 4 to 5 gallons of water a day. A genetics test coding regions of the AVP gene and the AVP receptor 2 (AVPR2) genes were sequenced in the outpatient setting revealing an AVPR2 sequence variant on the X chromosome associated with NDI. The maternal uncle was also tested and found to have similar results.

## CONCLUSION

Disturbance of water and electrolyte balances in acutely sick newborn and infant deserve an urgent systematic and detailed investigation for accurate diagnosis and proper management in view of preventing the neurological and developmental complications that could occur. Our patient had early manifestation of congenital NDI, contrary to his uncle who developed symptoms at a later age and the grandmother who appears to have a mild form. Acute pyelonephritis may be a compounding factor for the initiation of his NDI. For it is known that acute pyelonephritis may cause an acquired and transient NDI by downregulating AQP2 expression. Accurate diagnosis of this patient helped to diagnose his maternal uncle with hereditary NDI due to an AVPR2 x-linked mutation, and provide clues to the maternal grandmother's clinical manifestation.

\*\*\*\*\*

## Author Contributions

Christian Castillo – Conception and design, Acquisition of data, Analysis and interpretation of data, Drafting the article, Critical revision of the article, Final approval of the version to be published

Poonam Bherwani – Conception and design, Acquisition of data, Analysis and interpretation of data, Drafting the article, Critical revision of the article, Final approval of the version to be published

Evelyn Erickson – Acquisition of data, Drafting the article, Critical revision of the article, Final approval of the version to be published

Gerard Prosper – Conception and design, Acquisition of data, Analysis and interpretation of data, Drafting the article, Critical revision of the article, Final approval of the version to be published

## Guarantor

The corresponding author is the guarantor of submission.

## Conflict of Interest

Authors declare no conflict of interest.

## Copyright

© Christian Castillo et al. 2012; This article is distributed under the terms of Creative Commons Attribution 3.0 License which permits unrestricted use, distribution and reproduction in any means provided the original authors and original publisher are properly credited. (Please see [www.ijcasereportsandimages.com/copyright-policy.php](http://www.ijcasereportsandimages.com/copyright-policy.php) for more information.)

## REFERENCES

1. Bichet DG, Oksche A, Rosenthal W. Congenital Nephrogenic Diabetic Insipidus. *Journal of American Society of Nephrology* 1997;8(12):1951–8.
2. van den Ouweland AM, Dreesen JC, Verdijk M, et al. Mutations in the vasopressin type 2 receptor gene (AVPR2) associated with nephrogenic diabetes insipidus. *Nat Genet* 1992 Oct;2(2):99–102.
3. Pan Y, Metzenberg A, Das S, Jing B, Gitschier J. Mutations in the V2 vasopressin receptor gene are associated with X-linked Nephrogenic Diabetes Insipidus. *Nat Genetics* 1992 Oct;2(2):103–6.
4. Sato K, Fukuno H, Taniguchi T, Sawada S, Fukui T, Kinoshita M. A novel mutation in the vasopressin V2 receptor gene in a woman with congenital nephrogenic diabetes insipidus. *Intern Med* 1999 Oct;38(10):808–12.
5. Nomura Y, Onigata K, Nagashima T, et al. Detection of Skewed X-Inactivation on two female carriers of vasopressin type 2 receptor gene mutation. *J Clin Endocrinol Metab* 1997 Oct;82(10):3434–7.

CASE REPORT

OPEN ACCESS

# Numb chin in thyroid carcinoma: A rare clinical presentation

Jitendra V Kalburge, Yogesh K Kini, Vaishali J Kalburge

## ABSTRACT

**Introduction:** Metastasis to the oral region from a malignant tumor elsewhere in the body is an uncommon but clinically important finding, because it may be the first indication that the patient has a distant primary tumor. **Case report:** A 65-year-old female presented with numb chin secondary to metastasis from thyroid follicular carcinoma is discussed. The lesion was located in the mandible on the right side. The diagnosis was solely based on histopathological examination of the tissue taken from the lesion in the mandible. This was the first evidence of the metastatic tumor in the jaws from thyroid follicular carcinoma in this patient. **Conclusion:** Although metastatic lesions within the mandible can be asymptomatic, most patients experience some degree of discomfort or pain, which is often followed by loosening of teeth or unilateral paresthesia or anesthesia of the lower lip or chin. The development of these symptoms should alert the clinician to the potential presence of metastatic disease.

**Keywords:** Metastasis, Follicular carcinoma, Thyroid gland, Mandible

\*\*\*\*\*

Kalburge JV, Kini YK, Kalburge VJ. Numb chin in thyroid carcinoma: A rare clinical presentation. International Journal of Case Reports and Images 2012;3(11):28–31.

\*\*\*\*\*

doi:10.5348/ijcri-2012-11-216-CR-9

## INTRODUCTION

Cancer is a complex disease in which many basic processes, such as cell division, apoptosis, and cell migration are dysregulated. It is the process of metastasis that results in morbidity and eventual mortality [1]. Metastatic carcinoma is the most common form of cancer involving the bone. Metastasis to a jaw bone may arise from primary carcinomas of any anatomic site. Carcinomas of breast, lung, thyroid, prostate and kidney give rise to the majority of gnathic metastases [2]. Metastatic carcinoma to the jaws constitutes approximately 1% of all oral malignancies. These tumors are of great clinical significance since at times their appearance may be the only symptom of an undiscovered malignancy and may be the first evidence of dissemination of the known tumor from its primary site [3].

Metastatic involvement of the jaws exhibit a wide variety of symptoms such as pain, swelling, loosening of teeth, etc. Metastasis to the mandible with involvement of the inferior alveolar nerve occasionally produces a distinctive pattern of anesthesia termed numb chin syndrome, in which there is an unexplained loss of sensation in the lower lip and chin. These symptoms may also be associated with inflammatory or primary neoplastic diseases of the jaws [2].

Jitendra V Kalburge<sup>1</sup>, Yogesh K Kini<sup>2</sup>, Vaishali J Kalburge<sup>3</sup>  
**Affiliations:** <sup>1</sup>Professor, Dept. of Oral & Maxillofacial Pathology, Rural Dental College, Pravara Institute of Medical Sciences, Loni; <sup>2</sup>Professor, Dept. of Oral & Maxillofacial Surgery, Rural Dental College, Pravara Institute of Medical Sciences, Loni; <sup>3</sup>Senior lecturer, Dept. of Conservative Dentistry & Endodontics, Rural Dental College, Pravara Institute of Medical Sciences, Loni.  
**Corresponding Author:** Dr. Jitendra Kalburge, Professor and Head, Dept. of Oral & Maxillofacial Pathology, Govt. Dental College & Hospital, Jamnagar-361008, Gujarat; Ph: 9604173884; Email: jkalburge@gmail.com, oralpathology@pmtipms.org

Received: 04 October 2011  
Accepted: 05 May 2012  
Published: 01 November 2012



The objective of this case report is to discuss metastatic thyroid follicular carcinoma in the mandible with an initial clinical presentation of numb chin syndrome.

## CASE REPORT

A 65-year-old female reported to the outpatient department, with a complaint of swelling in the right side of the lower jaw with loss of sensation in the lower lip and chin for three months. Patient also complained of difficulty in opening mouth and swallowing.

The patient was old and appeared to be emaciated. No relevant medical history or a family history indicating any underlying genetic mechanism was recorded. She had habit of cleaning teeth by using Maseri and chewing tobacco quid mixed with lime, three to four times a day since her young age.

Extraoral examination revealed a diffuse swelling which was soft to firm in consistency, slightly tender with a size of 3x2 cm involving body and angle of mandible over right side. The skin over the swelling appeared to be normal but fixed to the underlying tissues. Area of fixation could be appreciated clinically on inspection as well as on palpation (Figure 1). The patient was clinically tested for loss of sensation in lower lip by forceful pinching and needle piercing. It was found that she had developed paresthesia of lower lip.

Intraoral examination confirmed with extra oral findings on the extension of the lesion. There was a swelling in the region of angle and depression in the region of body of the mandible on edentulous alveolar ridge. The alveolar ridge appeared to be soft and fluctuating on palpation. Patient gave history of exfoliation of teeth in the same region because of mobility. Maxillary arch was edentulous (Figure 2).

After thorough clinical examination, an orthopantomogram (OPG) was recorded. OPG revealed a large radiolucent, destructive lesion in the body and angle of mandible region. At places there were some radiopaque foci (Figure 3).

Based on these clinical and radiographic findings, a provisional diagnosis of primary intraosseous carcinoma was made. In the differential diagnosis following pathologies like central giant cell granuloma, central salivary gland neoplasm, and osteomyelitis were considered.

After obtaining written consent from the patient routine blood investigations were carried out and an incisional biopsy was done under all aseptic conditions and local anaesthesia.

The tissue was processed by routine histologic method and the sections were stained with H&E stain. Histopathologically, the tissue showed follicles lined by cuboidal cells with eosinophilic material (colloid) in the lumen. The cells with hyperchromatic nuclei were also found to be in sheets and towards periphery of the lesional tissue, invading the surrounding tissue (Figure 4). These histopathologic features were suggestive of

metastatic deposits and were in favor of follicular carcinoma of thyroid gland. Thus a diagnosis of metastasis of thyroid follicular carcinoma to the mandible was made.

The patient was immediately called and examined for neck mass. A mild swelling could be appreciated in the middle of the neck. The swelling was inconspicuous, painless, soft in consistency and diffuse. Patient was then referred to oncology department for thorough examination of the primary tumor site, i.e. thyroid gland. The reports confirmed the tumor as follicular carcinoma of thyroid with secondary in the mandible. Thus a conclusion was made that the jaw metastasis was first evidence of the malignant tumor of thyroid gland in this patient and was the cause of numb chin syndrome.

Patient was referred to oncology unit for further management. She was treated by near-total

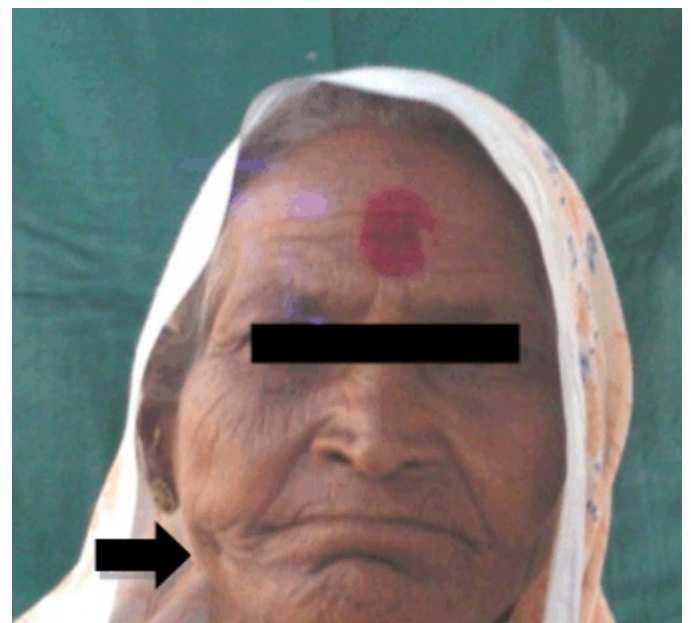

Figure 1: Extraoral photograph shows fixation of skin (arrow) to the underlying structures in lower half of the face on right side.

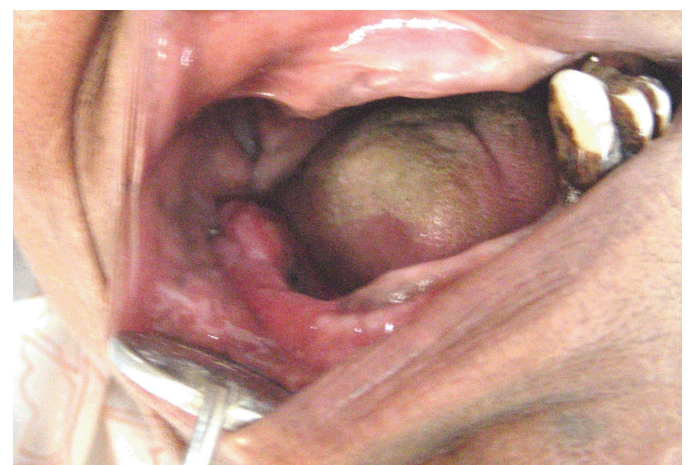


Figure 2: Intraoral photograph shows edentulous right alveolar ridge with swelling & depression in angle/body of the mandible.



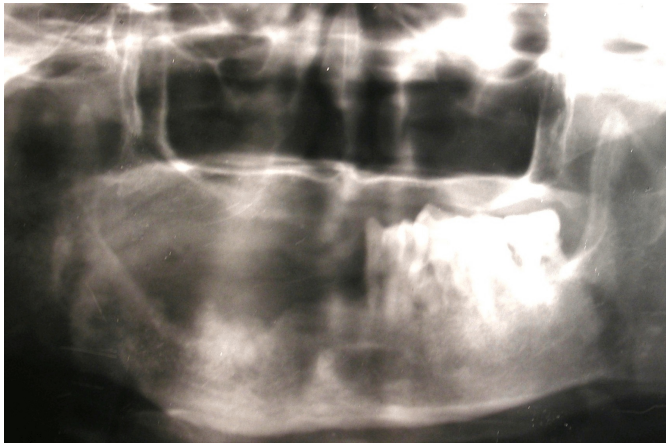


Figure 3: OPG showing a large radiolucent lesion with few radio-opaque foci in the body of the mandible on right side.

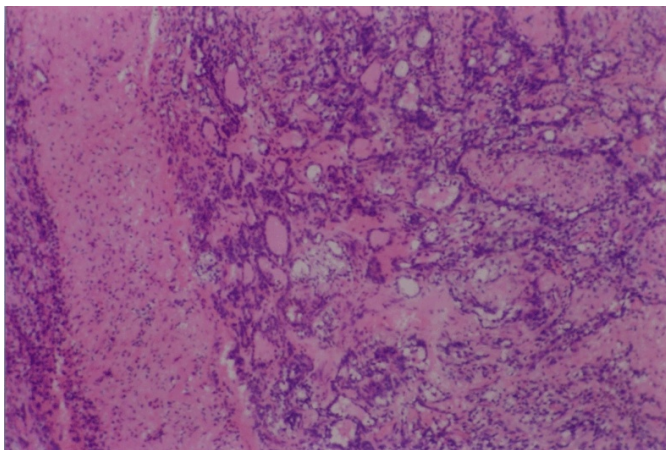


Figure 4: Photomicrograph shows follicles lined by hyperchromatic cuboid cells and containing colloid and sheets invading the surrounding tissues (20X, H&E stain)

thyroidectomy, resection of lesion in the mandible and radiotherapy. Follow-up revealed that the patient did not turn-up after second cycle of radiotherapy and died of the disease.

## DISCUSSION

Metastatic jaw tumors originate from distant body sites and exclude lesions due to spread from adjacent sites or those due to local recurrence. Metastatic lesions are very significant as their appearance may be the only symptom of an underlying malignancy and/or the first evidence of dissemination from the primary site [4].

The exact incidence of secondary malignancies in the jaws is difficult to ascertain, as skeletal radiographic surveys are not routinely done. Even when such scans are performed, the jaws are usually excluded. In the opinion of several authors, only 1% of oral malignant neoplasms are metastatic in origin [4, 5]. Metastatic

tumors are most commonly encountered in the fifth to seventh decade of life. Controversy exists regarding sex predilection [6].

Literature indicates that metastases are more frequent in the mandible than in the maxilla due to paucity of active red marrow in the latter. Apart from the jaw bones, other oral sites of metastatic tumor are gingiva, buccal mucosa, soft palate and tongue [7]. In the oral soft tissues, the gingiva is the most common site for the metastatic colonization. Inflammation may play a role in the attraction of metastatic cells towards the gingiva [8].

Very few cases of metastatic thyroid follicular carcinoma to the jaws have been reported. In a recent analysis of 673 metastatic tumors to the oral cavity, Hirshberg et al. found 21 cases of thyroid malignancy metastasizing to the oral cavity, majority of them (19 cases) showed involvement of the jaws with female predominance (15 cases) [1]. A female predominance has been noticed among patients developing thyroid carcinoma in the adults, probably related to the expression of estrogen receptors on neoplastic thyroid epithelium. Follicular carcinomas are the second most common form of thyroid cancer (15%) and the neoplasm tend to metastasize through the blood stream to the lungs, bone and liver [9]. It shows higher prevalence of bone metastasis [10].

Soft tissue metastasis involving gingiva from a thyroid medullary carcinoma was reported by Piattelli et al. [10] while Hefer et al. [11] reported a case of maxillary metastasis. Kaveri et al. [6] reported a case of metastatic thyroid follicular carcinoma to the mandible.

Paresthesia of the lower lip and the chin should be considered an ominous sign for metastatic lesions of the mandible, as this signifies deep invasion of the tumor in to the bone and involvement of the inferior dental or mental nerves. The patient presented with initial complaint of swelling in the mandible and paresthesia of the lower lip on affected side. When seen in a patient with a known malignancy numb chin syndrome, in the absence of other causes, should be considered to be due to mandibular metastases until proven otherwise [12]. In 1987, a similar case of mental nerve anesthesia secondary to metastatic adenocarcinoma of breast was reported by Kalamchi [13].

This case is showed numb chin syndrome with involvement of mandible. A thorough evaluation of clinical condition and histopathological study of the incisional biopsy revealed the presence of metastatic pathology. Oral metastasis may present in various forms; as pain, swelling, tooth loosening, paresthesia, epistaxis and cervical lymphadenopathy or rarely as a pathological fracture or solitary radiolucency of the jaw bone. From the features of this case we suggest that metastatic tumor should always be included in the differential diagnosis of numb chin syndrome, along with odontogenic infections and other intraoral tumors.

Unlike the oral soft tissues, where a potentially metastatic lesion can be easily recognized, the presence of an early focus of tumor metastasis in the jaw bone may be overlooked. For many tumors the nearest

anatomic site encountered will be the most common site for metastatic colony formation [12]. Hanahan and Weinberg, have described the processes involved in the detachment of tumor cells from the primary cancer site, its transport through the lymphatics or blood stream and establishment of a metastatic tumor site [14].

## CONCLUSION

Metastases to the oral cavity are quite uncommon. They may present with features similar to odontogenic infections and benign tumors. Most of the patients experience some degree of discomfort or pain, which is often followed by loosening of teeth or unilateral paresthesia or anesthesia of the lower lip or chin. The development of these symptoms should alert the clinician to the potential presence of metastatic disease. Careful clinical and histopathologic examination would facilitate selective investigations and multidisciplinary treatment.

\*\*\*\*\*

## Author Contributions

Jitendra V Kalburge – Substantial contributions to conception and design, Acquisition of data, Analysis and interpretation of data, Drafting the article, Revising it critically for important intellectual content, Final approval of the version to be published

Yogesh K Kini – Analysis and interpretation of data, Revising it critically for important intellectual content, Final approval of the version to be published

Vaishali J Kalburge – Analysis and interpretation of data, Revising it critically for important intellectual content, Final approval of the version to be published

## Guarantor

The corresponding author is the guarantor of submission.

## Conflict of Interest

Authors declare no conflict of interest.

## Copyright

© Jitendra V Kalburge et al. 2012; This article is distributed under the terms of Creative Commons Attribution 3.0 License which permits unrestricted use, distribution and reproduction in any means provided the original authors and original publisher are properly credited. (Please see [www.ijcasereportsandimages.com/copyright-policy.php](http://www.ijcasereportsandimages.com/copyright-policy.php) for more information.)

## REFERENCES

1. Hirshberg A, Shnaiderman-Shapiro A, Kaplan I, Berger R. Metastatic tumours to the oral cavity – pathogenesis and analysis of 673 cases. *Oral Oncology* 2008;44(8):743–52.
2. Neville BW, Damm DD, Alen CM, Bouquot JE. *Oral and Maxillofacial Pathology*, 2nd edition, Saunders-Elsevier Publications, 582–3.
3. Anil S, Lal PM, Gill DS, Beena VT. Metastasis of thyroid carcinoma to the mandible. Case report. *Australian Dental Journal* 1999;44(1):56–7.
4. Adebayo ET, Ajike SO. Report of six cases of metastatic jaw tumours in Nigerians. *Nigerian Journal of Surgical Research* 2004 Jan-June;6(1-2):30–3.
5. Batsakis JG. *Tumours of Head and Neck*. William and Wilkins, Baltimore 1979.
6. Kaveri H, Puniya VA, Tayaar Amsavardani S. Metastatic thyroid carcinoma to the mandible. *Journal of Oral and Maxillofacial Pathology* 2007;11:32–4.
7. Van der Wall RIF, Buter J, Van der Wall I. Oral metastases: Report of 24 cases. *Br J Oral Maxillofac Surg* 2003;41(1):3–6.
8. Hirshberg A, Leibovich P, Buchner A. Metastatic tumours to the jawbones: analysis of 390 cases. *J Oral Pathol Med* 1994;23(8):337–41.
9. Kumar V, Cotran R, Robbins S. *Robbins Basic Pathology*, 7th edition, Saunders-Elsevier Publications, 733–7.
10. Piattelli A, Fioroni M, Rubini C. Gingival metastasis from a medullary thyroid carcinoma: Case report. *Journal of Periodontology* 2000 Jan;71(1):112–6.
11. Hefer T, Manor R, Joachims HZ, et al. Metastatic follicular thyroid carcinoma to the maxilla. *The Journal of Laryngology & Otology* 1998;112(1):69–72.
12. Bodner L, Sion-Vardy N, Geffen DB, Nash M. Metastatic tumors to the jaws: A report of eight new cases. *Med Oral Patol Oral Cir Bucal* 2006;11(2):E132–5.
13. Kalamchi S. Mental nerve anaesthesia secondary to breast cancer. *Dent Update* 1987;14(3):125–8.
14. Hanahan D, Weinberg RA. The hallmark of cancer. *Cell* 2000;100(1):57–70.

CASE REPORT

OPEN ACCESS

# Ileocecal burkitt's lymphoma presenting as acute appendicitis: A case report

Jean-Pierre Gonçalves, Arnaldo Cerqueira, Henedina Antunes, Íris Maia, Susana Carvalho

## ABSTRACT

**Introduction:** Burkitt's lymphoma is a highly aggressive non-Hodgkin lymphoma and occurs predominantly in the first decades of life in males. Often the clinical presentation is an abdominal mass associated with abdominal pain, nausea, intestinal obstruction or intussusceptions. The association between Burkitt's lymphoma and histological proven acute appendicitis is rare, and usually is secondary to intussusceptions. **Case Report:** We present a case of a 14-year-old boy with an ileocecal Burkitt's lymphoma presented as acute appendicitis. **Conclusion:** This report emphasizes the importance of the histopathological exam of the appendix in all patients with acute appendicitis suspicious, even those with typical clinical presentation.

**Keywords:** Burkitt's lymphoma, Acute appendicitis

Jean-Pierre Gonçalves<sup>1,2</sup>, Arnaldo Cerqueira<sup>1</sup>, Henedina Antunes<sup>3</sup>, Íris Maia<sup>4</sup>, Susana Carvalho<sup>1</sup>

**Affiliations:** <sup>1</sup>Paediatrics Department, Braga Hospital, Portugal; <sup>2</sup>Community Health, School of Health Sciences, University of Minho, Braga, Portugal; <sup>3</sup>Paediatric Gastroenterology, Hepatology and Nutrition Unit, Braga Hospital, Portugal; Life and Health Sciences Research Institute, School of Health Sciences, University of Minho; ICVS/3B's - PT Government Associate Laboratory, Braga/Guimarães, Portugal; <sup>4</sup>Paediatric Oncology, Portuguese Institute for Oncology, Porto (IPO), Portugal.

**Corresponding Author:** Jean-Pierre Gonçalves, Hospital de Braga, Sete Fontes, S. Victor, 4710-243 Braga; Ph: 253027000; Email: pierre\_3.14r@hotmail.com

Received: 13 October 2011

Accepted: 12 January 2012

Published: 01 November 2012

Gonçalves JP, Cerqueira A, Antunes H, Maia Í, Carvalho S. Ileocecal burkitt's lymphoma presenting as acute appendicitis: A case report. International Journal of Case Reports and Images 2012;3(11):32–34.

\*\*\*\*\*

doi:10.5348/ijcri-2012-11-217-CR-10

## INTRODUCTION

Lymphomas are a group of malignant tumors involving cells of the lymphoreticular or immune system [1]. Burkitt's lymphoma (BL) accounts for 30% of non-endemic pediatric lymphoma and is a highly aggressive non-Hodgkin lymphoma. It is also the faster growing human tumor with a doubling time of the less than 24 hours [2] and has two major forms, the endemic (African) and non-endemic (sporadic) form.

Burkitt's lymphoma occurs predominantly in the first decades of life, in males and might present primarily as an abdominal mass associated with abdominal pain, nausea, intestinal obstruction or intussusceptions [3]. The association between BL and histological proven acute appendicitis (AA) is rare [4] and usually is secondary to intussusceptions [3]. We present a rare case of ileocecal BL presenting as AA.

## CASE REPORT

A 14-year-old Caucasian boy presented to our Emergency Unit with a six-day history of periumbilical pain associated with fever. He had anorexia but nausea or vomiting were not reported. There was no diarrhea, melena or hematemesis. Past medical, surgical and drug histories were unremarkable.

Physical examination revealed tenderness over the right iliac fossa, but there were no palpable masses or abdominal distension. Blood analysis showed an increased white blood cell counts (11500 cells/ $\mu$ L),



neutrophilia (9000 cells/ $\mu$ L) and raised C-reactive protein (172 mg/L). Abdominal ultrasound scan (USS) results have supported the clinical AA diagnosis and showed an enlarged appendix and a periappendiceal abscess formation (3x4 cm).

A diagnosis of AA was made and the patient was prepared for an open appendectomy. The findings at surgery were macroscopically suggestive of AA with periappendicular abscess and no adjacent lymph nodes. His postoperative course was uneventful and he was discharged home with antibiotics and no gastrointestinal symptoms.

Fourteen days later, the histopathological examinations showed appendicitis and high grade B cell non-Hodgkin lymphoma consistent with BL in the thick-walled appendix (Figure 1).

The patient was referred to a specialist pediatric oncology unit where abdominal computerized tomography (CT) scan (Figure 2), positron emission tomography (PET) scan (Figure 3) and immunohistochemical studies were performed. These exams confirmed the histological diagnosis of abdominal BL. Immunohistochemical study showed the malignant cell

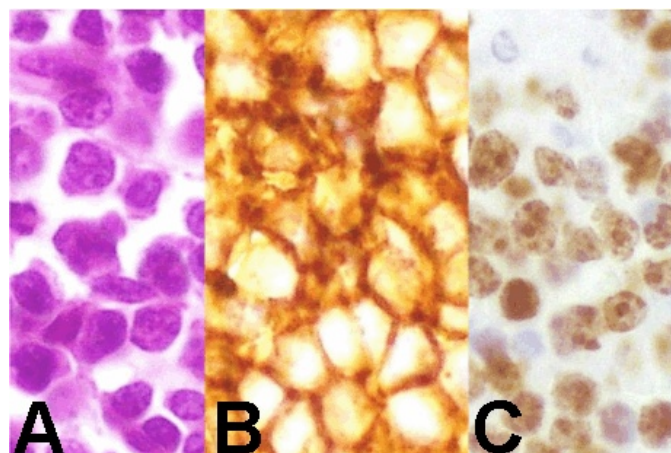


Figure 1: Microscopic examination of representative sections of the appendix revealed neutrophilic infiltration of mucosa and an intramural neoplasm. (A) H&E, (B) CD20 marker for mature B cells; C: Ki67 cell proliferation marker.

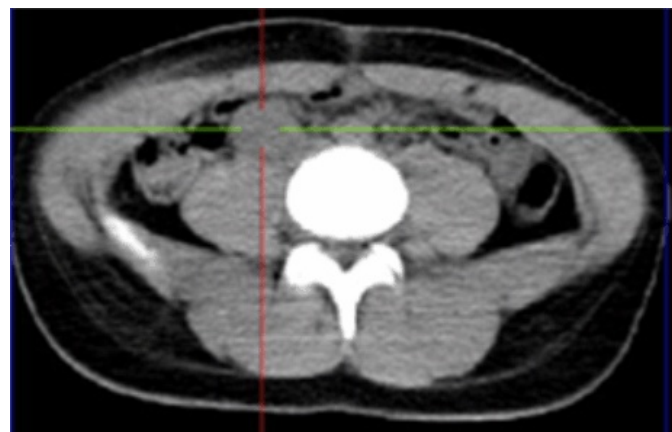


Figure 2: Computed tomography at the level of the upper pelvis shows a solid, 34x31x39 mm nodule adjacent to right iliopsoas muscle.

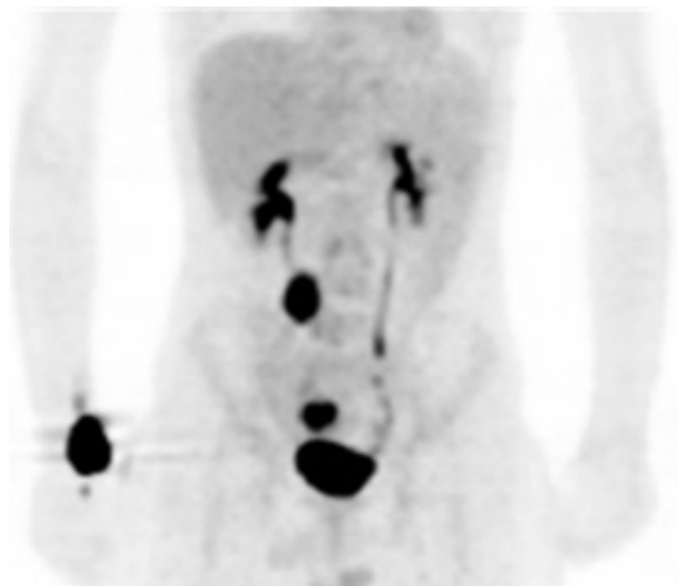


Figure 3: Metastasis to (or adjacent to) right iliopsoas muscle and paravesical detected by F-18 FDG PET-CT imaging.

population was positive for CD20, CD10 and BCL6 and negative for CD3 and MUM1. Chromosomal translocation 8q24 (myc gene) was reported.

Polychemotherapy according to the B-non-Hodgkin's lymphoma chemotherapy protocols (group B LMB protocol 2001) were administered [5]. Follow-up abdominal CT at four months, six months and one year was performed, and the patient is disease free and shows no signs of recurrence or metastasis.

## DISCUSSION

Appendiceal lymphomas are exceedingly rare and often diagnosed postoperatively. In a review of 29 patients with appendiceal lymphoma, Burkitt's lymphoma was diagnosed in 9 cases [6]. The clinical findings are nonspecific, leading to a delay in diagnosis. Primary appendiceal lymphoma may present clinically as acute appendicitis [7, 8]. Besides this association, the precise mechanism for the AA occurrence in patients with appendiceal lymphoma is not known, but obstruction could play a role in the pathogenesis of the AA [6].

BL is a rare and rapidly progressive tumor and commonly presents as an abdominal mass and long duration of symptoms and weight loss were two important clinical clues to the presence of gastrointestinal lymphoma. These symptoms were not present in our patient.

AA is the initial preoperative diagnosis of similar clinical presentation of periumbilical pain, low grade fever and anorexia. The clinical presentation and operative findings were highly suggestive of of AA with periappendicular abscess. The preliminary macroscopic pathological examination of terminal ileum revealed only a thickened mucosa. No periappendicular mass was apparent. The diagnosis of AA and LB were made in the



histopathological exam of biopsy fragment. There are already other cases of BL described presenting as suspicious AA, but usually it is secondary to ileocecal intussusceptions [9].

In this case, examination of the specimen never revealed discernible tumor. The entire appendix was submitted for microscopic examination. The fact that this lymphoma was discovered only in the histopathological exam raises questions about the importance of complete examination and acquisition of adequate appendix biopsies in children more than five years of age [10].

This tumor responds well to chemotherapy and the role of surgery remains controversial [11, 12]. In this case the tumor regressed completely after the chemotherapy and there are no signs of recurrence at 1 year of follow-up.

## CONCLUSION

AA is mostly diagnosed preoperatively but the histology is the gold standard exam for the diagnosis. The histopathological exam of the appendix is vital and should be mandatory for all patients with AA suspicious, even those with typical clinical presentation.

In this patient with histologically proved acute appendicitis the unexpected diagnosis of LB was made by the histology. This diagnosis was early and allowed a prompt treatment of the tumor which might have been life saving for this boy.

\*\*\*\*\*

## Acknowledgements

The authors wish to thank Dr. Fernando Parda who performed the histopathological exam.

## Author Contributions

Jean-Pierre Gonçalves – Conception and design, Acquisition of data, interpretation of data, Drafting the article, Final approval of the version to be published

Arnaldo Cerqueira – Conception and design, Acquisition of data, interpretation of data, Drafting the article, Final approval of the version to be published

Henedina Antunes – Conception and design, interpretation of data, Critical revision of the article, Final approval of the version to be published

Íris Maia – Conception and design, interpretation of data, Critical revision of the article, Final approval of the version to be published

Susana Carvalho – Conception and design, interpretation of data, Critical revision of the article, Final approval of the version to be published

## Guarantor

The corresponding author is the guarantor of submission.

## Conflict of Interest

Authors declare no conflict of interest.

## Copyright

© Jean-Pierre Gonçalves et al. 2012; This article is distributed under the terms of Creative Commons Attribution 3.0 License which permits unrestricted use, distribution and reproduction in any means provided the original authors and original publisher are properly credited. (Please see [www.ijcasereportsandimages.com/copyright-policy.php](http://www.ijcasereportsandimages.com/copyright-policy.php) for more information.)

## REFERENCES

1. Forteza-Vila J, Fraga M. Burkitt lymphoma and diffuse aggressive B-cell lymphoma. *Int J Surg Pathol* 2010;18(3 Suppl):133S–5S.
2. Smith SM, Anastasi J, Cohen KS, Godley LA. The impact of MYC expression in lymphoma biology: Beyond Burkitt lymphoma. *Blood Cells Mol Dis* 2010;45(4):317–23.
3. Wang SM, Huang FC, Wu CH, Ko SF, Lee SY, Hsiao CC. Ileocecal Burkitt's lymphoma presenting as ileocolic intussusception with appendiceal invagination and acute appendicitis. *J Formos Med Assoc* 2010;109(6):476–9.
4. Ghani SA, Syed N, Tan PE. A rare cause of acute appendicitis: Burkitt's lymphoma of the appendix. *Med J Malaysia* 1984;39(4):311–3.
5. Link MP, Shuster JJ, Donaldson SS, Berard CW, Murphy SB. Treatment of children and young adults with early-stage non-Hodgkin's lymphoma. *N Engl J Med* 1997;337(18):1259–66.
6. Fu TY, Wang JS, Tseng HH. Primary appendiceal lymphoma presenting as perforated acute appendicitis. *J Chin Med Assoc* 2004;67(12):629–32.
7. Pasquale MD, Shabahang M, Bitterman P, Lack EE, Evans SR. Primary lymphoma of the appendix. Case report and review of the literature. *Surg Oncol* 1994;3(4):243–8.
8. Muller G, Dargent JL, Duwel V, D'Olne D, Vanvuchelen J, Haot J, et al. Leukaemia and lymphoma of the appendix presenting as acute appendicitis or acute abdomen. Four case reports with a review of the literature. *J Cancer Res Clin Oncol* 1997;123(10):560–4.
9. Hoxha FT, Hashani SI, Krasniqi AS, Kurshumliu FI, Komoni DS, Hasimja SM, et al. Intussusceptions as acute abdomen caused by Burkitt lymphoma: a case report. *Cases J* 2009;2:9322.
10. Bethel CA, Bhattacharyya N, Hutchinson C, Ruymann F, Cooney DR. Alimentary tract malignancies in children. *J Pediatr Surg* 1997;32(7):1004–8; discussion 8–9.
11. Sehn LH. Management of Burkitt lymphoma: a continuing challenge. *Oncology (Williston Park)* 2008;22(13):1519, 22–3.
12. Patte C, Michon J, Frappaz D, Leverger G, Rubie H, Soussain C, et al. Therapy of Burkitt and other B-cell acute lymphoblastic leukaemia and lymphoma: experience with the LMB protocols of the SFOP (French Paediatric Oncology Society) in children and adults. *Baillieres Clin Haematol* 1994;7(2):339–48.

CASE REPORT

OPEN ACCESS

# Primary duodenal adenocarcinoma of the fourth portion diagnosed using double-balloon enteroscopy and surgically resected: A case report

Shingo Kawano, Koichi Sato, Hiroshi Maekawa, Mutsumi Sakurada, Hajime Orita, Ryo Wada

## ABSTRACT

**Introduction:** Primary duodenal adenocarcinoma is extremely rare. If this carcinoma occurs in fourth portion, it can now be diagnosed by recent developments in enteroscopy. **Case Report:** We report a rare case of primary duodenal adenocarcinoma of the fourth portion diagnosed by double-balloon enteroscopy and resected surgically. A 57-year-old man was anemic. PET-CT revealed accumulation in the fourth portion of the duodenum. Double-balloon enteroscope showed circular tumor of the fourth portion of the duodenum, and biopsy disclosed poorly differentiated adenocarcinoma. Partial duodenectomy and partial colectomy were performed. The marginal artery of the transverse colon was invaded. Histological examination disclosed that the tumor was poorly differentiated adenocarcinoma and two lymph node metastases were seen. **Conclusion:** Primary duodenal adenocarcinoma of fourth portion can be diagnosed by double-balloon enteroscopy and treated by surgical resection.

Shingo Kawano<sup>1</sup>, Koichi Sato<sup>1</sup>, Hiroshi Maekawa<sup>1</sup>, Mutsumi Sakurada<sup>1</sup>, Hajime Orita<sup>1</sup>, Ryo Wada<sup>2</sup>

**Affiliations:** <sup>1</sup>Department of Surgery, Juntendo Shizuoka Hospital, Juntendo University School of Medicine, 1129 Nagaoka, Izunokuni-shi, Shizuoka 410-2295, Japan; <sup>2</sup>Department of Pathology, Juntendo Shizuoka Hospital, Juntendo University School of Medicine, 1129 Nagaoka, Izunokuni-shi, Shizuoka 410-2295, Japan.

**Corresponding Author:** Shingo Kawano, Department of Surgery, Juntendo Shizuoka Hospital, Juntendo University School of Medicine, 1129 Nagaoka, Izunokuni-shi, Shizuoka 410-2295, Japan; Ph: +81-55-948-3111; Fax: +81-55-946-0514; Email: shingoshingo2000jp@yahoo.co.jp

Received: 25 October 2011  
Accepted: 17 January 2012  
Published: 01 November 2012

**Keywords:** Double-balloon enteroscopy, Primary duodenal adenocarcinoma, The fourth portion

\*\*\*\*\*

Kawano S, Sato K, Maekawa H, Sakurada M, Orita H, Wada R. Primary duodenal adenocarcinoma of the fourth portion diagnosed using double-balloon enteroscopy and surgically resected: A case report. International Journal of Case Reports and Images 2012;3(11):35–39.

\*\*\*\*\*

doi:10.5348/ijcri-2012-11-218-CR-11

## INTRODUCTION

Primary duodenal adenocarcinoma is extremely rare, accounting for 0.3~0.4% of all gastrointestinal cancers [1]. It is too difficult to anatomically diagnose primary duodenal adenocarcinoma of the fourth portion. However, primary duodenal adenocarcinoma of the fourth portion can be diagnosed by recent developments in enteroscopy. Here we report a case of duodenal adenocarcinoma of the fourth portion diagnosed by double-balloon enteroscopy and resected surgically, and discuss it based on a review of literature.

## CASE REPORT

A 57-year-old Japanese male was admitted to our hospital in December 2009 for evaluation of severe anemia. Past medical history included a gastric ulcer when he was 50-years-old. His family history was noncontributory. Physical examination on admission revealed a body height of 175 cm, weight of 63 kg, blood pressure of 112/61 mmHg, a regular pulse of 85/min, and body temperature of 36.8°C. There was no sign of



lymphadenopathy. His abdomen was soft and flat, and no abdominal, liver, or spleen masses were palpable.

There were no abnormal laboratory findings, except evidence of anemia (hemoglobin was 6.6 g/dL) and an inflammatory reaction (white blood cell count was 8900/ $\mu$ g, and C-reactive protein was 3.7 mg/dL). Tumor markers, carcinoembryonic antigen (CEA) and carbohydrate antigen (CA19-9), were within normal ranges.

Abdominal computed tomography (CT) scan indicated a circumferential, thick, and unequally enhanced wall in the fourth portion of the duodenum, and showed no lymph node swelling or ascites. Upper gastrointestinal series demonstrated a 7-cm ‘apple core’ sign in the fourth portion of the duodenum (Figure 1). Double-balloon enteroscopy showed a circumferential tumor with ulceration in the fourth portion of the duodenum (Figure 2). The enteroscope could not pass

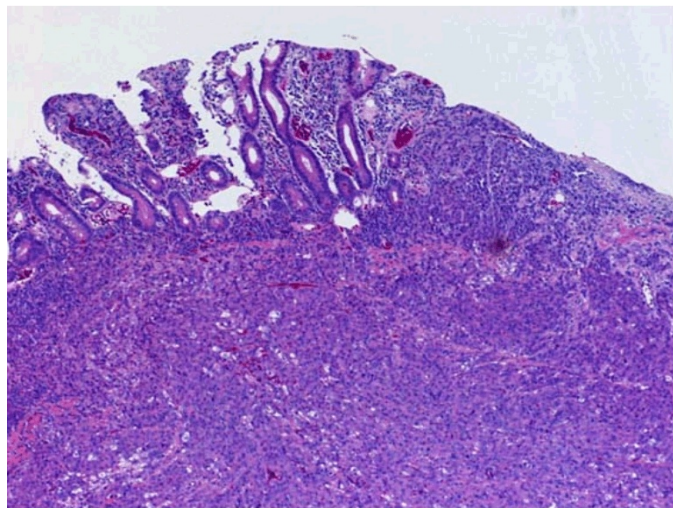


Figure 1: Upper gastrointestinal series: A 7-cm ‘apple core’ sign was found in the fourth portion of the duodenum.

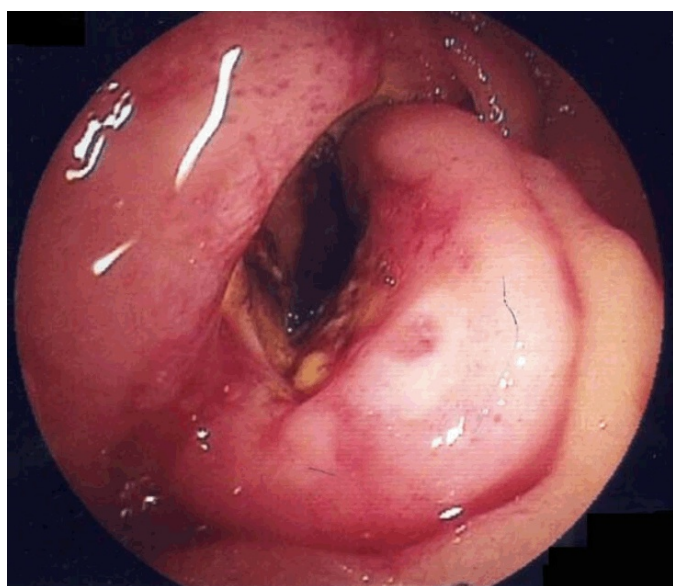


Figure 2: Double-balloon enteroscopy: A circumferential tumor with ulceration in the fourth portion of the duodenum.

the lesion. Biopsy specimen from the lesion disclosed poorly differentiated adenocarcinoma. Positron Emission Tomography (PET) revealed accumulation in the fourth portion of the duodenum (Figure 3). Based on these findings, the patient was diagnosed with primary duodenal adenocarcinoma of the fourth portion and underwent partial duodenectomy and partial colectomy because the marginal artery of the transverse colon was invaded by the tumor on January 22nd, 2010.

The resected tumor had deep ulceration with a round wall and measured 100×80 mm in size (Figure 4).

Histological examination disclosed that the tumor was poorly differentiated adenocarcinoma which invaded into the subserosal layer and two lymph node metastases were seen (Figure 5).

The patient had an uneventful postoperative course, and was discharged from hospital 40 days postoperatively. Combined chemotherapy of TS-1 and

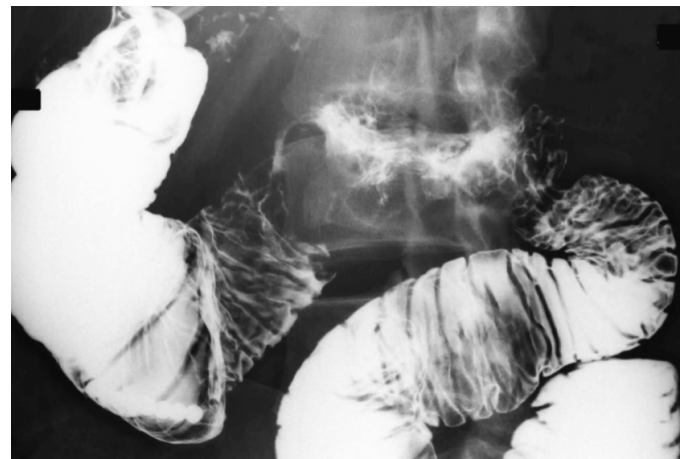

Figure 3: Surgical specimen: The resected tumor displayed deep ulceration with a round wall and measured 100×80 mm in size.

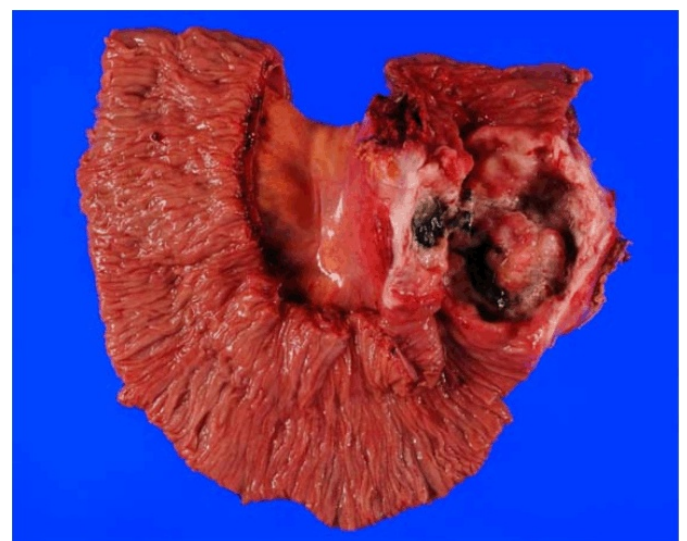


Figure 4: Histological findings: Poorly differentiated adenocarcinoma had invaded the subserosal layer. Two lymph node metastases were also detected.

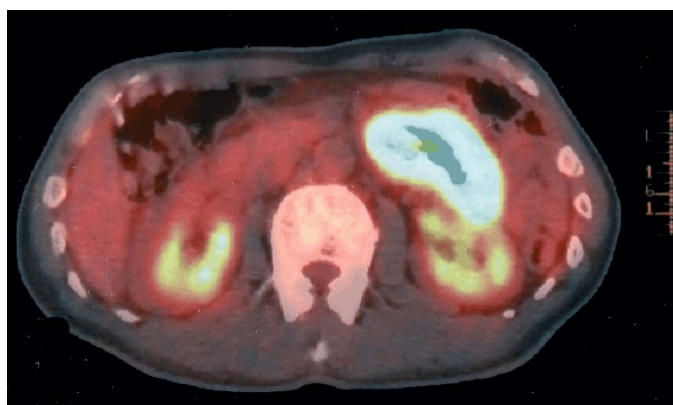


Figure 5: Positron Emission Tomography (PET): There was accumulation in the fourth portion of the duodenum.

cisplatin was prescribed as neoadjuvant chemotherapy. TS-1 (80 mg/m<sup>2</sup>) was administered 21 days, followed by 14 days rest as one course. Cisplatin (60 mg/m<sup>2</sup>) was administered on the eight day. Six courses of this adjuvant chemotherapy were administered. The patient is alive with no recurrence for one year.

## DISCUSSION

Primary duodenal adenocarcinoma is extremely rare. Most primary duodenal adenocarcinomas are in the first and second portions, with 20% in the third portion, and 10% in the fourth portion [2]. Recently, reports of

primary duodenal adenocarcinoma have been increasing because of progresses in gastric endoscopy [3, 4]. However, it is impossible to diagnose primary duodenal adenocarcinoma of the third and fourth portions by gastric endoscopy. There are still many cases to be diagnosed by the upper gastrointestinal series. In this case, primary duodenal adenocarcinoma of the fourth portion was diagnosed by double-balloon enteroscopy. In Japan, there are no case reports of primary duodenal adenocarcinoma of the fourth portion diagnosed by double-balloon enteroscopy. In Brazil, there is only one case report [5].

In Japan, there are eleven case reports of primary duodenal adenocarcinoma of the fourth portion resected surgically, including our case [5–16] (Table 1). The median age was 60.5 years (range, 42–74 years). Six cases were men. Two cases invaded into the mucosal layer, three cases into the subserosal layer, and six cases went beyond the serosal layer. Seven cases had metastasis of the lymph nodes. According to these reports, there are two kinds of surgery, three cases of pylorus preserving pancreatoduodenectomy and partial duodenectomy and eight cases of partial duodenectomy with lymphadenectomy. In Kaklamanos's report, there was no significant difference in prognosis between pancreatoduodenectomy and partial duodenectomy in sixty-three cases of primary duodenal adenocarcinoma [16]. In Lowell's report, the seven cases of primary duodenal adenocarcinoma of the third or fourth portions are all alive after five years, except for those who died of another disease [17]. Five of seven cases underwent partial duodenectomy. There are many

Table 1: Cases of the primary adenocarcinoma of the fourth portion of the duodenum reported in Japan

Author	Year	Age/Sex	Operation	Depth*	N	Prognosis
Adachi	1991	55/F	SD	SE	+	Unknown
Umehara	1996	42/F	PPPD	SE	+	24 mth. dead
Oshiro	2000	51/F	SD	SE	-	24 mth. alive
Saito	2001	54/M	SD	SE	+	Unknown
Hosokaewa	2003	74/F	SD	M	-	24 mth. alive
Maeda	2004	58/F	PPPD	SS	+	16 mth. alive
Suzuki	2005	66/M	PPPD	SE	+	24 mth. alive
Kinoshita	2006	65/M	SD	SS	-	11 mth. alive
Miyawaki	2006	72/M	SD	SE	+	30 mth. alive
Ishizaki	2008	72/M	SD	M	-	30 mth. alive
Our case	2010	57/M	SD	SS	+	12 mth. alive

PPPD: pylorus-preserving pancreatoduodenectomy, DS: segmental duodectomy, \*: Depth was expressed according to Japanese Classification of Gastric Carcinoma (The 14th Edition), mth.: Month



reports that partial duodenectomy is better in the case of primary duodenal adenocarcinoma in the third or fourth portions. Consequently, partial duodenectomy was thought to be a better surgery for primary distal duodenal adenocarcinoma. However, in Suzuki's report, a case of primary duodenal adenocarcinoma of the fourth portion underwent pancreatoduodenectomy [12]. There were metastases of the lymph nodes in No. 13 and No. 14 according to the Japanese classification of gastric carcinoma (The 14th Edition). That report insisted on the necessity of pancreatoduodenectomy with lymphadenectomy. Our case underwent partial duodenectomy with lymphadenectomy. There was no recurrence for one year in spite of advanced carcinoma and metastasis of the lymph nodes.

## CONCLUSION

We reported an extremely rare case of primary duodenal adenocarcinoma of the fourth portion diagnosed by double-balloon enteroscopy and resected surgically.

\*\*\*\*\*

## Author Contributions

Shingo Kawano – Substantial contributions to conception and design, Acquisition of data, Analysis and interpretation of data, Drafting the article, Revising it critically for important intellectual content, Final approval of the version to be published

Koichi Sato – Acquisition of data, Revising it critically for important intellectual content, Final approval of the version to be published

Hiroshi Maekawa – Acquisition of data, Revising it critically for important intellectual content, Final approval of the version to be published

Mutsumi Sakurada – Acquisition of data, Revising it critically for important intellectual content, Final approval of the version to be published

Hajime Orita – Acquisition of data, Revising it critically for important intellectual content, Final approval of the version to be published

Ryo Wada – Acquisition of data, Revising it critically for important intellectual content, Final approval of the version to be published

## Guarantor

The corresponding author is the guarantor of submission.

## Conflict of Interest

Authors declare no conflict of interest.

## Copyright

© Shingo Kawano et al. 2012; This article is distributed under the terms of Creative Commons Attribution 3.0 License which permits unrestricted use, distribution and reproduction in any means provided the original authors and original publisher are properly credited.

(Please see [www.ijcasereportsandimages.com/copyright-policy.php](http://www.ijcasereportsandimages.com/copyright-policy.php) for more information.)

## REFERENCES

1. Tocci A, Mazzoni G, Puma F, et al. Adenocarcinoma of the third and fourth portions of the duodenum: results of surgical treatment. *Arch Surg* 2003;138:80–5.
2. Shunsuke O, Gakuto K, Yoshihisa S, et al. A Clinicopathological Study of Our 10 Cases with Primary Carcinoma of the Duodenum. *The Japanese Journal of Gastroenterological Surgery* 2006;39:1458–63.
3. Rose DM, Hochwald SN, Klimstra DS, Brennan MF. Primary duodenal adenocarcinoma: a ten-year experience with 79 patients. *J Am Coll Surg* 1996;183:89–6.
4. Santoro E, Sacchi M, Scutari F, Carboni F, Graziano F. Primary adenocarcinoma of the duodenum: treatment and survival in 89 patients. *Hepatogastroenterology* 1997;44:1157–63.
5. Safatle-Ribeiro AV, Franzini TA, Kuqa R, et al. Double-balloon enteroscopy in the diagnosis of an adenocarcinoma of the fourth portion of the duodenum: report of a case. *Clinics (Sao Paulo)* 2007 Jun;62(3):353–6.
6. Keiichi A, Shiro F, Noriyuki A. A case of an advanced duodenal cancer of the fourth portion. *Clinics in Bowel Diseases* 1991;4:24–7.
7. Yasuhiko U, Tadatoshi O, Yoshihiko S, Toshio N, Naomi W, Ryutaro M. A case of an advanced duodenal cancer of the fourth portion. *Surgical Diagnosis & Treatment* 1996;38:1337–40.
8. Yoshio O, Kazuo S, Fuminori A, et al. A case of duodenal adenocarcinoma of the fourth portion diagnosed. *The Journal of the Hiroshima Medical Association* 2000;53:414–7.
9. Shuji S, Itaru E, Takafumi K, et al. A case of curatively resected duodenal cancer of the fourth portion. *The Japanese Journal of Gastroenterological Surgery* 2001;34:485–9.
10. Yukako H, Shigehiro K, Kimiyasu Y, et al. A case of duodenal polypoid intramucosal adenocarcinoma observed for six years. *Gastroenterological endoscopy* 2003;45:1130–4.
11. Tetsuya M, Akira T, Hironori K. A Case Report of Primary Duodenal Carcinoma of the Fourth Portion. *Journal of Japanese College of Surgeons* 2004;29:884–9.
12. Ryo S, Norichika M, Kentaro N, Akimasa Y, Takahisa M, Tomoaki M. A Case of Primary Adenocarcinoma of the Fourth Portion of the Duodenum Curatively Resected by Pylorus-Preserving Pancreatoduodenectomy. *The Japanese Journal of Gastroenterological Surgery* 2005;38:429–34.
13. Hiroyuki K, Katsutoshi T, Takeshi T, et al. A Resected Case of Primary Adenocarcinoma of the Fourth Portion of the Duodenum. *The Japanese Journal of Gastroenterological Surgery* 2006;39:1380–4.
14. Kiichiro M, Koichi T, Yu N, Daisuke K, Mitsumasa A, Shinji T. A case of duodenal cancer of the fourth portion detected by routine gastroduodenoscopy. *Gastroenterological endoscopy* 2006;48:2639–44.

15. Tetsuo I, Makoto T, Takashi O, et al. A case of early cancer of the fourth portion of the duodenum. *The Japanese Journal of Gastroenterological Surgery* 2008;41:516–20.
16. Kaklamanos IG, Bathe OF, Franceschi D, Camarda C, Levi J, Livingstone AS. Extent of resection in the management of duodenal adenocarcinoma. *Am J Surg* 2000;179:37–41.
17. Lowell JA, Rossi RL, Munson JL, Braasch JW. Primary adenocarcinoma of third and fourth portions of duodenum, favorable prognosis after resection. *Arch Surg* 1992;127:557–60.

CASE REPORT

OPEN ACCESS

# Unique presentation with trimodal transfer of a patient with traumatic bilateral anterior (obturator) hip dislocation

Rishya Manikam, CS Kumar, Kunalan G, AB Sri Latha, Nasir Mohamad

## ABSTRACT

**Introduction:** Bilateral anterior hip dislocation presenting late with complete recovery with no complication is unusually rare. **Case Report:** A 39-year-old manual labor presented with bilateral anterior hip dislocation with non-specific neurology following an industrial accident 20 hours post injury. Closed manual reduction required femoral block, spinal and general anaesthesia with three surgeons engaging a maneuver not previously described. Subsequently, skin traction was applied for two weeks and was discharged with non-weight bearing advice for another four weeks. Patient on his regular clinic follow up was subjected to various modalities of physiotherapy in view of his job nature requiring early return to work. Regular follow-up of three years did not reveal any evidence of avascular necrosis of the femoral heads and he obtained full function of both his hip joints. **Conclusion:** The mode of transport which results in the delay in seeking treatment.

**Keywords:** Traumatic, Anterior, Bilateral, Hip Dislocations

\*\*\*\*\*

Manikam R, Kumar CS, Kunalan G, Latha ABS, Mohamad N. Unique presentation with trimodal transfer of a patient with traumatic bilateral anterior (Obturator) hip dislocation. International Journal of Case Reports and Images 2012;3(11):40–42.

\*\*\*\*\*

doi:10.5348/ijcri-2012-11-219-CR-12

## INTRODUCTION

Bilateral traumatic anterior hip dislocations caused by industrial accident is rare. Its rarity is evident with only eleven cases reported in English literature [1]. Here we report a case of traumatic bilateral anterior hip dislocation; its presentation delay, mechanism of injury, mode of patient transfer to hospital and the modified reduction technique. We also reviewed literature on the various modality of treatment advocated for this unusual presentation.

## CASE REPORT

A 39-year-old manual labor at a construction site from a rural area with poor transportation infrastructure, first presented to our emergency room 20 hours post injury to both his hips. He was in a squatted position at the time of injury. A brick impacting machine lost control and compressed him from the front and back, fulcruming his perineum against the hard ground. He fell forward with both his hips in full flexion, wide abduction and external rotation. He was in prone position for about 20 minutes

Rishya Manikam<sup>1</sup>, CS Kumar<sup>2</sup>, Kunalan G<sup>2</sup>, A.B. Sri Latha<sup>1</sup>, Nasir Mohamad<sup>3</sup>  
**Affiliations:** <sup>1</sup>Trauma And Emergency Department, University Malaya Medical Centre, Kuala Lumpur, <sup>2</sup>Orthopedics Department, University Malaya Medical Centre, Kuala Lumpur; <sup>3</sup>Accident And Emergency Department, University Science Malaysia Medical Centre, Kota Bahru.

**Corresponding Author:** Dr. Rishya Manikam, Head, Trauma And Emergency Department, University Malaya, Lembah Pantai, 50603, Kuala Lumpur, Malaysia; Ph: +60379494198; Fax: +60379494198; Email: rishyaman@yahoo.com

Received: 31 October 2011  
Accepted: 23 January 2012  
Published: 01 November 2012

before getting help to lie in supine position. He was not able to move his hips and being in an awkward position, he was carried by his colleagues where one of them supported the torso by holding under his armpits and two others held his back and pelvis with their bare hands. The fourth colleague supported both the lower limbs to prevent them from too much movement. He was shifted onto the back of a 4-wheel drive which took them to a riverside where a boat was waiting for them. As there were no available splints, his colleagues used tree branches to anchor him to the boat. He was in the same position for another 45 minutes of the boat ride which took him to a helicopter landing site. Upon arrival to the site, he was again carried by his colleagues in the same manner to a helicopter waiting to transport him to a general hospital. With the help of a trained paramedic, the patient was then secured in the passenger bay of the helicopter using several safety harnesses. The paramedic also administered intravenous Pethidine to calm the patient during the air transfer. In short, a trimodal mode of transport was used in transferring the patient to definitive care.

Though he was spared of other major organ injuries, his complaints were severe pain, deformity and inability to move both his hips. Examination revealed both his hips were in wide abduction, flexion and external rotation. Passive movement of his hips was nearly impossible. There was patchy neurology in both the lower limbs. The myotome or dermatome could not be specified to either solely L1, L2, etc. as the patient had a mixture of all the dermatomes in a patchy manner. Nevertheless, post reduction, there was no neurology.

No foot drop was noted as the patient had a multimodal transfer in which an anticipation of foot drop was expected. We assumed that since non-trained individuals helped with the transfer, there could be a possibility of his leg undergoing traction at some point of the transfer. Fortunately, the femoral nerve was not affected in patient. There were superficial facial injuries and he was hemodynamically stable. Appropriate analgesics were administered to counter his severe pain prior to the radiographs. Radiographic studies revealed bilateral anterior hip dislocations into the obturator foramen (Figure 1).

Close reduction using 75 mg Pethidine and 7.5 mg Midazolam as sedation was unsuccessful. In the operating room, initially, bilateral femoral block was attempted with great difficulty by the anaesthetist in view of the awkward positioning of the patient. Though successful, it was inadequate to counter the muscle spasm but it was sufficient to position the patient for spinal anesthesia. In spite of successful spinal anesthesia, it was difficult for both surgeons and patient to co-operate with the external close maneuvers. Though the anaesthetist preferred the regional block but due to poor response of the patient, general anaesthesia was finally given. The general anaesthetic was conducive for the surgeons to perform the maneuvers as the patient was fully relaxed. Unlike individual hip posterior dislocation, where counter-traction to the anterior iliac crest and hip flexion to 90 degrees, slight

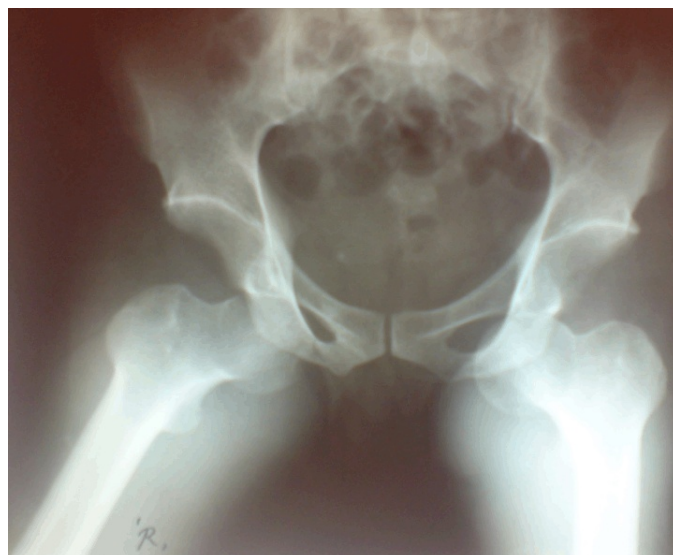

Figure 1: Bilateral Anterior Hip Dislocation into Obturator Foramen

abduction while pulling in line with the femur would suffice to reduce the dislocation, this type of dislocation did not respond to the usual method.

In this patient, we first placed a sandbag over the sacrum in line with the spine to obtain sag of both the gluteal muscles. Then, we engaged one surgeon for pelvic stabilization by traction-counter-traction over the anterior iliac crest and perineum. Two other surgeons simultaneously applied axial traction to each leg with internal rotation and application of pressure to the medial side of the proximal thigh bringing the femoral head towards the acetabulum and adduction. Both the hips reduced simultaneously. Post reduction telescoping proved its stability upon reduction. Post reduction radiographs showed the hips were correctly positioned and did not reveal any fractures. No CT or MRI was done post reduction as the centre was not equipped with one at that time. We were dependent on the radiographs and the clinical outcome. There were no foot drops.

Subsequently, skin traction was applied for two weeks in the ward. Wheel chair mobilization was commenced with regular ultrasound heat therapy and static quadriceps and calf exercises. He was discharged from the ward with non-weight bearing advice for another four weeks. On follow-up at one month, we were rather surprised to see him fully weight bear without any pain and having full range of movement over his hip joints. The patchy neurology fully recovered. He was back to full manual labor the following week. Six monthly follow-up for three years with radiographs did not reveal any evidence of avascular necrosis of both femoral heads and patient was pain free.

## DISCUSSION

Hip dislocations are becoming more common due to increased high velocity road traffic accidents. Posterior hip dislocations are more common. Anterior hip



dislocations are being reported to occur in only 10–11% of the total hip dislocations. Bilateral, simultaneous anterior hip dislocations are even rarer and a number of cases have been reported by different authors. The most common cause in most of the cases reported has been road traffic accident. In our case, it was an industrial accident and the mechanism of injury that made this case unique. Nevertheless, all the authors highlighted on the position of the hips at the time of impact being in extreme abduction and flexion [1, 2].

Patients with bilateral anterior dislocation usually present with flexed, externally rotated leg and abducted hips. Radiographs are usually diagnostic but in case of doubt, CT scan will definitely reveal the type of dislocation. Anterior hip dislocation can be classified as obturator, perineum and pubic. The direction of the hip dislocation depends on the position of the hip at the time of impact [3, 4].

Most authors used the Allis's maneuvers to achieve reduction i.e., patient in supine position, knee flexed, pelvis stabilized, lateral traction force to inside of thigh, longitudinal traction is applied in line with axis of femur, and hip in slightly flexed position. The essential feature is traction in line of deformity, followed by gentle flexion of hip to 90 degrees. The hip is gently rotated internally and externally with continued longitudinal traction until reduction is achieved. These maneuvers are ideally done under general anaesthesia. In our case, three modalities of anesthesia were used to get the ideal relaxation of the muscles in spasm. This technique was used after fully understanding the various forces acting onto the hip joints at the time of injury. Patient's compliance to post reduction therapy and urgency to return to active work also contributed to defying the golden rule for Avascular Necrosis (AVN) [5–7].

The bilateral anterior hip dislocations in this case were a rare and significant injury. The outcome of the treatment was encouraging. Although we realize that the usefulness of data based on a single case is limited, we are encouraged by the outcome in this case and believe that the technique used is a viable option in bilateral anterior hip dislocation.

## CONCLUSION

The time taken in seeking immediate treatment for bilateral anterior hip dislocation is essential for good outcome. Although there was a significant delay in seeking treatment in this patient due to the logistic mode of transfer, the patient was lucky to have a complete recovery. It is essential to improve the prehospital care aspect especially in the rural areas.

\*\*\*\*\*

## Author Contributions

Rishya Manikam – Conception of design, Acquisition of data, Analysis and interpretation of data, Drafting the

article, Critical revision of the article, Final approval of the version to be published

CS Kumar – Conception of design, Acquisition of data, Analysis and interpretation of data, Drafting the article, Critical revision of the article, Final approval of the version to be published

Kunalan G – Conception of design, Acquisition of data, Analysis and interpretation of data, Drafting the article, Critical revision of the article, Final approval of the version to be published

A B Sri Latha – Conception of design, Acquisition of data, Analysis and interpretation of data, Drafting the article, Critical revision of the article, Final approval of the version to be published

Nasir Mohamad – Conception of design, Acquisition of data, Analysis and interpretation of data, Drafting the article, Critical revision of the article, Final approval of the version to be published

## Guarantor

The corresponding author is the guarantor of submission.

## Conflict of Interest

Authors declare no conflict of interest.

## Copyright

© Rishya Manikam et al. 2012; This article is distributed under the terms of Creative Commons Attribution 3.0 License which permits unrestricted use, distribution and reproduction in any means provided the original authors and original publisher are properly credited. (Please see [www.ijcasereportsandimages.com/copyright-policy.php](http://www.ijcasereportsandimages.com/copyright-policy.php) for more information.)

## REFERENCES

1. Anna Domingo, Josep M. Segur, Lazaro Saz, Sebastian Garcia-Ramiro. Unusual traumatic anterior bilateral hip dislocation. *J Orthop Surg Traumatol* 2008;18:475–8.
2. R. Tezcan, R. Erginer, M. Babacan. Bilateral Traumatic Anterior Dislocation Of The Hip: Brief Report. *J Bone Joint Surg(Br)* 1988;70-B:148–9
3. T S Sethi, M K Mam, R K Kakroo. Bilateral Traumatic anterior dislocation of the hip. *The Journal of Trauma* 06/1987;27(5):573–4.
4. N Terahata, H Matsui, N Makiyama. Bilateral anterior dislocations of the hips. *International Orthopaedics* 02/1996;20(2):125–6.
5. A L Akinyoola, A A Abiodun. Bilateral traumatic anterior hip dislocation—a case report. *West African journal of medicine*. 24(3)272–3.
6. Zamani MH et al. Bilateral traumatic anterior dislocation of hip: case report. *Clin Orthop* 1981;161:203–6.
7. Gibbs A. Bilateral obturator dislocation of the hip joint. *Injury* 1981;12:250–1.

CASE REPORT

OPEN ACCESS

# Knowing your lab test well: Expanding the differential for elevated alkaline phosphatase

Sachin Kumar Amruthlal Jain, Kashyap Patel, Yousif Ismail,  
Michael Williams

## ABSTRACT

**Introduction:** It is known that increased alkaline phosphatase with a distended gallbladder increases the suspicion of pancreatic malignancy. But benign etiology can be present, including a fasting state. **Case Report:** Our patient, a 58-year-old African–American female with a history of recurrent UTI presented to the emergency room with nausea and vomiting and loss of appetite for last five days. Physical exam was unremarkable except for dehydration. Initial laboratory test were normal including liver function tests, except for alkaline phosphatase level which was elevated to 216 (normal 35–120). She was started on intravenous fluids and antibiotics. Her symptoms improved and she tolerated a high protein and carbohydrate diet. She underwent an abdominal ultrasound of the right upper quadrant (2nd day of admission). It showed distended gallbladder and dilated common bile duct. No stones were seen and the liver was homogenous without masses. Gastroenterologist performed the EGD (3rd day of admission) which was benign. Her initial alkaline phosphatase trended down but started to rise again. The 5' Nucleotidase was normal. An

abdominal CT scan was performed (5th day of admission) showed no pancreatic mass, a contracted gallbladder and normal common bile duct. She was discharged home on oral antibiotics and a food supplement. Her follow up alkaline phosphatase was normal. **Conclusion:** Believe that our patient's generalized weakness, weight loss, as well as her increased alkaline phosphatase, distended gallbladder and common bile duct dilation can be attributed to her fasting state. During this, alkaline phosphatase activity is increased. It is a component of regulatory mechanisms, by increased delivery of the enzyme to the blood and respective decrease and increase of the maximal velocities of the enzyme reactions. Studies done on rats and elephant seals showed that not only with fasting, but also with refeeding, alkaline phosphatase activity increases. Some studies have shown that fasting can cause phases of dilatation and phases of contraction of gallbladder which phases of maxima dilatation at 12 a.m. and 4 p.m., and maxima contraction at 8 a.m. and 4 p.m. Thus, we are inclined to conclude that starvation and refeeding have played role in our patient's presentation timing is the key.

**Keywords:** Alkaline phosphatase, Starvation, Refeeding, Gallbladder dilatation

\*\*\*\*\*

Jain SKA, Patel K, Ismail Y, Williams M. Knowing your lab test well: Expanding the differential for elevated alkaline phosphatase. International Journal of Case Reports and Images 2012;3(11):43–46.

\*\*\*\*\*

doi:10.5348/ijcri-2012-11-220-CR-13

Sachin Kumar Amruthlal Jain<sup>1</sup>, Kashyap Patel<sup>1</sup>, Yousif Ismail<sup>1</sup>, Michael Williams<sup>1</sup>

**Affiliations:** <sup>1</sup>Department of Internal Medicine, Providence Hospital and Medical Centers, Southfield, MI

**Corresponding Author:** Sachin Kumar Amruthlal Jain, MD, Department of Internal Medicine, Providence Hospital and Medical Centers, 16001 W. Nine Mile Road, Southfield, MI. 48075; Ph: 248 849 3968; Fax: 248 849 3151; Email: doctorsachin@gmail.com

Received: 04 November 2011

Accepted: 26 March 2012

Published: 01 November 2012

## INTRODUCTION

Elevated alkaline phosphatase in the setting of a distended gallbladder and dilated common bile duct increase the suspicion of benign as well as malignant conditions, including pancreatic carcinoma. We present a case with such findings without any gross underlying pathology. Could these findings also present secondary to starvation?

## CASE REPORT

Our patient is a 58-year-old African–American female with a history of recurrent urinary tract infection. She presented to the emergency room with nausea, vomiting, and anorexia for the last five days. She also reported modest weight loss. Her history was significant for a recent emergency room visit for a seizure, secondary to a sub-therapeutic phenytoin level. At that time, she was also diagnosed with a urinary tract infection, and placed on an oral antibiotic regimen.

The physical exam was significant for dry mucosa and tongue, with a blood pressure of 100/62 mmHg. The exam was otherwise unremarkable. Initial laboratory examination showed hemoglobin of 12.8, and a white blood cell count of 17.8. Electrolytes, BUN, creatinine, and liver function tests were all normal, with the exception of an elevated alkaline phosphatase level (ALP) of 216 (normal 35 to 120). In the ER, intravenous fluids and intravenous antibiotics were administered. As her symptoms improved with antiemetic, she was started on a liquid diet. Her prealbumin was checked later on, and found to be 9 (Normal > 17).

Day 2: An ultrasound of the right upper quadrant of her abdomen was completed due to concerns over her elevated ALP. It showed a distended gallbladder with a dilated common bile duct of 9 mm. Stones were not visualized, and the liver was homogenous, without any masses. The gastroenterology (GI) service was consulted.

Day 3: The GI service performed an esophagogastroduodenoscopy (EGD). The study showed small esophageal ulcers and mild scarring of the distal esophagus, attributed to reflux. The study was otherwise unremarkable. During this time, there had been a downtrend in the patient's ALP. A 5' nucleotidase level was found to be within normal limits. Considering the improvement in laboratory and clinical findings, further invasive testing was not performed. The patient was tolerating feeds at this time and had been advanced to a high protein, and carbohydrate diet.

Day 4: The patient's ALP levels were rising again on the fourth day. This was confirmed with a second test to rule out any laboratory errors. Accordingly, the GI service scheduled the patient for an MRI cholangiogram, and pancreaticogram to be done later on in the day. However, these tests could not be performed without clearance from the neurology service, as this patient had prior stents placed for a brain aneurism.

Day 5: We chose to forego the MRI studies altogether and proceed with an abdominal CT scan on the fifth day, in hopes of finding an etiology for the elevated ALP. The CT scan visualized a pancreas that was free of any masses. The gallbladder was contracted, and the common bile duct could not be visualized. The study as a whole was unremarkable.

Day 6: The patient felt well, and her prealbumin level had risen to 14 from 9. ALP levels demonstrated a second downtrend. Considering that the work up was negative, and her symptoms had resolved, the patient was discharged home on oral antibiotics for her urinary tract infection, and a nutrition supplement.

One month later, she followed up in the clinic. She was doing well without any complaints and her ALP level was rechecked and was found to be within normal limits.

## DISCUSSION

There are three isoenzymes of alkaline phosphatase (ALP). Two different genes code for ALP of intestinal and placental origin (during the third trimester). A third gene codes for ALP synthesized by multiple organs including the liver, bones, and kidneys. The 5' nucleotidase may be helpful in delineating which isotype is elevated in the serum, as this test may be abnormal in cases of liver pathology.

The 5' nucleotidase test in our patient was within normal limits. However, the results of this test should be interpreted cautiously. This test is better used for ruling in hepatic pathology rather than ruling it out (the specificity is better than its sensitivity) [1]. Additionally, our patient presented with gastrointestinal complaints. A process involving the liver could not be completely ruled out.

The initial ultrasound showed a distended gallbladder, and dilated common bile duct but failed to demonstrate cholelithiasis. Additionally, the patient did not have clinical signs or laboratory results consistent with jaundice. As such, an acute obstructive process (e.g. choledocholithiasis) was less likely to be the cause. The subsequent workup, including an EGD and abdominal CT scan failed to show any gross obstructive or inflammatory etiologies responsible for the dilated CBD. The negative workup ultimately led us to conclude that this patient's chief complaints of nausea, vomiting, and anorexia were most likely secondary to her UTI.

It could be argued that this isolated elevation in ALP may have been related to phenytoin use [2]. However, we must recall that the patient's ALP level fluctuated throughout the hospital stay, and the gallbladder was, indeed, distended upon admission.

Studies done in animals may suggest a possible etiology for the elevated ALP. Recall that due to the nausea, vomiting and loss of appetite, our patient had not eaten for the last five days. Studies in animals have shown that starvation has been associated with changes in serum ALP activity. While one study demonstrated a decrease in serum ALP activity in fasting rats, two other



studies showed increased in fasting seal pups and female monkeys [3–5]. One study also showed increased serum ALP activity upon refeeding fasting rats [6]. Fasting and refeeding have also been associated with disturbances of ALP activity (increases as well as decreases) in histological sections of the intestine, liver and fat of different animals [7–9].

A study done in Sweden, examined metabolic abnormalities in teenage girls (mean age 15 years) with eating disorders [10]. ALP was among the tests performed in 251 subjects. When adjusted for their age, most of the ALP levels were either lower than the reference range, or marginally normal. One possible conclusion of this study could be that the fasting state affected the ALP levels only slightly (and in the opposite direction from which we observed in our patient). However, to make that conclusion, we must assume that these patients were necessarily in a starvation state when they were evaluated. In reality, they may or may not have had a regimen of regular, but small meals as part of their eating disorders. Our patient did not have a long-term history of malnutrition, or eating disorders; she presented with an acute episode of starvation.

We believe our patient's elevated ALP and distended gallbladder could be attributed to her state of starvation. Note that some time after initiation of a regular diet, her ALP level took a down trending course. The subsequent transient rise in ALP might be due to refeeding. Also the gallbladder was initially dilated due to her fasting state and with refeeding the gallbladder was contracted [11].

## CONCLUSION

When a patient presents with elevated ALP activity and a distended gall bladder, the clinician must consider several etiologies in the differential diagnosis. The biggest concern is always the obstructing lesion. Our patient had these abnormalities in the background of a negative clinical work up, including abdominal CT scan. Considering that these findings were isolated in regards to workup and combining the clinical picture, they proved to be transient as our patient was slowly started on a normal diet, we are inclined to conclude that starvation and refeeding have played role in our patient's presentation.

\*\*\*\*\*

## Author Contributions

Sachin Kumar Amruthlal Jain – Involved in substantial contributions to conception and design, acquisition of data, drafting the article, revising it critically for important intellectual content and final approval of the version to be published

Kashyap Patel – Involved in substantial contributions to conception and design, acquisition of data, drafting the article, revising it critically for important intellectual content and final approval of the version to be published

Yousif Ismail – Involved in substantial contributions to conception and design, acquisition of data, drafting the

article, revising it critically for important intellectual content and final approval of the version to be published

Michael Williams – Involved in substantial contributions to conception and design, acquisition of data, drafting the article, revising it critically for important intellectual content and final approval of the version to be published

## Guarantor

The corresponding author is the guarantor of submission.

## Conflict of Interest

Authors declare no conflict of interest.

## Copyright

© Sachin Kumar Amruthlal Jain et al. 2012; This article is distributed under the terms of Creative Commons Attribution 3.0 License which permits unrestricted use, distribution and reproduction in any means provided the original authors and original publisher are properly credited. (Please see [www.ijcasereportsandimages.com/copyright-policy.php](http://www.ijcasereportsandimages.com/copyright-policy.php) for more information.)

## REFERENCES

1. Pagani F, Panteghini M. 5'-Nucleotidase in the detection of increased activity of the liver form of alkaline phosphatase in serum. *Clinical Chemistry* 2001 Nov;47(11):2046–8.
2. McNeil AR, Walker Y, Perera S, Chiang CY, Mitchell D, Lam QT. Changes in Serum ALP and GGT in People Taking the Anticonvulsants Phenytoin, Carbamazepine or Valproate. Poster presented as part of the Australasian Association of Clinical Biochemists' 45th Annual Scientific Conference, Adelaide, South Australia, 16–19 September 2008.
3. Kale VP, Joshi GS, Gohil PB, Jain MR. Effect of fasting duration on clinical pathology results in Wistar rats. *Veterinary Clinical Pathology* 2009 Sep;38(3):361–6. Epub 2009 Mar 30.
4. Costa DP, Ortiz CL. Blood chemistry homeostasis during prolonged fasting in the northern elephant seal. *American Journal of Physiology* 1982 May;242(5):R591–5.
5. Zeng XC, Yang CM, Pan XY, Yao YS, Pan W, Zhou C, Jiang ZR, Chang Y, Ma J. Effects of fasting on hematologic and clinical chemical values in cynomolgus monkeys (*Macaca fascicularis*). *Journal of Medical Primatology* 2011 Feb;40(1):21–6. doi: 10.1111/j.1600-0684.2010.00444.x. Epub 2010 Aug 19.
6. Martins MJ, Hipólito-Reis C, Azevedo I. Effect of fasting on rat duodenal and jejunal microvilli. *Clinical Nutrition* 2001 Aug;20(4):325–1.
7. Farooq N, Priyamvada S, Arivarasu NA, Salim S, Khan F, Yusufi AN. Influence of Ramadan-type fasting on enzymes of carbohydrate metabolism and brush border membrane in small intestine and liver of rat used as a model. *British Journal of Nutrition* 2006 Dec;96(6):1087–94.
8. Racek L, Lenhardt L, Mozes S. Effect of fasting and refeeding on duodenal alkaline phosphatase activity in monosodium glutamate obese rats. *Physiological Research* 2001;50(4):365–72.

9. Lallès JP, David JC. Fasting and refeeding modulate the expression of stress proteins along the gastrointestinal tract of weaned pigs. *Journal of Animal Physiology and Animal Nutrition (Berl)* 2011 Aug;95(4):478–8. doi: 10.1111/j.1439-0396.2010.01075.x. Epub 2010 Nov 22.
10. Swenne I. The significance of routine laboratory analyses in the assessment of teenage girls with eating disorders and weight loss. *Eat Weight Disord* 2004 Dec;9(4):269–78.
11. Khandelwal N, Suri S, Malik M, Katariya S, Das KM, Garg K, Duggal R. Ultrasound in choledocholithiasis. *Journal of the Indian Medical Association* 1991 Apr;89(4):95–7.

CASE REPORT

OPEN ACCESS

# Inguinal dermoid cyst masquerading as irreducible inguinal hernia: A case report

Soumen Das, Utpal De, Dilip Das, Sudip Sarkar

## ABSTRACT

**Introduction:** Dermoid cysts are common developmental anomalies occurring along embryonic fusion lines. Occurrence of this in inguinal region is rare and imposes diagnostic challenge as it masquerades hernia. **Case Report:** A 48-year-old male patient presented with irreducible left inguinal hernia. Exploration of the left inguinal canal revealed a cyst (10x7 cm) in the floor of the inguinal canal separated from the cord structures. The cyst was opened and foul smelling muddy paste like material along with a few hairs came out. Cyst was completely excised. The histopathology was consistent with a dermoid cyst. The patient is doing well at one year follow-up. **Conclusion:** Inguinal dermoid cyst mimicking irreducible hernia is rare but possible entity. If such cyst is encountered during hernia operation, complete excision is to be contemplated.

**Keywords:** Dermoid Cyst, Inguinal Canal, Hernia

\*\*\*\*\*

Das S, De U, Das D, Sarkar S. Inguinal dermoid cyst masquerading as irreducible inguinal hernia: A case report. International Journal of Case Reports and Images 2012;3(11):47–49.

Soumen Das<sup>1</sup>, Utpal De<sup>1</sup>, Dilip Das<sup>1</sup>, Sudip Sarkar<sup>1</sup>  
**Affiliations:** <sup>1</sup>Department of surgery, Ipgmer & sskm hospital, Kolkata, West Bengal, India.  
**Corresponding Author:** Dr. Soumen Das, P-33, R.N. Tagore Road, Kolkata - 700077; Email: drsoumen\_das@yahoo.co.in

Received: 21 November 2011  
Accepted: 13 April 2012  
Published: 01 November 2012

\*\*\*\*\*

doi:10.5348/ijcri-2012-11-221-CR-14

## INTRODUCTION

Dermoid cysts are developmental lesions occurring along the line of embryonic fusion [1]. Common sites include supraorbital region of forehead and midline [1]. Dermoid cyst of anterior abdominal wall is rare. Literature review revealed only five cases of inguinal dermoid till date [1–7]. We report a case with review of literature.

## CASE REPORT

A 48-year-old male patient presented with a swelling in left groin since last 12 years. The swelling was progressive in nature, increased in size on straining, coughing and decreased on lying down. It was associated with occasional pain which subsided on medication.

Physical examination revealed mild pallor with a left sided inguinoscrotal swelling. The swelling extended from mid inguinal region to root of left scrotum. It was pyriform shaped and measured 10 cm in its longitudinal axis. We could not get above the swelling. Cough impulse was present. The swelling was doughy on palpation. It was irreducible. Abdominal and per-rectal examinations were within normal limits. A clinical diagnosis of Irreducible left inguinal hernia was made and an elective inguinal hernioplasty was planned.

Laboratory investigations revealed a hemoglobin- 9 g/dL, WBC count- 11,000/mm<sup>3</sup>, DLC-N<sub>63</sub>L<sub>30</sub>E<sub>7</sub>, 63%, L 30%, E 7%, blood glucose 110 g/dL, urea 20 mg/dL, serum creatinine 0.8 mg/dL. Chest X-ray and ECG were normal.

Exploration of the left inguinal canal revealed a cyst (10x7 cm) in the floor of the inguinal canal separated



from the cord structures. The cyst extended from the deep ring above to upper pole of left testis below. Cord structures were separated from cyst. No direct or indirect sac could be detected. The cyst was opened and foul smelling muddy paste like material along with a few hairs (Figure 1) came out. Cyst was completely excised and sent for histopathology. The postoperative recovery was uneventful and the patient was discharged on 10th post operative day after stitch removal.

Histopathology revealed a thin-walled cystic lining composed of keratinized squamous epithelial cells. Underlying layers contained blood vessels, hair follicles, eccrine and apocrine glands. The above findings were consistent with a dermoid cyst.

The patient is doing well at one year follow-up.

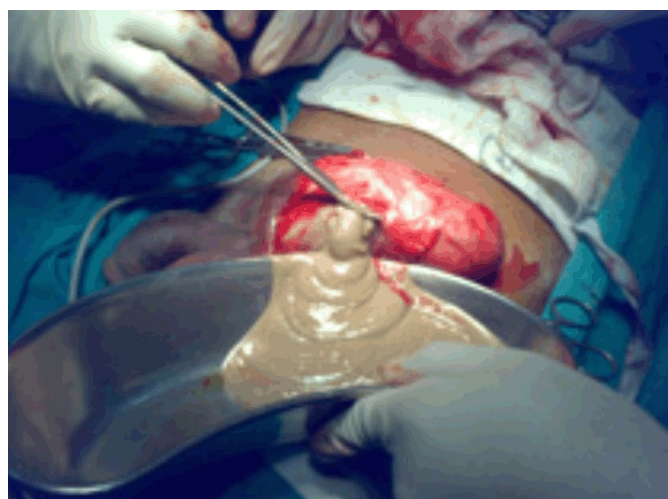

Figure 1: Paste like material coming from the cyst.

## DISCUSSION

Hernia is the commonest inguinal swelling. Other common swellings include undescended testes, lipoma or hydrocele of spermatic cord. Rare inguinal swellings include preperitoneal lipoma, supernumerary pectineus bursa, haemorrhage into internal oblique muscle, round ligament angioma, pedunculated uterine fibromyoma, inguinal endometriosis and thrombophlebitis [5].

Dermoid cyst as a cause of inguinal swelling is rare. A search of English medical databases, using key words dermoid cyst and inguinal mass, revealed five case reports of inguinal dermoid till date (Table 1) [2, 3, 4]. Of the five patients three were female [2, 3] and two male [4]. Four patients were below 30 years [3, 4] of age and the fifth patient was 72 years of age [2]. The duration of the swelling varied from 1 to 4 years. The swellings were provisionally diagnosed as inguinal hernia [2, 4], lipoma [3] and cyst of the round ligament respectively. Dermoid cyst was revealed peroperatively and confirmed histopathologically. A fifth patient had dermo-plastic repair of inguinal hernia and later developed inclusion dermoid [7]. This procedure is obsolete and as such does not need further elaboration.

Dermoid cysts may be teratomatous or non teratomatous benign malformations [3, 4, 5]. Non teratomatous dermoids are common in the inguinal canal. Grossly the excised tumour may be mistaken for a sebaceous cyst or epidermoids. The microscopic presence of skin along with its appendages and sebaceous gland differentiates them from epidermoids and sebaceous cyst which have stratified squamous epithelium surrounded by fibrous tissue forming their wall [2, 3, 4]. The absence of tissues foreign to the part differentiates it from a true dermoid found elsewhere. The contents of the cyst have been reported as tan-colored keratin resulting from accumulation of stratum corneum [4].

Diagnosis is often mistaken clinically as irreducible inguinal hernia. Complications of the cyst which resembles obstructed or incarcerated inguinal hernia include inflammation and hemorrhage [4]. The cyst may sometimes lead to compression of adjacent organs causing retention of urine and bowel obstruction [4]. The possibility of malignant degeneration exists

Table 1: Published case reports of inguinal dermoid

Year	Author	Journal	Age (yrs)	Sex	Provisional diagnosis	Duration of mass
1963	Doctor HG et al. <sup>7</sup>	J Int Coll Surg.	Inclusion dermoid cyst following repair of hernia with full thickness skin graft.			
1971	Brightmore <sup>2</sup>	BJCP	72	F	Strangulated hernia	4 years
1985	Asfraf et al. <sup>*3</sup>	JIMA	20	F	Lipoma	2 years
1992	Leeming et al. <sup>*4</sup>	J Paed Surg	18	M	Incarcerated hernia	1 year
2006	Genetzakis M et al. <sup>1</sup>	Clin Exp Obstet Gynecol	27	F	Cyst of round ligament	4 years
2012 (Present case)	Das et al.	IJCRI	48	M	Irreducible hernia	12 years

especially in women with dermoid cysts arising from round ligament [6]. Tumor markers like alpha fetoprotein and beta chorionic gonadotropin estimation are helpful to monitor treatment and recurrence [6].

Surgical excision is the treatment of choice [1–6].

## CONCLUSION

Inguinal dermoid cyst is rare. If encountered complete excision is to be contemplated in order to avoid complications like—inflammation, hemorrhage and rarely malignant degeneration.

\*\*\*\*\*

## Author Contributions

Soumen Das – Substantial contributions to conception and design, Acquisition of data, Drafting the article, revising it critically for important intellectual content, Final approval of the version to be published

Utpal De – Substantial contributions to conception and design, Acquisition of data, Drafting the article, revising it critically for important intellectual content, Final approval of the version to be published

Dilip Das – Substantial contributions to conception and design, Acquisition of data, Drafting the article, revising it critically for important intellectual content, Final approval of the version to be published

Sudip Sarkar – Substantial contributions to conception and design, Acquisition of data, Drafting the article, revising it critically for important intellectual content, Final approval of the version to be published

## Guarantor

The corresponding author is the guarantor of submission.

## Conflict of Interest

Authors declare no conflict of interest.

## Copyright

© Soumen Das et al. 2012; This article is distributed under the terms of Creative Commons Attribution 3.0 License which permits unrestricted use, distribution and reproduction in any means provided the original authors and original publisher are properly credited. (Please see [www.ijcasereportsandimages.com/copyright-policy.php](http://www.ijcasereportsandimages.com/copyright-policy.php) for more information.)

## REFERENCES

1. Genetzakis M, Lagoudianakis EE, Papadima A, Tsekouras DK, Markogiannakis H, Filis K, Manouras A. Inguinal dermoid cyst of the round ligament. A case report and review of the literature. Clin Exp Obstet Gynecol 2006;33:249–51.
2. Dermoid cyst of the inguinal canal simulating a strangulated inguinal hernia. Brightmore T. Br J Clin Pract 1971;25:191.

3. Dermoid cyst of the inguinal canal. Ashraf SM, Ansari BA, Iqbal N, Ansari A. J Indian Med Assoc 1985;83:125–6.
4. Inguinal dermoid cyst presenting as an incarcerated inguinal hernia. Leeming R, Olsen M, Ponsky JL. J Pediatr Surg 1992;27:117–8.
5. Farrands PA, Taylor I. Unusual groin swellings. Postgrad. Med. J. 1984;60:309–11.
6. Khvorostov ED, Zakharchenko IuB, Tomin MS. Dermoid cyst of inguinal channel: review of the literature and clinical Observation. Klin Khir 2008;3:20–2.
7. Doctor HG, Talwalkar MG, Raichur BS. Inclusion dermoid cyst following repair of hernia with full thickness skin graft. Report of a case and review of the literature. J Int Coll Surg 1963;40:109–6.

CASE REPORT

OPEN ACCESS

# Selenium adjuvant therapy in central nervous system infection

Ladislav Kočan, Janka Vašková, Jozef Firment, Ladislav Vaško

## ABSTRACT

**Introduction:** Bacterial meningitis is associated with permanent after effects resulting from damage to central nervous system structures in affected patients. Massive release of inflammatory mediators and production of reactive oxygen species often complicate the course of the disease and result in the development of sepsis and worsening of the patient's prognosis. **Case Report:** A 38-year-old male patient of Slovak origin with bacterial meningitis and serious sepsis was admitted to an intensive care unit. During a six-day supplementation of selenite pentahydrate at a dose of 750 µg per day, increased activity of the antioxidant enzyme glutathione peroxidase was recorded, the co-factor of which is selenium and synergistically acting enzyme glutathione

reductase, respectively. A concurrent slight decrease in the activity of superoxide dismutase and the reduced levels of inflammatory markers indicated the development of an adequate response of the body to the production of free radicals and their elimination. **Conclusion:** It has been demonstrated that supplementation of critically ill patients with selenium can improve their antioxidant status and may also decrease oxidation damage to neurons and glial cells. Selenium as an adjuvant showed potential efficacy in reducing complications and improving patients' outcomes in the case of lowered antioxidant status during bacterial meningitis, firstly as a pro-oxidant to aid the elimination of microbial pathogens, and secondly as the antioxidant selenoenzymes. The results obtained allowed us to conclude that this can be a suitable complementary intervention in patients with pneumococcal meningitis and developing sepsis.

**Keywords:** Meningitis, Sepsis, Selenium, Selenoenzyme

\*\*\*\*\*

Kočan L, Vašková J, Firment J, Vaško L. Selenium adjuvant therapy in central nervous system infection. *International Journal of Case Reports and Images* 2012;3(11):50–55.

\*\*\*\*\*

doi:10.5348/ijcri-2012-11-222-CR-15

Ladislav Kočan<sup>1</sup>, Janka Vašková<sup>2</sup>, Jozef Firment<sup>3</sup>, Ladislav Vaško<sup>4</sup>

**Affiliations:** <sup>1</sup>Anaesthetist, 1<sup>st</sup> Clinic of Anaesthesiology and Intensive Medicine, Louis Pasteur University Hospital, Košice, Slovak Republic; <sup>2</sup>Research Assistant Professor, Department of Medical and Clinical Biochemistry, Faculty of Medicine, Pavol Jozef Šafárik University in Košice, Košice, Slovak Republic; <sup>3</sup>Head of 1<sup>st</sup> Clinic of Anaesthesiology and Intensive Medicine, Faculty of Medicine, Pavol Jozef Šafárik University in Košice and Louis Pasteur University Hospital, Košice, Slovak Republic; <sup>4</sup>Associate Professor, Department of Medical and Clinical Biochemistry, Faculty of Medicine, Pavol Jozef Šafárik University in Košice, Košice, Slovak Republic.

**Corresponding Author:** Janka Vašková, M.A., Ph.D, Dept. of Medical and Clinical Biochemistry, Faculty of Medicine, Pavol Jozef Šafárik University in Košice, Tr. SNP 1, Košice, Slovak Republic - 040 66; Ph: +421556423849, +421556424239; Fax: +421556423849; Email: janka.vaskova@upjs.sk

Received: 30 December 2011  
Accepted: 05 March 2012  
Published: 01 November 2012

## INTRODUCTION

Even though the range of possible treatments for bacterial meningitis is constantly increasing, the death rate for this disease is still very high (25%) and almost



half of the patients who overcome the disease suffer lifelong neurological consequences. It is a secondary disease which develops after transmission of the pathological agent from another focus of infection (middle ear infections 30%, pulmonary infections 18%, paranasal sinuses infections 2%), and most frequently via the hematogenous route [1]. The groups most at risk are children, immunocompromised patients and elderly people. Meningitis can be associated with subsequent blood borne infective complications such as sepsis, peritonitis and meningitis, which considerably decrease the patient's chances of survival [2].

The respective immune response is significantly affected by the specific anatomic location of the disease. Inflammation is an important component of the pathogenesis of meningitis, particularly in the stage of promotion and evolution of neuron demyelination and degeneration, even in cases where pathogenic micro-organisms have been removed by therapy.

In the case of bacterial meningitis, one has to consider the following cumulative effect of several pathophysiological factors:

1. systemic inflammatory response of the host organism resulting in extravasation of leukocytes to the subarachnoid space, vasculitis, brain oedema and secondary ischemia,
2. stimulation of microglia by bacterial components, and
3. potential direct toxicity of bacterial components on neurons.

The damage to neurons results from the release of reactive oxygen species (ROS), caspases, proteases, cytokines and excitant amino acids after the activation of transcription factors [3]. A significant increase in cerebrospinal fluid (CSF) ROS levels in patients with bacterial meningitis was observed [4]. The central nervous system is particularly vulnerable to the deleterious effects of oxidative stress, due to the high lipid content in the brain, so that an attack on membrane-lipids by ROS initiates a process of lipid peroxidation and subsequent oxidative modification of other cellular components.

Regarding pathogenesis, free radicals also play a key role in development of sepsis, is a serious complication of pneumococcal meningitis [5]. The production of free radicals is in equilibrium with the action of the antioxidant protective system [2, 6]. Superoxide dismutase (SOD) is an enzyme essential for regulating the disproportionation of superoxide radicals to peroxides. Glutathione peroxidase (GPx), of which selenium is a co-factor, acts as non-specific catalyst, facilitating the conversion of peroxides to corresponding alcohols and water, thus preventing the formation of additional ROS produced by the breakdown of peroxides by means of glutathione oxidation.

Original studies on selenium supplementation in the critical care environment are from heterogenous groups of patients and include selenium supplemented in various dosing regimes. The available data demonstrate a potential survival benefit from the supplementation of selenium in general Intensive Care Unit (ICU) patients

[7], mostly pointed out the narrow therapeutic window for selenium supplementation [6]. Randomised trial [8] showed no effect on new infections or on mortality when parenteral nutrition was supplemented with glutamine and/or selenium (500 µg per day). The supplementation of selenium in patients suffering from pneumococcal meningitis and developing sepsis could be considered a reasonable therapeutic intervention since there is evidence of a decrease in serum selenium levels during infections regardless of the infective agent.

The aim of this study was to point, by means of a case report, to potentially beneficial effects of supplemental adjuvant therapy with suitable micronutrients in critically ill patients.

## CASE REPORT

A 38-year-old male patient of Slovak origin with repeating epileptic paroxysms was found unconscious at a railroad station. After arrival of medical emergency rescue team the patient was sedated, intubated, and transferred to the Department of Anesthesiology and Intensive Medicine. A thorough examination resulted in the diagnosis of purulent meningoencephalitis with suspect autogenous origin. For the purpose of ENT specialist intervention, the patient was transferred to the relevant tertiary hospital, the Louis Pasteur University hospital in Košice. The patient required artificial ventilation (AV) and was admitted to the 1st Clinic of anesthesiology and intensive medicine. A sample of CSF was withdrawn for microbiological and biochemical examination (Table 1). The patient was administered intravenously with cefotaxime (3 g every six hours). The cultivation of CSF revealed bacterial infection with *Enterococcus faecalis*, which was confirmed by a blood sample taken from the central venous catheter. On the basis of positive cultures, antimicrobial therapy was initiated. Symptoms of severe sepsis developed during the hours following admission and biochemical inflammatory parameters were elevated. The patient received catecholamine support with norepinephrine ( $0.1 \mu\text{g}\cdot\text{kg}^{-1}$  per minute) to maintain a suitable blood pressure. At the same time, the patient was started on meningitis therapy (cefotaxime 3 g every six hours, meropenem 2 g every 8 hours, vancomycin 2 g per day, antimycotics - fluconazol 20 mg every six hours, antismelling treatment 100 mL of 20% mannitol every six hours) and hydrocortisone supplementation (50 mg every eight hours) to prevent presupposed vascular collapse due to secondary adrenal insufficiency. Subsequently, tympanomastoidectomy was performed on the left ear.

After the operation, a CT scan of the brain was carried out and an intracranial pressure (ICP) monitoring was introduced invasively to monitor manifestations of intracranial hypertension with a shift in midline brain structures. The patient was in analgosedation and the medication was gradually decreased to acceptable ICP values. During hospitalization, alongside adjuvant therapy, the patient

was administered daily sodium selenite pentahydrate (selenium, hereafter) by continuous infusion at a dose of 750 µg per day for six days corresponding to 250 µg selenium per day. Therapeutic advance was approved by Ethics Committee of Faculty of Medicine, Pavol Jozef Šafárik University in Košice. At the same time, alanyl glutamine solution was administered via a central venous catheter at a daily dose of 100 mL (2 g) for six days. During the supplementation, the plasma dynamics of inflammatory cells were monitored (leukocytes, neutrophil/lymphocyte ratio, thrombocytes) as well as the dynamics (Table 1) of biochemical markers (procalcitonin, fibrinogen, CRP, lactate) and antioxidant enzymes, glutathione peroxidase (E.C. 1.11.1.9), glutathione reductase (GR; E.C. 1.6.4.2) (Figure 1) by kit user manuals (SigmaAldrich, Germany) and superoxide dismutase (E.C. 1.15.1.1) (Fluka, Japan) (Figure 2) and the conscious state by means of Glasgow Coma scale (GCS).

Due of the necessity of long-term AV, we performed percutaneous dilatation tracheostomy and subsequently percutaneous endoscopic gastrostomy (PEG) in order to administer enteral nutrition. The objective neurological findings indicated dominance of quadraparesis predominantly in right limbs, right facial nerve paralysis and expressive aphasia. Control CT scan of the head showed inflammatory changes in the left brain hemisphere. Liquid cultures were sterile. The patient was rehabilitated. Complications during the hospital

stay included sepsis and the development of purulent tracheobronchitis. Swabs of the endotracheal cannula confirmed colonisation of *Pseudomonas aeruginosa*. Due to high levels of laboratory markers of inflammation and sepsis, a CT scan of the brain was carried out which ruled out the presence of a brain abscess. The neurosurgeon did not find evidence to perform decompressive craniectomy. Healing of the incision was protracted, and the wound moist so the attending ENT surgeon recommended only a conservative approach. After a two-week treatment and withdrawal of medication, the patient still showed quantitative consciousness disorder, spontaneous opening of the eyes with goal directed fixation, motoric deficit and expressive aphasia. Breathing was spontaneous with pressure support, gaseous exchange in the blood and the acid-base balance (ABB) were satisfactory. Antiepileptic medication was part of the prophylactic treatment. The patient's circulation was stable and did not require catecholamine support. The patient was nourished via PEG, diuresis appeared sufficient, and the artificial ventilation via T-piece was discontinued.

Subsequently, upon the patient's agreement, he was transferred to the relevant ICU in a regional hospital for follow-up treatment. Following improvement, the patient described in the present case report was transferred from the ICU to the relevant neurological unit. At present, this patient is in office-based care of his

Table 1: Selected laboratory parameters from patient's medical history before and during selenium supplementation

	Day before selenium therapy	Day after administration of 1 <sup>st</sup> selenium dose	Day 7 of therapy
Leukocytes ( $10^9 \times L^{-1}$ )	16.9	5.8	9,4
Neutrophils/lymphocytes ( $10^9 \times L^{-1}$ )	12	8	7
Thrombocytes ( $10^9 \times L^{-1}$ )	248	165	182
Fibrinogen ( $g \times L^{-1}$ )	5.46	5.68	1.3
Lactate ( $mmol \times L^{-1}$ )	3.8	2.5	2
CRP ( $mg \times L^{-1}$ )	328	124	75
Procalcitonin ( $\mu g \times L^{-1}$ )	$\geq 10$	-	$\leq 0.5$
GPx ( $\mu kat \times L^{-1}$ )	0.121	-	0.148
GR ( $\mu kat \times L^{-1}$ )	0.424	-	0.565
SOD ( $U \times mL^{-1}$ )	4.500	-	4.063

Abbreviations: CRP C-reactive protein GPx glutathione peroxidase GR glutathione reductase  
SOD superoxide dismutase




Figure 1: Glutathione peroxidases can have different peroxidase activities depending on the selenium status in an organism. Specifically, the activity of GPx, which contains selenium, was measured in reaction with tert-butyl hydroperoxide. The GPx activity measured did not reach a median value equal to that of healthy individuals (1.1  $\mu\text{kat.l}^{-1}$ ); however, plasma glutathione peroxidase is known to be a more easily renewable selenoprotein than other blood components containing GPx. GR activity increased more quickly, mainly indicating high demands on glutathione as well as carbohydrate metabolism remedy.

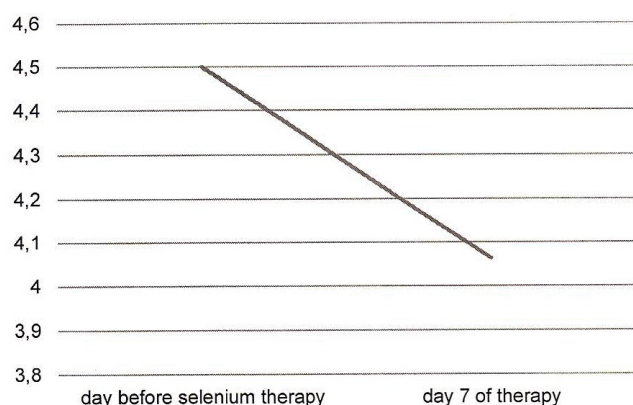


Figure 2: Activity of SOD was established to constitute a relevant parameter in order to evaluate the oxidative stress state of septic patients. An increase in SOD activity indicated an increase in superoxide radical production, leading to lipid peroxidation in addition to the intended goal of microorganism elimination. The initial activity of SOD is higher in comparison to that in healthy people (median 3.1 U.ml<sup>-1</sup> measured in 30 individuals), denoting adequate SOD activity but without further selenoenzyme support. The tendency to decrease after six days of selenium adjuvant therapy indicated lowered superoxide production essentially from two points; namely, by successful antimicrobial therapy and as a result of glutathione peroxidase activity restoration.

local general practitioner and his neurological status is normal without neurological deficit.

## DISCUSSION

Bacterial meningitis is a serious, life-threatening disease requiring rapid diagnosis and immediate treatment. Diagnostics is based clinical symptoms and

predominantly on cytological and biochemical analysis of CSF. Prognosis of acute purulent meningitis depends on the inducing agent, intensity of infection, associated diseases, protective mechanisms and the timeliness of therapeutic intervention. Adjuvant therapy includes antioxidant therapy as protection against free radicals which participate in vasospasms and vasculitis of brain vessels and damage nervous tissue. Free oxygen radicals play an important role in the pathogenesis of the development and progression of this disease [9].

A precondition of the development of purulent meningitis is the colonization of mucous membranes with a pathogenic agent. Bacteremia and subsequent crossing of the hematoencephalic barrier may develop in immunocompromised individuals. The endothelia of cerebral capillaries play a key role in the penetration of bacteria into the CNS [9]. Once bacteria have successfully entered the CSF they start to multiply in the subarachnoid space. Bacteria produce proinflammatory molecules and release active substances by autolysis, which exhibit direct cytotoxic effects. Free oxygen radicals and reactive intermediate nitrogen products are very effective inflammation markers, participating in direct cytotoxic activity and amplification of inflammatory processes. They are produced by granulocytes, microglial cells, endothelium and the bacteria themselves. The cytotoxic effect of radicals is non-selective and, in addition to affecting bacteria, also causes significant damage also to CNS cells. Reactions of free radicals give rise to relatively stable molecules of peroxynitrite. These molecules induce cell death through peroxidation of biomembranes, damage to protein structures, damage to DNS and its excision reparative mechanisms. Selenoproteins such as GPx or thioredoxin reductases as well as methionine sulfoxide reductase are thought to have important antioxidant or redox roles. Selenium is not stored in organisms, so a temporary absence of intake rapidly leads to deficiency. Experimental measurements of selenium levels in critically ill patients with sepsis, SIRS and polytrauma revealed a marked decrease in plasma selenium and significant negative correlation between plasma selenium levels, APACHE II and SAPS II [10]. Intravenous daily intake of 1000  $\mu\text{g}$  sodium selenite pentahydrate was well tolerated by patients in intensive care units [2]. The importance of measuring the selenium dosage became apparent for three reasons: firstly, due to the extreme sensitivity of neural tissue to oxidative injury, leading to intracranial complications and brain damage; secondly, the fact that selenium itself evinces pro-oxidative effect until incorporated into the structure of proteins [11] and finally as global protein synthesis itself is reduced under conditions of stress as a means of serving cellular resources [12].

Increased activity of SOD before selenium administration may result in an increase in the production and accumulation of peroxides and, thus, also to the induction of oxidative stress [13]. With regard to the tendency of decreased SOD activity (9.7%), the levels determined in our study indicated a decrease in the production of superoxide radicals (Table 1, Figure 1).



GPx is an antioxidant enzyme capable of destroying peroxides produced by SOD-mediated dismutation of superoxide anions. Three isoenzymes, cellular GPx, extracellular GPx and phospholipid GPx convert peroxides by supplying electrons from sulfhydryl residues of reduced glutathione. GPx is able to react with both hydrogen peroxide and lipid peroxides. Very low plasma levels of selenium [14] in critically ill patients may therefore be related to low activity of GPx. During the course of selenium therapy we observed that the activity of GPx was increased by 22.3% (Table 1, Figure 1) on day 7 compared to the initial level. Supplementation with selenium, the co-factor of GPx, resulted in increased GPx activity and, thus, also in increased degradation of peroxides, which is indicative of selenium incorporation into proteins and reduced oxidative stress conditions. Assuming the fact that glutathione is required for selenium metabolism, supplementation of glutathione synthesis precursors (alanyl glutamine) could be supportive alone. The key metabolite, hydrogen selenide, is formed from inorganic sodium selenite via selenogluthathione through reduction by thiols and NADPH-dependent reductase [15].

Glutathione reductase continuously recycles the oxidised glutathione back to its reduced form and this regeneration of thiols by means of GR is responsible for uninterrupted degradation of ROS. Decreased activity of GR could be a direct consequence of the overall depletion of antioxidative substances and their co-factor as well as enzyme inhibition by glucose glycation due to acidosis. With regard to the increased activity of GR (33.3%) observed after the initiation of selenium adjuvant therapy and overall improvement of health, we can presume that the body's adequate response to high oxidative stress was supported as confirmed by the observed inflammatory parameters (Table 1).

## CONCLUSION

Combined administration of antibiotics and adjuvant therapy with selenium at a dose of 750 µg per day was carried out for a period of seven days, resulting in an improvement in the patient's condition. The case illustrates the potential usefulness of selenium in clinical usage as an adjuvant and its potential efficacy in reducing complications and improving the outcome for patients in cases of lowered antioxidant status during bacterial meningitis. In this respect, we consider the changes in the activity of SOD against GPx to be interesting parameters for predicting a patient's prognosis. However, further studies are needed to answer the question of the effect of selenium adjuvant therapy against oxidative damage to the CNS and long term outcomes in purulent meningitis.

\*\*\*\*\*

## Acknowledgements

Financial support of the Slovak grant agency for Science VEGA 1/0799/09 was appreciated.

## Abbreviations

ABB	Acid-base balance
APV	Artificial pulmonary ventilation
CRP	C-reactive protein
CSF	Cerebrospinal fluid
CT	Computer tomography
ENT	Ear-nose-throat
ICP	Intracranial pressure
GPx	Glutathione peroxidase
GR	Glutathione reductase
GCS	Glasgow Coma Scale
NADPH	Nicotinamide adenine dinucleotide phosphate, reduced form
PEG	Percutaneous endoscopic gastrostomy
ROS	Reactive oxygen species
SOD	Superoxide dismutase

## Author Contributions

Ladislav Kočan – Substantial contribution to conception and design, Acquisition of data, Drafting the article, Final approval of the version to be published

Janka Vašková – Substantial contribution to conception and design, Analysis and interpretation of data, Drafting the article, Final approval of the version to be published

Jozef Firment – Substantial contribution to conception and design, Revising it critically for important intellectual content, Final approval of the version to be published

Ladislav Vaško – Analysis and interpretation of data, Revising it critically for important intellectual content, Final approval of the version to be published

## Guarantor

The corresponding author is the guarantor of submission.

## Conflict of Interest

Authors declare no conflict of interest.

## Copyright

© Ladislav Kočan et al. 2012; This article is distributed under the terms of Creative Commons Attribution 3.0 License which permits unrestricted use, distribution and reproduction in any means provided the original authors and original publisher are properly credited. (Please see [www.ijcasereportsandimages.com/copyright-policy.php](http://www.ijcasereportsandimages.com/copyright-policy.php) for more information.)

## REFERENCES

1. Ostergaard Ch, Konradsen BH, Samuelsson S. Clinical presentation and prognostic factors of *Streptococcus pneumoniae* meningitis according to the focus of infection. *BMC Infect Dis* 2005;5:93.

2. Geoghegan M, McAuley D, Eaton S, Powell-Tuck J. Selenium in critical illness. *Curr Opin Crit Care* 2006;12(2):136–41.
3. Nau R, Brück W. Neuronal injury in bacterial meningitis: mechanisms and implications for therapy. *Trends Neurosci* 2002;25(1):38c45.
4. Menezes ChC, Dorneles AG, Sperotto RL, et al. Oxidative stress in cerebrospinal fluid of patients with aseptic and bacterial meningitis. *Neurochem Res* 2009;34(7):1255–60.
5. Spapen H, Zhang H, Vincent JL. Potential therapeutic value of lazarets in endotoxemia and other forms of sepsis. *Shock* 1997;8(5):321–7.
6. Heyland D, Dhaliwal R, Suchner U, Berger MM. Antioxidant nutrients: a systematic review of trace elements and vitamins in the critically ill patient. *Intensive Care Med* 2005;31(3):327–7.
7. Strachan S, Wyncoll D. Selenium in critically ill patients. *The Intensive Care Society JICS* 2009;10(1):38–42.
8. Andrews PJ, Avenell A, Noble DW. Randomised trial of glutamine, selenium, or both, to supplement parenteral nutrition for critically ill patients. *BMJ* 2011;342:d1542.
9. Gerber J, Nau R. Mechanisms of injury in bacterial meningitis. *Curr Opin Neurol* 2010;23(3):312–8.
10. Sakr Y, Reinhart K, Bloos F, et al. Time relationship between plasma selenium concentrations, systemic inflammatory response, sepsis, and multiorgan failure. *British J Anaesth* 2007;98(6):775–84.
11. Valenta j, Brodská H, Drabek T, Hendl J, Kazda A. High-dose selenium substitution in sepsis: a prospective randomized clinical trial. *Intensive Care Med* 2011;37(5):808–15.
12. Holcik M, Sonenberg N. Translational control in stress and apoptosis. *Nat Rev Mol Cell Biol* 2005;6(4):318–27.
13. Molina-Heredia FP, Mouvé-Levin C, Berthomieu C, et al. Detoxification of superoxide without production of H<sub>2</sub>O<sub>2</sub>: Antioxidant activity of superoxide reductase complexed with ferrocyanide. *Proc Nat Acad Sci U S A* 2006;103(40):14750–5.
14. Heyland D, Dhaliwal R, Day A, Drover J, Cote H, Wischmeyer P. Optimizing the dose of glutamine dipeptides and antioxidants in critically ill patients: a phase I dose-finding study. *J Parenter Enteral Nutr* 2007;31(2):109–18.
15. Ganther HE. Selenium metabolism, selenoproteins and mechanisms of cancer prevention: complexities with thioredoxin reductase. *Carcinogenesis* 1999;20(9):1657–6.

CLINICAL IMAGES

OPEN ACCESS

# Silicone gel breast implant rupture by magnetic resonance imaging

Amin Ahmed Elzaki, Hamid Osman Hamid,  
Iman Elfatih Badawi Babiker

## CASE REPORT

A 50-year-old female was referred to the X-ray department with a complaints of slowly growing mass in the lower outer quadrant of her left breast and a sudden strong pain with change in the breast size and shape.

Her past medical history reported an augmentation mammoplasty silicone breast implant 15 years ago. Physical examination showed a localized swelling in the lower outer quadrant of the left breast, with a presence of palpable mass given a high significant of breast implant rupture. Rest of physical examination were normal. A non-contrast magnetic resonance imaging (MRI) revealed a left side breast implant rupture (Figure 1).

## DISCUSSION

Breast implants composed of silicone gel enveloped in a silicone rubber elastomer were introduced in 1963. The frequency of rupture of silicone-gel-filled breast prostheses is unknown, as are the associated health

effects [1]. Brown SL et al. reported that on MRI, the prevalence of silicone gel implant rupture in a population-based study of 344 women in Birmingham, Alabama, was 55% and that 22% of ruptured implants showed extracapsular spread of silicon [2]. In 2003, Lisbet et al. reported 33 definite ruptures (10%) and 23 possible ruptures (7%) during a 2-year period. The overall rupture incidence rate for definite ruptures was 5.3 ruptures/100 implants per year [3].

Rupture of silicone breast implants is caused by stress on the implant at the time of surgical placement, trauma, defects in manufacture, long-term repetitive

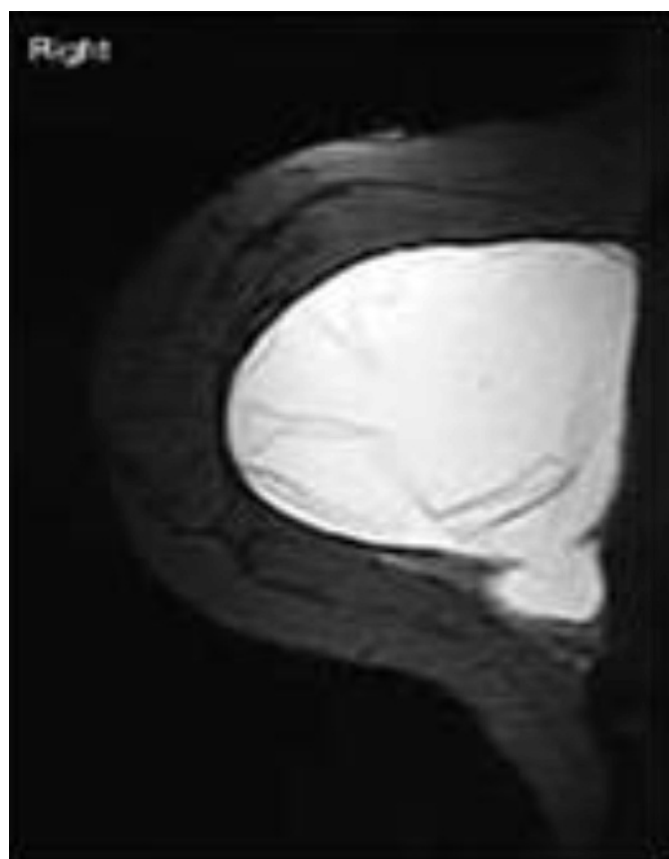


Figure 1: A T2 weighted sagittal MRI image of left breast. Silicone can be seen extruding from the implant inferiorly.

Amin Ahmed Elzaki<sup>1</sup>, Hamid Osman Hamid<sup>2</sup>, Iman Elfatih Badawi Babiker<sup>3</sup>

**Affiliations:** <sup>1</sup>Radiographic Technology & Medical Imaging, Taif University, Head Department, Radiological Science Department, Taif, KSA; <sup>2</sup>Medical Physics, Taif University, Senior Lecturer, Radiological Science Department, College of Medical Applied Science, Taif, KSA; <sup>3</sup>Radiological Science, University of Medical Science & Technology, Radiographic Technologist, Radiological Science, Department, Faculty of Radiological Science, Khartoum, Sudan.

**Corresponding Author:** Amin Ahmed Elzaki, Taif, Mekkah, Kingdom of Saudi Arabia KSA. 21944, P.O. Box 171; Ph: +966 533 82 18 79; Email: Aminzaki2000@yahoo.com

Received: 08 February 2012

Accepted: 27 April 2012

Published: 01 November 2012



stresses such as exercise, mammographic compression, and long-term detention of the implant [4].

The risk of implant rupture increases with implant age. A minimum of 15% of modern implants can be expected to rupture between the third and tenth year after implantation [3].

The diagnosis is difficult to make on the basis of clinical findings on findings on film-screen mammograms. Hence, the value of other imaging techniques such as sonography, computerized tomography (CT) scan, and MRI needs to be studied [4]. The performance of MRI is superior to that of mammography, sonography and CT scan in depicting the rupture [5].

MRI is the most accurate imaging examination for the evaluation of silicone gel breast implant SGBI rupture [6]. High-resolution MRI is needed to depict internal structure of implants accurately. High resolution can best be achieved through use of a dual shoulder coil or a dedicated breast coil. MRI done in a body coil does not provide sufficiently detailed information [1].

## CONCLUSION

Regardless the high costs of MRI scans and possible unavailability, MRI is the best radiological method in detecting breast implant rupture.

\*\*\*\*\*

Elzaki AA, Hamid HO, Babiker IEB. Silicone gel breast implant rupture by magnetic resonance imaging. International Journal of Case Reports and Images 2012;3(11):56–57.

\*\*\*\*\*

doi:10.5348/ijcricri-2012-11-223-CI-16

\*\*\*\*\*

## Author Contributions

Amin Ahmed Elzaki – Substantial contributions to conception and design, Acquisition of data, Analysis and interpretation of data, Drafting the article, Revising it critically for important intellectual content, Final approval of the version to be published

Hamid Osman Hamid – Analysis and interpretation of data, Revising it critically for important intellectual content, Final approval of the version to be published

Iman Elfatih Badawi Babiker – Analysis and interpretation of data, Revising it critically for important intellectual content, Final approval of the version to be published

## Guarantor

The corresponding author is the guarantor of submission.

## Conflict of Interest

Authors declare no conflict of interest.

## Copyright

© Amin Ahmed Elzaki et al. 2012; This article is distributed under the terms of Creative Commons Attribution 3.0 License which permits unrestricted use, distribution and reproduction in any means provided the original authors and original publisher are properly credited. (Please see [www.ijcasereportsandimages.com/copyright-policy.php](http://www.ijcasereportsandimages.com/copyright-policy.php) for more information.)

## REFERENCES

1. S Lori Brown, Barbara G Silverman, Wendie A Berg. Rupture of silicone-gel breast implants: causes, sequel, and diagnosis. *Lancet* 1997;350:1531–7.
2. Brown SL, Middleton MS, Berg WA, Soo MS, Pennello G. Prevalence of rupture of silicone gel breast implants revealed on MR imaging in a population of women in Birmingham, Alabama. *AJR* 2000;175:1057–64.
3. Lisbet R, Ho"lmich, Søren Friis, et al. Incidence of Silicone Breast Implants Rupture. *Arch Surg* 2003;138:801–6.
4. Lenone I Evenson, Helena Parantainen, Tone Detlie, et al. Diagnosis of breast implant rupture: imaging findings and relative efficacies of imaging techniques. *AJR* 1994;163:57–60.
5. Wendie A Berg, Thuy Khanh Nguyen, Michael S Middleton, Mary Scott Soo, Gene Pennello, S. Lori Brown. MR Imaging of Extracapsular Silicone from Breast Implants: Diagnostic Pitfalls 2002; *AJR*;178: 465–72.
6. Middleton MS, McNamara MP Jr. Breast implant classification with MR imaging correlation: CME available on RSNA link. *Radiographics* 2000 May;20(3):E1.

CLINICAL IMAGES

OPEN ACCESS

# Apparent right mid-lung mass in a dyspneic man: The phantom lung tumor

Kavitha B, Balasubramanian R

## CASE REPORT

A 70-year-old male presented with complaints of dyspnoea on exertion of two years duration with recent worsening and additional orthopnoea and paroxysmal nocturnal dyspnoea. There was no history of chest pain, syncope or pedal edema. He had no significant past medical illness like diabetes, hypertension or coronary artery disease. Clinical examination revealed low volume regular pulse with blood pressure of 100/80 mmHg. His JVP (jugular venous pressure) was normal. There was no pedal edema. The cardiovascular system examination revealed aortic stenosis (AS), ejection systolic murmur at the aortic area and early diastolic murmur at the second aortic area (aortic regurgitation/AR). Auscultation over his lungs revealed florid bi-basal crackles. There was no evidence of free fluid or congestive hepatomegaly per abdomen. His electrocardiogram showed sinus tachycardia with low voltage complexes. The Chest X-ray posteroanterior view (Figure 1) showed cardiomegaly, congested lung fields and bilateral minimal pleural effusion. Of note, was a dense rounded opacity in the right midzone. His echocardiogram revealed mild MS (mitral valve size 1.75 cm<sup>2</sup>), moderate AS, mild AR/MR (aortic regurgitation/mitral regurgitation) with ejection fraction of 31%. He was managed with injectable furosemide 80 mg per day and oral digoxin 0.25 mg per day and oral penicillin v 250 mg twice daily. He

improved symptomatically, with the above medications. Chest X-ray repeated after two week's treatment with diuretics and digoxin (Figure 2). It showed decrement of cardiomegaly with good resolution of congestion and pleural effusions. But the most conspicuous finding is the total disappearance of the tumor like shadow visible in Figure 1.

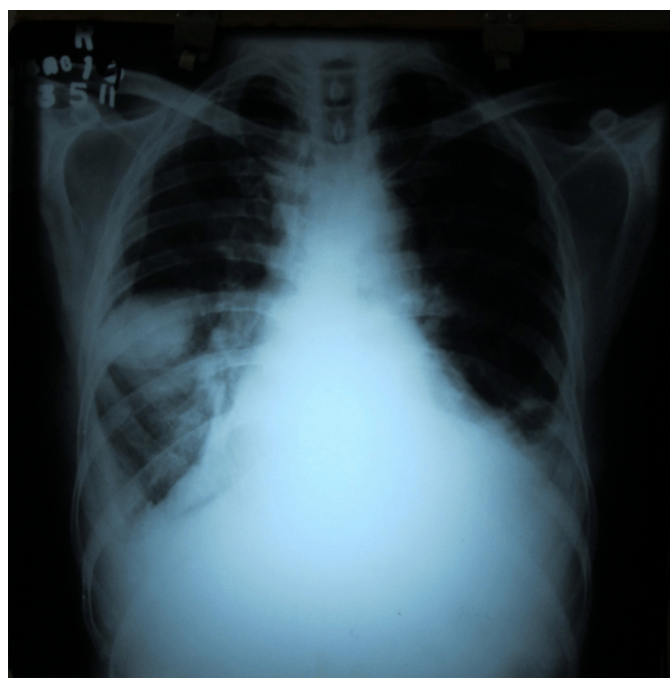


Figure 1: Chest X-Ray posteroanterior view shows cardiomegaly, congested lung fields and bilateral minimal pleural effusion. There is a dense rounded opacity in the right midzone.

Kavitha B<sup>1</sup>, Balasubramanian R<sup>2</sup>

**Affiliations:** <sup>1</sup>Assistant Professor, Department of Internal Medicine, Indiragandhi Medical College and Research Institute, Puducherry, India; <sup>2</sup>Professor & HOD, Department of Internal Medicine, Indiragandhi Medical College And Research Institute, Puducherry, India.

**Corresponding Author:** Kavitha B, House No 5, 4th Cross, Rainbownagar, Puducherry. India, 605011; Ph: +91 9943438870; Email: kavithadr@yahoo.co.in

Received: 07 March 2012

Accepted: 06 May 2012

Published: 01 November 2012

## DISCUSSION

This patient's chest X-ray shows the classical features of what is known as the Phantom Tumor or the Vanishing Lung Tumor [1, 2]. The term 'Phantom Lung Tumor' is applied to a transudative interlobar fluid collection in congestive heart failure, which disappears spontaneously with compensation and may reappear

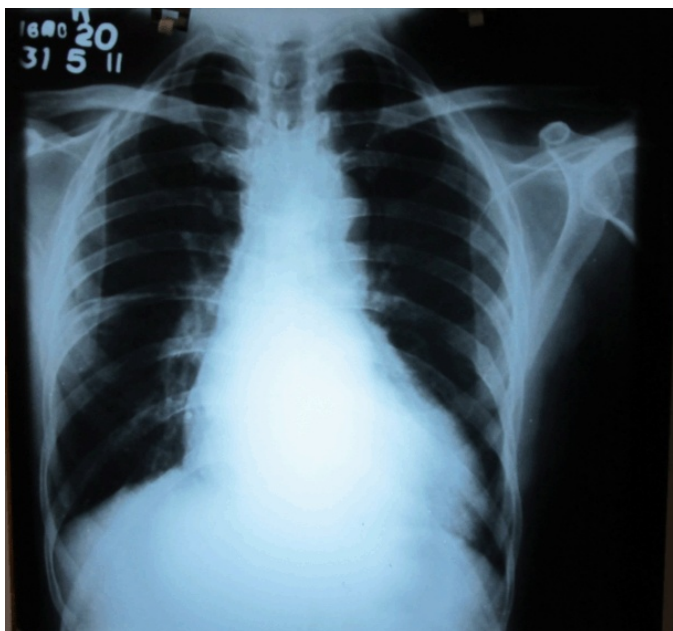

Figure 2: This figure shows decrement of cardiomegaly with good resolution of congestion and pleural effusions and disappearance of the tumor.

with each bout of cardiac decompensation [3, 4]. On a posteroanterior chest film it appears as a dense, well-delineated shadow of variable shape, not infrequently resembling pulmonary tumor. The pseudotumors of the lung [5] are transient collections of pleural fluid in the interlobar pulmonary fissure predominantly on the right, usually seen in congestive heart failure, renal failure or hypoalbuminemia by transudation from the pulmonary vasculature. The interlobar fluid collection occurs most commonly on the right side, in the transverse fissure. Infrequently, it occurs in the transverse and oblique fissures simultaneously. The pathogenesis of this condition is not clear [3, 4]. Several theories have been proposed like: (a) recurrent pleuritis with pleural adhesions due to antecedent infection leading to interlobar localization of the transudate, (b) repeated episodes of heart failure with hydrothorax leading to pleural reaction with subsequent adhesions. The interlobar fissures are the least affected, however, once the general pleural cavity is obliterated, the fluid collects in the interpleural spaces, (c) an interlobar fluid collection remains as the residue of a general pleural effusion. When fluid extends from the general pleural cavity into the interlobar space, it may become encapsulated by deposition of fibrin. Thus in all three hypotheses pleural adhesions are considered the factor responsible for the localization of the transudate.

## CONCLUSION

Hence we conclude that familiarity with this form of pleural effusion is important because it may be the sole manifestation of heart failure. It also avoids unnecessary workup for a pulmonary malignancy. Managing the

underlying condition leads to resolution of the 'pseudotumor'.

\*\*\*\*\*

Kavitha B, Balasubramanian R. Apparent Right Mid-lung Mass In A Dyspneic Man: The Phantom Lung Tumor. International Journal of Case Reports and Images;2012;3(11):58–59.

\*\*\*\*\*

doi:10.5348/ijcri-2012-11-224-CI-17

\*\*\*\*\*

## Author Contributions

Kavitha B – Substantial contributions to the conception and design, acquisition of data, Drafting the article, revising it critically for important intellectual content, Final approval of the version to be published

Balasubramanian R – Substantial contributions to the conception & design, acquisition of data, Drafting the article, revising it critically for important intellectual content, Final approval of the version to be published

## Guarantor

The corresponding author is the guarantor of submission.

## Conflict of Interest

Authors declare no conflict of interest.

## Copyright

© Kavitha B et al. 2012; This article is distributed under the terms of Creative Commons Attribution 3.0 License which permits unrestricted use, distribution and reproduction in any means provided the original authors and original publisher are properly credited. (Please see [www.ijcasereportsandimages.com/copyright-policy.php](http://www.ijcasereportsandimages.com/copyright-policy.php) for more information.)

## REFERENCES

1. Ardic I, Yarlioglu M, Celik A, Kaya MG. Vanishing or Phantom Tumor of the Lung. Texas Heart Inst J 2010;37(6):730–1.
2. Feder BH, Wilk SP. Localized interlobar effusion in heart failure; phantom lung tumor. Dis Chest 1956;30(3):289–7.
3. Ganesh Athappan, Venkatesh K Ariyamuthu, Rajamani VK. Phantom Tumor of the Lung. Internet Journal of Cardiology 2007;5(1).
4. Haus BM, Stark P, Shofer SL, Kuschner WG. Massive pulmonary pseudotumor. Chest 2003;124(2):758–60.
5. Charles E Millard. Vanishing or Phantom Tumor of the Lung; Localized Interlobar Effusion in Congestive Heart Failure. Chest 1971;59(6):675–7.



CLINICAL IMAGES

OPEN ACCESS

# Paraduodenal hernia presenting as acute intestinal obstruction on computed tomography scan

Susannah Margaret Flexer, David Scullion

## CASE REPORT

A 24-year-old male presented with a four-year history of intermittent colicky abdominal pain. These episodes were associated with abdominal distension and constipation and had previously resolved spontaneously. Over the four-year period a series of investigation were performed by his general practitioner, including baseline blood tests, serology for coeliac disease, Esophagogastroduodenoscopy (OGD) and colonoscopy. All investigations were normal. He had undergone an appendectomy for appendicitis.

He presented acutely to hospital with symptoms and signs suggestive of mechanical bowel obstruction. Abdominal X-ray (AXR) and computed tomography (CT) scan were performed and they showed a cluster of abnormally dilated small bowel loops (Figures 1 and 2), with a mass effect on the ascending colon. The configuration of bowel loops seen on imaging suggested a closed loop obstruction secondary to an internal hernia.

The patient proceeded to theatre for a laparotomy, findings at laparotomy were acute small bowel obstruction secondary to a right sided paraduodenal hernia. This was repaired and the patient recovered well.

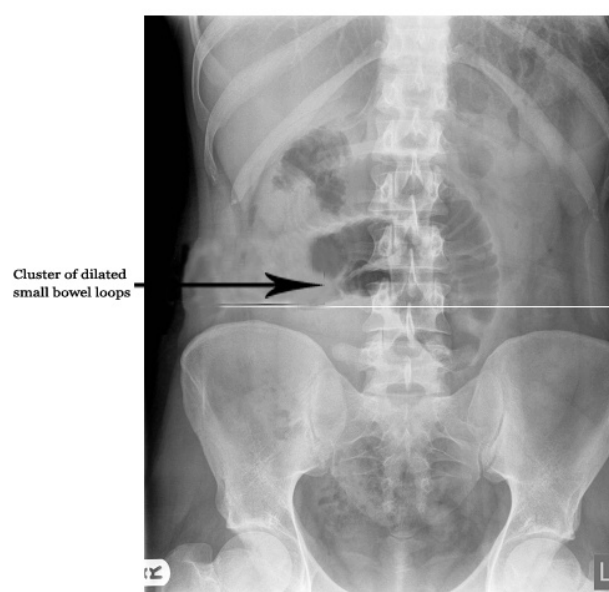


Figure 1: A supine abdominal X-ray demonstrates a mass-like cluster of abnormally dilated small bowel loops in the upper abdomen extending across to the right side of the abdomen and compressing the ascending colon.

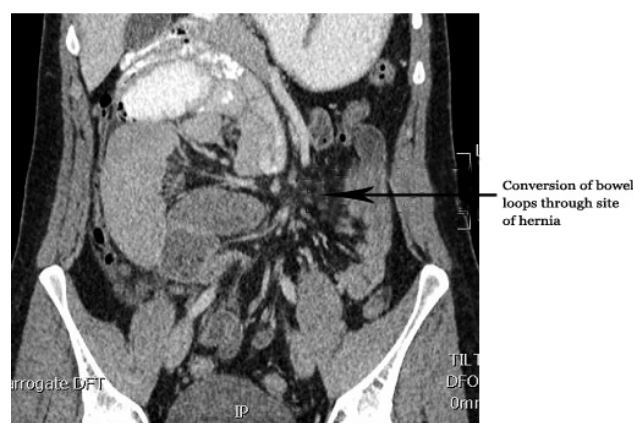


Figure 2: Enhanced abdominal CT scan reconstructed in the coronal plane. This demonstrates the obstructed small bowel loops and better depicts the compressive effect on the ascending colon. The point of conversion of the bowel loops close to the midline approximates to the site of herniation through Waldeyer's fossa.

Susannah Margaret Flexer<sup>1</sup>, David Scullion<sup>2</sup>

Affiliations: <sup>1</sup>Core Surgical Trainee, General Surgery Department, Harrogate District Hospital; <sup>2</sup>Consultant Radiologist, Department of Radiology, Harrogate District Hospital.

Corresponding Author: Miss Susannah Margaret Flexer, MBChB, MRCS, Core Surgical Trainee, General Surgery Department, Harrogate District Hospital, Email: [Susannah.flexer@hdfh.nhs.uk](mailto:Susannah.flexer@hdfh.nhs.uk)

Received: 18 April 2012

Accepted: 23 May 2012

Published: 01 November 2012

## DISCUSSION

Paraduodenal hernias are rare congenital anomaly arising from an error of midgut rotation. They are said to be the most common type of internal hernia. Both right and left paraduodenal hernias occur [1]. Right paraduodenal hernias occurs when bowel herniates through Waldeyer's fossa (a defect in the jejunal mesentery) [2]. Left paraduodenal hernias can be considered truly congenital and occur when bowel prolapses through Landzert fossa, an aperture behind the fourth part of the duodenum.

Signs and symptoms are variable. Intermittent episodes of self-limiting bowel obstruction may be associated with chronically incarcerated hernias. As in this case the patient had intermittent episodes of abdominal pain and distension. Complications of internal hernias include small bowel obstruction, ischemia, infarction and perforation. Differential diagnoses of internal hernias include foreign body impaction, intestinal volvulus, adhesions and tumor [3]. The treatment of a paraduodenal hernia is prompt surgical repair.

## CONCLUSION

Internal hernias are rare and can be a cause of recurrent episodes of abdominal symptoms. Critical review of imaging is needed to diagnose internal hernias. Prompt treatment by surgical repair is required to prevent complications of acute small bowel obstruction and the halt further recurrence of symptomatic episodes.

\*\*\*\*\*

Flexer SM, Scullion D. Paraduodenal hernia presenting as acute intestinal obstruction on computed tomography scan. *International Journal of Case Reports and Images* 2012;3(11):60–61.

\*\*\*\*\*

doi:10.5348/ijcri-2012-11-225-CI-18

\*\*\*\*\*

## Author Contributions

Susannah Flexer – Conception and design, Acquisition of data, Analysis and interpretation of data, Drafting the article, Critical revision of the article, Final approval of the version to be published

David Scullion – Analysis and interpretation of data, Critical revision of the article, Final approval of the version to be published

## Guarantor

The corresponding author is the guarantor of submission.

## Conflict of Interest

Authors declare no conflict of interest.

## Copyright

© Susannah Flexer et al. 2012; This article is distributed under the terms of Creative Commons Attribution 3.0 License which permits unrestricted use, distribution and reproduction in any means provided the original authors and original publisher are properly credited. (Please see [www.ijcasereportsandimages.com/copyright-policy.php](http://www.ijcasereportsandimages.com/copyright-policy.php) for more information.)

## REFERENCES

1. Hansman GH, Morton SA. Intra-abdominal hernias: Report of a Case and Review of the literature. *Archives of Surgery* 1939;39:973–3.
2. Weaver LT. Anatomy and Embryology. In: Walker WA, Goulet O, Kleinman RE, Sherman PM, Shneider BL, Sanderson IR, eds. *Pediatric Gastrointestinal Disease – Pathophysiology - Diagnosis Management*, Philadelphia: BC Decker 1991:195–6.
3. Blachar A, Federle MP, Dodson SF, Internal Hernia: clinical and imaging findings in 17 patients with emphasis on CT criteria. *Radiology* 2001;218(1):68–74.

# Monosomy 18p and hepatosplenomegaly

Kemawikasit Ponchai, Evelyn Erickson, Eduardo A Marrero

## To the Editors,

An 11-month-old infant, previously known to have a chromosome 18p- deletion, came to the clinic for her six months old well child care visit. Palpable hepatosplenomegaly was found and as a result, an abdominal ultrasound and complete blood count (CBC) were ordered. The CBC was normal except for monocytosis of  $1.7 \times 10^3/\text{mm}^3$  (normal-  $0.1-1 \times 10^3/\text{mm}^3$ ). The abdominal ultrasound confirmed hepatosplenomegaly of 9.2 cm found on physical examination. As per her mother, three months prior to her visit, while traveling abroad, the infant had an episode of clear nasal discharge, wet cough, intermittent fever for 3–4 days and watery diarrhea.

The patient was born to a 45-year-old mother, full term at 38 weeks with intrauterine growth restriction and a birth weight of 1970 g. She was born by C-section due to a category 2 tracing. Her mother had chronic hypertension and was on methyldopa. There were no signs of chorioamnionitis. The baby was admitted to the Neonatal Intensive Care Unit for eight days due to low birth weight. The quad screen test showed increased risk of neural tube defects and a fetal amniocentesis reported 46 XX del (18)(p10). Meanwhile, the FISH was that of a

normal female. The geneticist confirmed the results of the amniocentesis, and suggested maternal testing after proper family education and genetics counseling.

The patient's weight ranged from below 5–10% in weight, and the height was below 5%. She was able to sit unsupported but was not able to pivot when sitting, did not crawl well, and did not cruise. She held her bottle and used an immature pincer grasp, did not say 'mama, dada' and did not play gesture games. On the physical examination height was 65 cm (<5%), weight 7.3 kg (<5%) and head circumference 45 cm (75%) (Figure 1). The peripheral oxygen saturation was 95% and her heart rate 155 beats per minute. She was alert, active, well hydrated and not in acute distress. Her eyes, ears, nose and throat appeared normal. She had a short webbed neck. The heart and chest were normal although her right lung had mild wheezing in the lower lung field. Her abdomen was positive for a hepatomegaly and a splenomegaly. No costovertebral angle tenderness was observed.

Among the most important physical findings in patients with monosomy 18p- are ventricular septum defect, patent ductus arteriosus, inguinal hernia,

Kemawikasit Ponchai<sup>1</sup>, Evelyn Erickson<sup>2</sup>, Eduardo A Marrero<sup>3</sup>

**Affiliations:** <sup>1</sup>Pediatric Attending (Preceptor), Department of Pediatrics, Lincoln Hospital and Mental Health Center, Bronx, NY; <sup>2</sup>Pediatric Research Assistant, Department of Pediatrics, Lincoln Hospital and Mental Health Center, Bronx, NY; <sup>3</sup>Pediatric Resident post-graduate level 2, Department of Pediatrics, Lincoln Hospital and Mental Health Center, Bronx, NY.

**Corresponding Author:** Eduardo Antonio Marrero, 91-05, 118th St. Richmond Hill, Queens, NY, USA. 11418; Ph: (718) 704-8629; Fax: (718) 579-4700; Email: doctormarrero@hotmail.com

Received: 28 August 2011

Accepted: 02 November 2011

Published: 01 November 2012

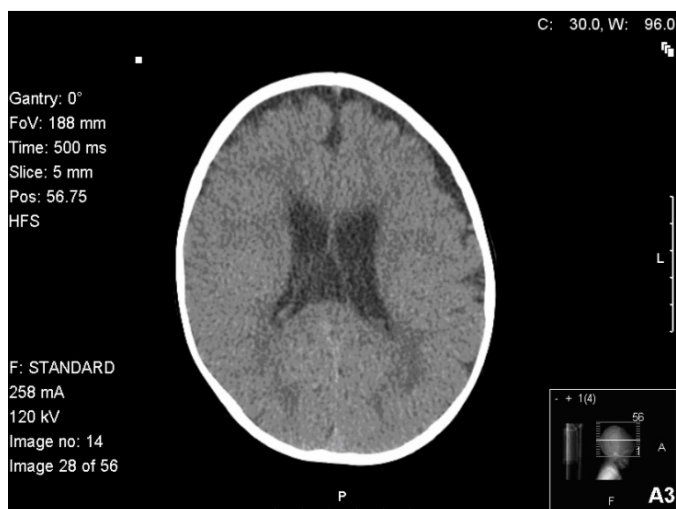


Figure 1: Computed tomography of the brain taken without contrast. Patient had this tomography in order to rule out brain calcifications as well as congenital brain anomalies.



accessory spleen, orthopedic anomalies, pes planus, scoliosis or kyphosis, spina bifida occulta, neurological anomalies (hypotonia, dystonia, holoprosencephaly, agenesis of corpus callosum), strabismus, ptosis, cleft lip/palate, growth hormone deficiency, recurrent otitis media and hearing loss. More than 2/3rd patients have developmental delays, speech delays and/or mild mental retardation [1]. Some can also have psychiatric disturbances such as attention deficit hyperactivity disorder, anxiety, mania, depression and psychosis [2]. Hepatosplenomegaly has not been documented to be associated with monosomy 18p.

Further evaluation was needed to evaluate whether the hepatosplenomegaly found in this patient was linked to monosomy 18p or not. Antibodies for cytomegalovirus (CMV) IgG was found elevated in this patient (Index Value: 4.99, Normal: 0–0.90). A CT of the head (Figure 1) was done which ruled out periventricular calcifications, pituitary abnormalities, mild form of holoprosencephaly with missing corpus callosum, although the patient reported chronic suppurative otitis media of the left ear. An ophthalmology consult was done and found to be within normal limits. In subsequent visits, the liver and the spleen decreased in size. No association between monosomy 18p- and hepatosplenomegaly was found. We concluded that her visceromegaly was related to a past CMV infection. It is still important in patients with monosomy 18p to be closely followed when medical illnesses arise to avoid any medical complications [3].

\*\*\*\*\*

Ponchai K, Erickson E, Marrero EA. Monosomy 18p and hepatosplenomegaly. International Journal of Case Reports and Images 2012;3(11):62–63.

\*\*\*\*\*

doi:10.5348/ijcricri-2012-11-226-LE-19

\*\*\*\*\*

### Author Contributions

Kemawikasit Ponchai – Substantial contributions to conception and design, Acquisition of data, Analysis and interpretation of data, Drafting the article, Revising it critically for important intellectual content, Final approval of the version to be published

Evelyn Erickson – Analysis and interpretation of data, Revising it critically for important intellectual content, Final approval of the version to be published

Eduardo A Marrero – Analysis and interpretation of data, Revising it critically for important intellectual content, Final approval of the version to be published

### Guarantor

The corresponding author is the guarantor of submission.

### Conflict of Interest

Authors declare no conflict of interest.

### Copyright

© Kemawikasit Ponchai et al. 2012; This article is distributed under the terms of Creative Commons Attribution 3.0 License which permits unrestricted use, distribution and reproduction in any means provided the original authors and original publisher are properly credited. (Please see [www.ijcasereportsandimages.com/copyright-policy.php](http://www.ijcasereportsandimages.com/copyright-policy.php) for more information.)

### REFERENCES

1. Turleau C. Monosomy 18p. Orphanet Journal of Rare Diseases 2008;3:4.
2. Zavala J, Ramirez M, Medina R, et al. Psychiatric Syndromes in Individuals With Chromosome 18 Abnormalities. Am J Med Genet B Neuropsychiatr Genet 2010 Apr 5;153B(3):837–45.
3. Schaub RL, Reveles XT, Baillargeon J, Leach RJ, Cody JD. Molecular characterization of 18p deletions: Evidence for a breakpoint cluster. Genet Med 2002 Jan-Feb;4(1):15–9.