EDORIUM Journals

Int J Case Rep Images 2018;9:100932Z01HY2018.
www.ijcasereportsandimages.com

CASE REPORT PEER REVIEWED | OPEN ACCESS

A challenging anesthetic management of acquired tracheo-esophageal fistula operation

Hija Yazıcıoğlu, Bilfer Özler, Büşra Tezcan, Mahmut Subaşı, Erdal Yekeler

ABSTRACT

Tracheo-esophageal fistula (TEF) is a rare but highly morbid complication of tracheal stent. In this case report we presented a challenging anesthetic management of TEF repair. An 18-year-old female patient with epilepsy diagnosis was intubated during epileptic seizure. Tracheomalasia occurred rapidly and stent placement was done inevitably. However TEF developed, rigid bronchoscopy was planned for the removal of the stent. Following premedication induction of anesthesia was done with fentanyl, lidocaine, propofol and rocuronium and maintained with propofol-remifentanil. She was ventilated manually with high flow and high fraction of inspired oxygen (FiO_2). Tracheal resection and primer esophagus repair was considered after failed stent removal attempts. She was intubated with 5.5 no cuffed endotracheal intubation tube (ETT), ventilated with pressure controlled ventilation (PCV) mode. An ETT was placed into the distal trachea when trachea was resected. High flow, 100% O_2 for three minutes was applied manually before apneic periods necessary for the operation. Following esophagus repair before suturing trachea, an aspiration probe was advanced retrogradely from the proximal end of the tracheal incision into the mouth and she was intubated orally via this probe. Depth of anesthesia was assessed with Sedline® (Masimo, USA) monitor. There was no significant hypoxemia, hypercarbia and hemodynamic instability during the whole procedure. Her neck position was extremely flexed during transport and in the ICU. She was extubated on the 12th hour. Anesthesia during TEF repair includes challenges in difficult intubation, sharing airway with the surgical team, troubles during apnea periods, air leakage during ventilation, providing deep anesthesia. Anesthesia management is a challenge but enhances the knowledge and practice of the anesthetist.

Keywords: Airway management, Anesthesia, Tracheo-esophageal fistula

Hija Yazıcıoğlu[1], Bilfer Özler[2], Büşra Tezcan[2], Mahmut Subaşı[3], Erdal Yekeler[4]

Affiliations: [1]Associate Prof. University of Medical Sciences, Turkey Yuksek Ihtisas Hospital, Anesthesiology and Reanimation Clinic, Ankara, Turkey; [2]Specialist, University of Medical Sciences, Turkey Yuksek Ihtisas Hospital, Anesthesiology and Reanimation Clinic, Ankara, Turkey; [3]Specialist Surgeon, University of Medical Sciences Turkey Yuksek Ihtisas Hospital, Thoracic Surgery and Lung Transplantation Department, Ankara, Turkey; [4]Associate Prof. Surgeon, University of Medical Sciences Turkey Yuksek Ihtisas Hospital, Thoracic Surgery and Lung Transplantation Department, Ankara, Turkey.

Corresponding Author: Hija Yazıcıoğlu, Bilkent 2, Park Sitesi, G-4 Blok No: 22/ 32, Bilkent Çankaya 06800, Ankara Turkey; Email: hija001@hotmail.com

Received: 08 May 2018
Accepted: 18 June 2018
Published: 05 July 2018

How to cite this article

Yazıcıoğlu H, Özler B, Tezcan B, Subaşı M, Yekeler E. A challenging anesthetic management of acquired tracheo-Esophageal fistula operation. Int J Case Rep Images 2018;9:100932Z01HY2018.

Article ID: 100932Z01HY2018

****

doi: 10.5348/100932Z01HY2018CR

INTRODUCTION

Tracheo-esophageal fistula (TEF) is a congenital abnormality seen in infants or acquired later in life in adults [1]. Causative factors of aquired TEF, which is a rare condition in adults are malignancy, trauma and iatrogenic factors. Iatrogenic factors include long term endotracheal tube or tracheostomy cannula presence, traumatic intubation, surgical complications [1, 2].

In this case report, we inform an iatrogenic TEF developed following tracheal stent placement which was considered for tracheomalasia caused by endotracheal intubation tube (ETT) cuff. We emphasized the difficult anesthesia management of this TEF repair operation; such as safe intubation, mandatory sharing of the airway with the surgical team during the case, continuous air leakage during ventilation and providing sufficient deep anesthesia.

CASE REPORT

An eighteen year old female patient was on double anti-epileptic drugs for epilepsy treatment, diagnosed two years ago. Although she was on drugs, she had seizures which ended up with endotracheal intubation. In a little while, on the 6th day of intubation tracheomalasia developed and a metallic stent was placed into her trachea. After two months she began to cough out gastric contents following food intake and had coughing bouts. She was transferred to our hospital with a diagnosis of TEF. She was cachectic on examination and had rhonchus on chest auscultation. Her oral food intake was stopped and she was started feeding with liquid nutrients by a nasal gastro-intestinal (GI) tube. CT scan revealed a TEF at the servical 7 vertebrate level. An operation was planned for the removal of the stent with rigid bronchoscopy and surgical repair of the fistula. On the day of the surgery the patient was premedicated with i.v. midazolam, metoclopromide and ondansetron. Anesthesia induction was with i.v. lidocaine 1mg kg^{-1} which helps to attenuate endotracheal intubation reflexes, fentanyl 1µgr kg^{-1}, propofol 3 mg kg^{-1} and rocuronium 0.9 mg kg^{-1} for rapid muscle relaxation. Deep anesthesia was maintained with TIVA including i.v. titrated propofol, remifentanil infusion and muscle relaxation with periodic rocuronium bolus injections. Depth of anesthesia was assessed with Sedline (Masimo)® monitor which works with the principle of analyzing the EEG waveforms. During rigid bronchoscopy the patient was ventilated manually with high flow and high FiO_2. Metalic stent was severely stuck to tracheal mucosa forming a strict adhesion, causing failed attempts for removal by rigid bronchoscopy. Then we made video assisted fiberoptic bronchoscopy (FOB) via ETT and the placement of the stent into the trachea was evaluated by the surgical team. The observation revealed that the stent (Figures 1 and 2) should be surgically removed and the esophagus primarily repaired. She was barely intubated with a cuffed 5.5 no ETT. Apneic periods, which is a must during tracheal resection and stent removal (Figure 2) were managed with manual ventilation with 100 % oxygen for three minutes before apnea. Following stent removal, oropharynx was by-passed and a 6 no cuffed ETT was placed into the distal tracheal lumen (Figure 3). A new sterile ventilator circuits were attached to this ETT and the proximal part of the circuit were passed to the anesthesia machine. Esophageal fistula on the posterior tracheal wall was repaired (Figure 4) while the patient was ventilated with pressure controlled ventilation (PCV). An aspiration probe was advanced retrograde from the proximal end of the tracheal incision into the mouth, by the surgical team before suturing the trachea. Then she was intubated orally with a cuffed 5.5 no ETT via this aspiration probe used as a guide for this intervention. There was no significant hypoxemia, hypercarbia and hemodynamic instability during the whole procedure. Extubation was decided to be done in ICU. Her neck position was extremely flexed during transport and in the ICU in order to avoid laceration of trachea. She was kept in this position as it is essential during the regeneration

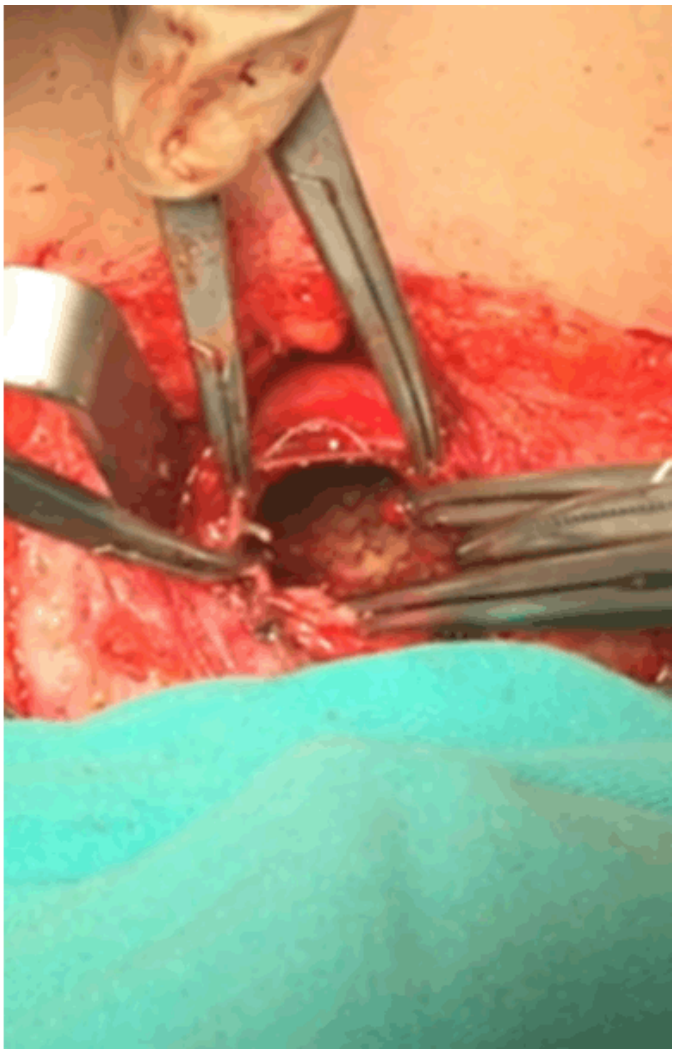

Figure 1: Tracheal resection.

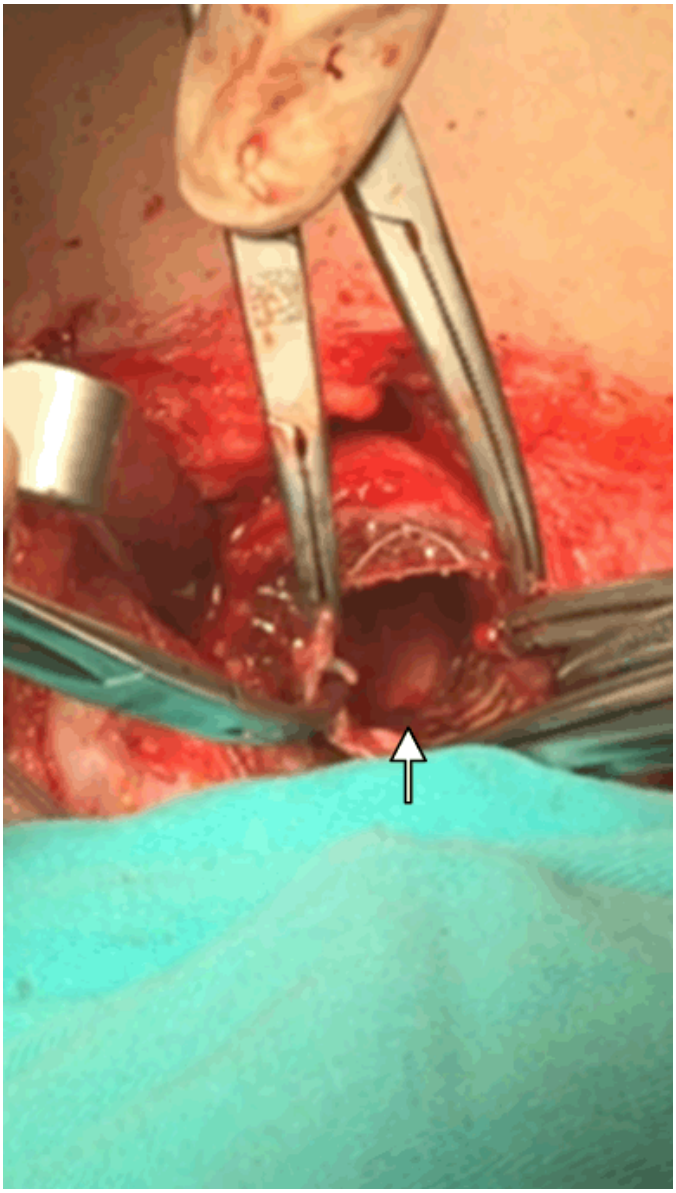

Figure 2: Metallic stent adherent to the tracheal lumen.

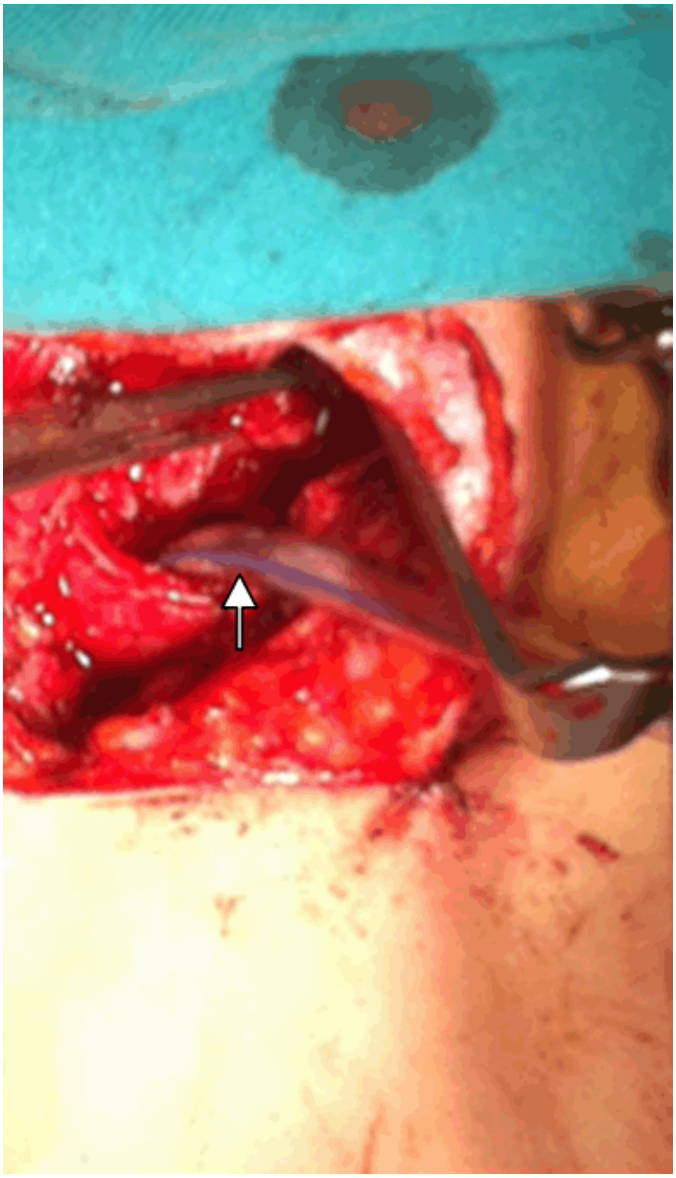

Figure 3: New endotracheal intubation tube in the distal trachea.

of the trachea. She was extubated on postoperative 12th hour in the ICU without any complication.

DISCUSSION

Tracheo-esophageal fistula is rarely seen in adults but has a very high mortality rate due to aspiration of GI contents and pulmonary complications and sepsis related to this complications [1]. Tracheal injury frequently occurs as a consequence of traumatic, long duration intubation; traumatic tracheal aspirations; vascular compression of ETT or tracheostomy tube cuff on the tracheal wall [2]. As a result of ischemia, pressure necrosis and ulceration occurs consequently leading to TEF [2]. In this case, preference of metallic stent instead of silicone one probably precipitates TEF occurrence. Premedication should also include glycopyrolate for blunting oropharengial secretions, however this drug is not available in our country. Anesthetic management during TEF repair includes challenges in difficult intubation, sharing airway with the surgical team, possible troubles during apnea periods, large amount of leakage during ventilation and providing deep anesthesia etc. We did not face any serious problems during the procedure as the anesthesia team was experienced, ventilation strategies was appropriate, FOB usage was effective, cooperation with the surgical team was good and depth anesthesia was sufficient enough. This approach provides better blood oxygen saturation, hypercarbia elimination and hemodynamic stabilization. We preferred TIVA instead of inhalation agents which is suggested to be used in some cases [2, 3], because the

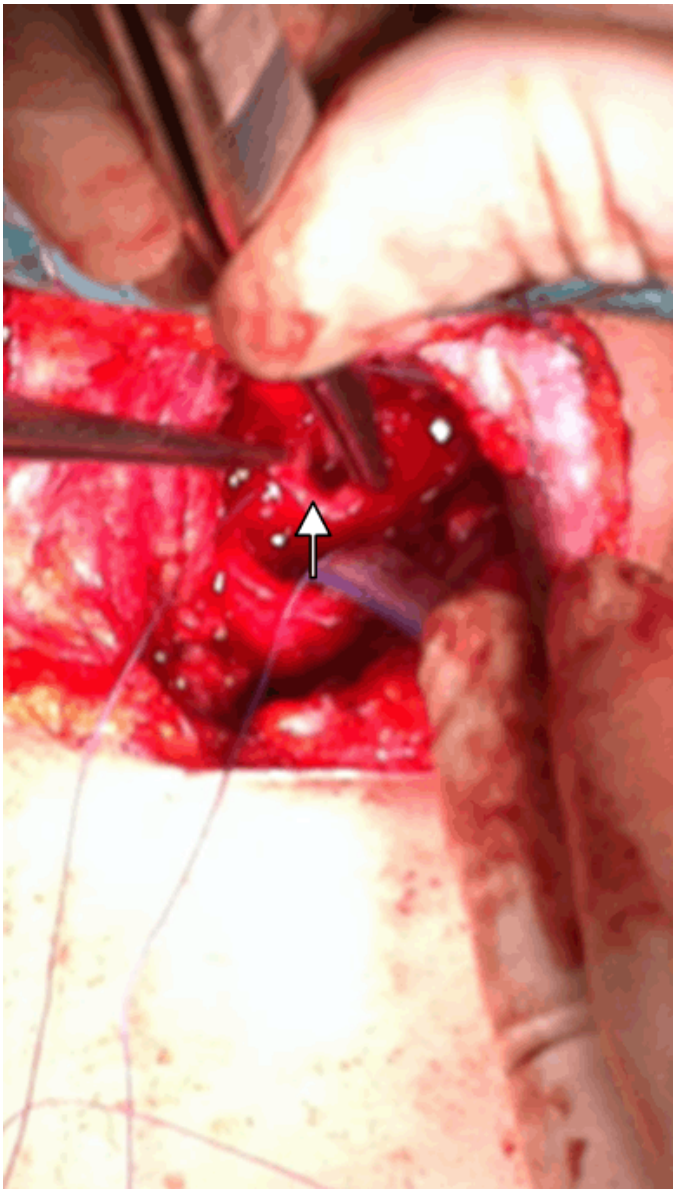

Figure 4: Tracheo-esophageal fistula localized in the posterior tracheal wall.

anesthesia depth during the apnea periods and the whole procedure should be strictly maintained. Thus we have no difficulty during cessation of inhalational ventilation such as during rigid bronchoscopy, FOB or apnea periods. We also managed this challenges with the help of EEG monitorization [4]. In this case probably lack of evaluation and monitoring of ETT cuff pressure was underemphasized at the referred hospital and tracheomalasia developed rapidly. A tracheal stent was implanted inevitably but as a result of ischemia, pressure necrosis and ulceration, TEF occurred within two months [3]. Preference of metallic stent instead of silicone one could also precipitate TEF occurrence [4].

She was premedicated with anti-vomiting and anti-acid drugs in order to take precaution in case of aspiration. On the other hand glycopyrolate should also be used for blunting oropharyngeal secretions, however this drug is not available in our country [5]. Anesthesia induction was conventional but rapid and potent dose of neuromuscular blocking agent was utilized as there was no tolerance to the patient`s movement at the very beginning during bronchoscopy and during the whole procedure.

Anesthetic management during TEF repair includes challenges in difficult intubation, sharing airway with the surgical team, possible troubles during apnea periods, large amount of leakage during ventilation and providing deep anesthesia [6–9].

We overcome the difficult intubation caused by the stenosis, by using pediatric ETT. The tube cuff already occluded the trachea, distal to the TEF at the cervical 7 vertebrate level; high above the carina so that the gastric dilatation and aspiration risk did not intimidate us.

Efficient FOB usage determined the exact level of tracheal resection for stent removal; identify TEF location and helped ETT suctioning at certain intervals [6, 7].

Intermittent apneic periods especially during TEF repair were managed with high flow high FiO2 insufflation for 3 minutes in advance. This approach provides better blood oxygen saturation, hypercarbia elimination and hemodynamic stabilization. Air flow was through such a narrow 5.5 no ETT that PCV was necessary for preventing barotrauma to the lungs. Before suturing the trachea after TEF repair, endotracheal re-intubation was performed retrogradely via an aspiration probe advanced from proximal end of the tracheal incision into the mouth. This approach kept us away from possible hazards about ensuring secure airway. Such as facing “can not intubate, can not ventilate” scenarios, blood aspiration from the surgical field, etc. Extremely good quality of communication with the surgeon is the key point while sharing the airway during the whole procedure.

Anesthesia depth should be strictly maintained and no patient movement should be warranted during the whole procedure. In order to achieve this goal we preferred TIVA on contrary to inhalation agents which was suggested in some similar case reports [3, 9, 10]. Thus we did not experience any difficulty while cessation of inhalational ventilation such as during rigid bronchoscopy, FOB or apnea periods. Patient state index which is a processed EEG monitor, a clinically validated anesthesia and sedation measurement device was very helpful to deal with this challenge [11].

We did not face any serious problems during the procedure as the anesthesia team was experienced, ventilation strategies was appropriate, FOB usage was effective, cooperation with the surgical team was good and depth of anesthesia was sufficient enough.

CONCLUSION

Anesthesia management of TEF operation is a challenge but helps to enhance the knowledge and practice of the anesthetist.

REFERENCES

1. Didee R, Shaw IH. Acquired tracheaesophageal fistula in adults continuing education in anaesthesia. Critical Care and Pain 2006;6(3):105–8.
2. Kastanos N, Estopá Miró R, Marín Perez A, Xaubet Mir A, Agustí-Vidal A. Laryngotracheal injury due to endotracheal intubation: Incidence, evolution, and predisposing factors. A prospective long-term study. Crit Care Med 1983 May;11(5):362–7.
3. Kaur D, Anand S, Sharma P, Kumar A. Early presentation of postintubation tracheoesophageal fistula: Perioperative anesthetic management. J Anaesthesiol Clin Pharmacol 2012 Jan;28(1):114–6.
4. Chin CS, Litle V, Yun J, Weiser T, Swanson SJ. Airway stents. Ann Thorac Surg 2008 Feb;85(2):S792–6.
5. Butterworth JF, Mackey DC, Wasnick JF. Cholinesterase inhibitors & other pharmacologic antagonists to neuromuscular blocking agents. In: Butterworth JF, Mackey DC, Morgan GE, Mikhail MS, editors. Morgan & Mikhail's Clinical Anesthesiology. 5ed. New York: McGraw-Hill Education; 2013. p. 236.
6. Gayle JA, Gómez SL, Baluch A, Fox C, Lock S, Kaye AD. Anesthetic considerations for the neonate with tracheoesophageal fistula. Middle East J Anaesthesiol 2008 Oct;19(6):1241–54.
7. Knottenbelt G, Costi D, Stephens P, Beringer R, Davidson A. An audit of anesthetic management and complications of tracheo-esophageal fistula and esophageal atresia repair. Paediatr Anaesth 2012 Mar;22(3):268–74.
8. Ni Y, Yao Y, Liang P. Simple strategy of anesthesia for the neonate with tracheoesophageal fistula: A case report. Int J Clin Exp Med 2014 Jan 15;7(1):327–8.
9. Joshi S, Kulkarni A, Holkunde RS. A rare case of adult acquired tracheo-oesophageal fistula with sub-glottic stenosis for corrective surgery- an anesthetic challenge. J Clin Diagn Res 2014 Nov;8(11):GD01–3.
10. Montes FR, Trillos JE, Rincón IE, et al. Comparison of total intravenous anesthesia and sevoflurane-fentanyl anesthesia for outpatient otorhinolaryngeal surgery. J Clin Anesth 2002 Aug;14(5):324–8.
11. Drover D, Ortega HR. Patient state index. Best Pract Res Clin Anaesthesiol 2006 Mar;20(1):121–8.

****

Author Contributions

Hija Yazıcıoğlu – Substantial contributions to conception and design, Acquisition of data, Analysis and interpretation of data, Drafting the article, Revising it critically for important intellectual content, Final approval of the version to be published
Bilfer Özler – Substantial contributions to conception and design, Acquisition of data, Analysis and interpretation of data, Revising it critically for important intellectual content, Final approval of the version to be published
Büşra Tezcan – Substantial contributions to conception and design, Drafting the article, Revising it critically for important intellectual content, Final approval of the version to be published
Mahmut Subaşı – Substantial contributions to conception and design, Acquisition of data, Analysis and interpretation of data, Revising it critically for important intellectual content, Final approval of the version to be published
Erdal Yekeler – Substantial contributions to conception and design, Acquisition of data, Analysis and interpretation of data, Revising it critically for important intellectual content, Final approval of the version to be published

Guarantor of Submission

The corresponding author is the guarantor of submission.

Source of Support

None

Consent Statement

Written informed consent was obtained from the patient for publication of this case report.

Conflict of Interest

Authors declare no conflict of interest.

Copyright

© 2018 Hija Yazıcıoğlu et al. This article is distributed under the terms of Creative Commons Attribution License which permits unrestricted use, distribution and reproduction in any medium provided the original author(s) and original publisher are properly credited. Please see the copyright policy on the journal website for more information.

Access full text article on other devices

Access PDF of article on other devices