EDORIUM Journals
www.edoriumjournals.com

CASE REPORT PEER REVIEWED | OPEN ACCESS

Synchronous carcinoma breast with renal cell carcinoma: A case report

Tej Prakash Soni, Sajal Goel, Lalit Mohan Sharma, Anil Kumar Gupta, Shantanu Sharma, Ravindra Gothwal

ABSTRACT

Incidence of double malignancy (synchronous or metachronous) has increased significantly. Renal cell cancer or Breast Cancer as second primaries are reported in the literature, but synchronous carcinoma breast with renal cell carcinoma is extremely rare. We are reporting a case of carcinoma breast with synchronous renal cell carcinoma. Case Report: A 38-year-old female was investigated for a lump in right breast. Biopsy from breast lump was reported as infiltrating duct carcinoma. Metastatic workup revealed a large mass at lower pole of right kidney. Right MRM and right radical nephrectomy were done for synchronous carcinoma breast and renal cell carcinoma. Conclusion: Genetic predisposition, tobacco, HPV, improvement in survival and long term surveillance after first primary cancer treatment, history of radiation or chemotherapy can be associated with second cancer but exact cause of second cancer is still unknown. Larger studies and research is warranted as the risk of double malignancy has been increased substantially. The plausible mechanisms behind the synchronous cancers have to be investigated.

All Articles Open Access

International Journal of Case Reports and Images (IJCRI)

International Journal of Case Reports and Images (IJCRI) is an international, peer reviewed, monthly, open access, online journal, publishing high-quality, articles in all areas of basic medical sciences and clinical specialties.

Aim of IJCRI is to encourage the publication of new information by providing a platform for reporting of unique, unusual and rare cases which enhance understanding of disease process, its diagnosis, management and clinico-pathologic correlations.

IJCRI publishes Review Articles, Case Series, Case Reports, Case in Images, Clinical Images and Letters to Editor.

Website: www.ijcasereportsandimages.com

(This page in not part of the published article.)

CASE REPORT PEER REVIEWED | OPEN ACCESS

Synchronous carcinoma breast with renal cell carcinoma: A case report

Tej Prakash Soni, Sajal Goel, Lalit Mohan Sharma, Anil Kumar Gupta, Shantanu Sharma, Ravindra Gothwal

ABSTRACT

Introduction: Incidence of double malignancy (synchronous or metachronous) has increased significantly. Renal cell cancer or Breast Cancer as second primaries are reported in the literature, but synchronous carcinoma breast with renal cell carcinoma is extremely rare. We are reporting a case of carcinoma breast with synchronous renal cell carcinoma. Case Report: A 38-year-old female was investigated for a lump in right breast. Biopsy from breast lump was reported as infiltrating duct carcinoma. Metastatic workup revealed a large mass at lower pole of right kidney. Right MRM and right radical nephrectomy were done for synchronous carcinoma breast and renal cell carcinoma. Conclusion: Genetic predisposition, tobacco, HPV, improvement in survival and long term surveillance after first primary cancer treatment, history of radiation or chemotherapy can be associated with second cancer but exact cause of second cancer is still unknown. Larger studies and research is warranted as the risk of double malignancy has been increased substantially. The plausible mechanisms behind the synchronous cancers have to be investigated.

Keywords: Carcinoma breast, Rare, Renal cell carcinoma, Synchronous

Tej Prakash Soni[1], Sajal Goel[2], Lalit Mohan Sharma[3], Anil Kumar Gupta[4], Shantanu Sharma[5], Ravindra Gothwal[6]

Affiliations: [1]MD, Consultant, Dept. of Radiation Oncology, Bhagwan Mahaveer Cancer Hospital & Research Centre, Jaipur, Rajasthan, India; [2]DNB, Senior Resident, Dept. of Radiation Oncology, Bhagwan Mahaveer Cancer Hospital & Research Centre, Jaipur, Rajasthan, India; [3]MD, (Sr. Consultant, Dept. of Medical Oncology, Bhagwan Mahaveer Cancer Hospital & Research Centre, Jaipur, Rajasthan, India; [4]MS, Sr. Consultant, Dept. of Surgical Oncology, Bhagwan Mahaveer Cancer Hospital & Research Centre, Jaipur, Rajasthan, India; [5]MD, Associate Professor, Dept. of Radiotherapy, S.M.S. Medical College & Hospital, Jaipur, Rajasthan, India; [6]MD, Associate Professor, Dept. of Radiotherapy, S.M.S. Medical College & Hospital, Jaipur, Rajasthan, India.

Corresponding Author: Tej Prakash Soni, Dr. Tej Prakash Soni, Consultant, Dept. of Radiation Oncology, Bhagwan Mahaveer Cancer Hospital & Research Centre, JLN Road, Jaipur, Rajasthan, India, Pincode 302017, Email: drtejprakashsoni@yahoo.co.in

Received: 05 June 2016
Accepted: 27 July 2016
Published: 01 November 2016

How to cite this article

Soni TP, Goel S, Sharma LM, Gupta AK, Sharma S, Gothwal R. Synchronous carcinoma breast with renal cell carcinoma: A case report. Int J Case Rep Images 2016;7(11):720–723.

Article ID: Z01201611CR10713TS

****

doi:10.5348/ijcri-2016125-CR-10713

INTRODUCTION

With to availability of effective cancer therapy and improvement in survival, the incidence of double malignancy has risen [1]. Double malignancy now comprises of the sixth most common cancers and it makes 16% of all incident cancers [2]. Renal cancer is known to be associated with multiple tumors involving bladder, prostate, rectum, lung, non-Hodgkin's lymphoma,

stomach and melanoma etc. [3]. Breast cancer is also associated with increased risk of second tumor involving colon, vulva, lung, larynx, liver, uterus and thyroid [4]. All these associations can be metachronous (develop consequently) or synchronous (tumors coexist at the time of diagnosis). Synchronous breast and renal cell carcinoma (RCC) can occur rarely [3]. We hereby report a case of carcinoma breast with synchronous renal cell carcinoma.

CASE REPORT

A 38-year-old premenopausal, multipara female with no significant family history presented with a lump in right breast since eight months duration. Sonomammography of ipsilateral breast showed a fibroadenoma of 23x18 mm at 9 o'clock position, surrounding fibroadenosis and reactive axillary lymph nodes. Excision Biopsy was done by a surgeon at a peripheral hospital and it was reported as pT 4.5x3 cm, infiltrating duct carcinoma with predominant ductal carcinoma in situ (cribriform pattern).

The patient was referred to our hospital for further management. Computed tomography scan of abdomen for metastatic workup showed a 45x42 mm mass in mid-lower pole of right kidney with small exophytic component and associated perilesional fat density suspected to be malignant (Figure 1). Bone Scan, CT chest and other routine investigations were within normal limits. Right modified radical mastectomy and right radical nephrectomy were done. Histopathology of breast specimen was reported as lumpectomy cavity of size 6x3.5x3 cm, no residual primary tumor, 4/26 lymph nodes positive for metastatic duct carcinoma (Figure 2), immunohistochemistry profile of axillary lymph node showed positivity for GCDFP and negativity for ER/ PR/ Her 2 neu/ CD 10/ PAX 8 and Vimentin. Gross size of the right kidney specimen was 12.5x7x3 cm with ureter 4 cm in length.

On cutting a well circumscribed tumor identified in middle region of kidney measuring 4.5x3.2x3 cm, with variegated cut surface, and Gerota's fascia adherent to the tumor at one focus measuring 3x1.2 cm. Histopathology of renal mass was reported a well-circumscribed tumor, grade I, clear cell renal cell carcinoma, Gerota's fascia uninvolved, vascular and ureteric cut end unremarkable, renal sinus and perinephric fat free of tumor (Figure 3).

Immunohistochemistry of renal mass was positive for CD 10, PAX8, Vimentin and negative for GCFDP. She was finally diagnosed as a case of synchronous carcinoma right breast (pT2pN2cM0) along with conventional renal cell carcinoma right kidney (pT1bpN0cM0, Grade I). She received adjuvant chemotherapy (FEC x 4 followed by Taxol x 4 cycles). She further received external beam radiotherapy to ipsilateral chest wall and SCF.

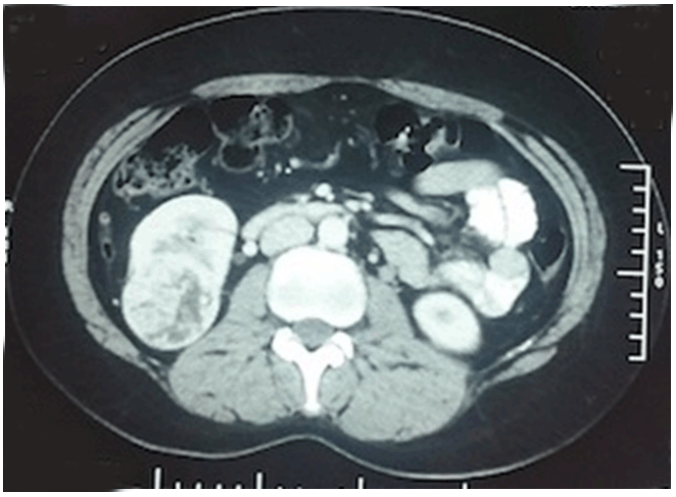

Figure 1: Computed tomography scan of abdomen showing a mass in mid-lower pole of right kidney with small exophytic component and associated perilesional fat density.

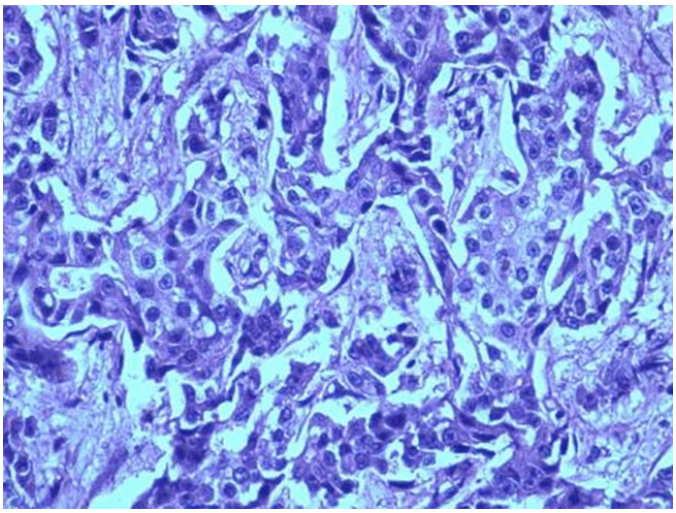

Figures 2: Malignant ductal cells diagnostic of Infiltrating duct carcinoma (H&E stain, x400).

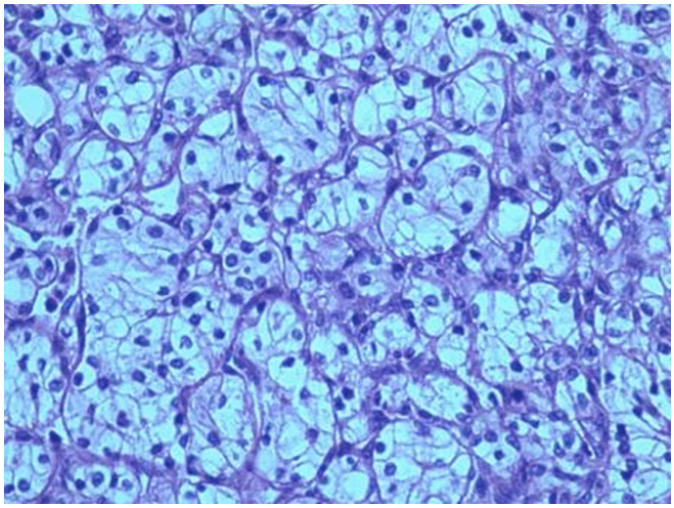

Figure 3: Slide showing clear cells diagnostic of clear cell renal cell carcinoma (H&E stain, x400).

DISCUSSION

Renal cell carcinoma and breast cancer are associated with increased risk of double malignancy [3, 4]. Sato et al. [3] found multiple primary malignant tumors in up to 12% of patients with renal cell cancer. Rabbani et al. [5] also reported 30–40% incidence of other primary malignancies on autopsy series in patients with renal cell carcinoma. Synchronous breast and renal carcinomas are rarely reported [3].

The exact mechanism of double malignancy is not well understood. The predisposing risk factors for dual malignancy include tobacco and alcohol, genetic predisposition (Li Fraumeni and Beckwith–Wiedemann syndrome, Cowden syndrome and BRCA mutations), improved survival, history of prior radiation or chemotherapy, environmental risk factors, old age [1]. PTEN gene is associated with Cowden syndrome which has high risk of developing tumors of the thyroid, breast, kidney, endometrium [6].

Detection bias may be another important factor as metastatic workup or long-term surveillance for first malignancy increases chances of detection of second primary tumor.

Hormone-ER complex may be playing a role in development of RCC. Di Silvero et al. [7] reported a series of 17 cases of renal cell carcinoma associated with primary tumors of steroid hormone target tissue such as breast, ovary and endometrium. Liu et al. [8] in a study of differentially expressed genes (DEGs), reported that ER target genes were closely associated with renal cell carcinoma development. Tanaka et al. [9] investigated that exposing the Syrian hamsters to estrogens results in the development of kidney cancer and aneuploidy in renal cells. Henriksson et al. [10] found no difference in survival for metastatic renal cell carcinoma patients treated with immunotherapy (interleukin 2/interferon alpha) and tamoxifen arm versus tamoxifen alone arm in a multicentric randomized controlled trial. These results suggest that the role of endocrine manipulation for renal cell cancer needs to be investigated more. Epidemiological studies of survivors of atomic bomb irradiation links the radiation as potential carcinogenic but the proportion of second cancers that attributes to radiotherapy is still unknown. Radiotherapy techniques have changed significantly in last two decades. These rapidly evolving techniques (intensity modulated radiotherapy (IMRT), volumetric arc therapy (VMAT) tomotherapy, cyberknife, stereotactic radiotherapy, proton therapy) have different acute and late toxicity profiles compare to conventional radiotherapy. IMRT delivers more conformal radiation doses to the target tumor volume but it involves more number of radiation fields and exposes a larger volume of normal tissue to lower doses. IMRT and its implication as increased second cancer incidence is a matter of debate.

Methodological research is required on association of dual malignancy with late side-effects of chemotherapy/radiotherapy, genetic modifiers, environmental risk factors.

CONCLUSION

As the survival of cancer patients has improved due to early detection and availability of advance treatment options, the risk of second cancer or double malignancy has also increased significantly. Long-term surveillance and high index of suspicion of double malignancy by treating physician and reviewing pathologist is warranted for early detection of second tumor. Further research is required to quantify the association between second malignancy and genetic, environment al and treatment related factors like IMRT and newer chemotherapy.

****

Author Contributions

Soni Tej Prakash – Substantial contributions to conception and design, Acquisition of data, Analysis and interpretation of data, Drafting the article, Revising it critically for important intellectual content, Final approval of the version to be published

Goel Sajal – Acquisition of data, Revising it critically for important intellectual content, Final approval of the version to be published

Sharma Lalit Mohan – Acquisition of data, Revising it critically for important intellectual content, Final approval of the version to be published

Gupta Anil Kumar – Acquisition of data, Revising it critically for important intellectual content, Final approval of the version to be published

Sharma Shantanu – Acquisition of data, Revising it critically for important intellectual content, Final approval of the version to be published

Gothwal Ravindra – Acquisition of data, Revising it critically for important intellectual content, Final approval of the version to be published

Guarantor

The corresponding author is the guarantor of submission.

Conflict of Interest

Authors declare no conflict of interest.

Copyright

© 2016 Soni Tej Prakash et al. This article is distributed under the terms of Creative Commons Attribution License which permits unrestricted use, distribution and reproduction in any medium provided the original author(s) and original publisher are properly credited. Please see the copyright policy on the journal website for more information.

REFERENCES

1. Travis LB, Rabkin CS, Brown LM, et al. Cancer survivorship–genetic susceptibility and second primary cancers: Research strategies and recommendations. J Natl Cancer Inst 2006 Jan 4;98(1):15-25.
2. Ries LAG, Harkins D, Krapcho M, et al. SEER Cancer Statistics Review, 1975-2003, National Cancer Institute. Bethesda, MD. [Available at: http://seer.cancer.gov/csr/1975_2003/]
3. Sato S, Shinohara N, Suzuki S, Harabayashi T, Koyanagi T. Multiple primary malignancies in Japanese patients with renal cell carcinoma. Int J Urol 2004 May;11(5):269–75.
4. Mellemkjaer L, Friis S, Olsen JH, et al. Risk of second cancer among women with breast cancer. Int J Cancer 2006 May 1;118(9):2285–92.
5. Rabbani F, Grimaldi G, Russo P. Multiple primary malignancies in renal cell carcinoma. J Urol 1998 Oct;160(4):1255–9.
6. Eng C. Will the real Cowden syndrome please stand up: Revised diagnostic criteria. J Med Genet 2000 Nov;37(11):828–30.
7. Di Silverio F, Sciarra A, Flammia GP, Mariani M, De Vico A. Multiple primary tumors: 17 cases of renal-cell carcinoma associated with primary tumors involving different steroid-hormone target tissues. World J Urol 1997;15(3):203–9.
8. Liu Z, Lu Y, He Z, Chen L, Lu Y. Expression analysis of the estrogen receptor target genes in renal cell carcinoma. Mol Med Rep 2015 Jan;11(1):75–82.
9. Tanaka Y, Sasaki M, Kaneuchi M, Fujimoto S, Dahiya R. Estrogen receptor alpha polymorphisms and renal cell carcinoma–a possible risk. Mol Cell Endocrinol 2003 Apr 28;202(1-2):109–16.
10. Henriksson R, Nilsson S, Colleen S, et al, Survival in renal cell carcinoma-a randomized evaluation of tamoxifen vs interleukin 2, alpha-interferon (leucocyte) and tamoxifen. Br J Cancer 1998 Apr;77(8):1311–7.

Access full text article on other devices

Access PDF of article on other devices

Edorium Journals: An introduction

Edorium Journals Team

About Edorium Journals

Edorium Journals is a publisher of high-quality, open access, international scholarly journals covering subjects in basic sciences and clinical specialties and subspecialties.

Invitation for article submission

We sincerely invite you to submit your valuable research for publication to Edorium Journals.

But why should you publish with Edorium Journals?

In less than 10 words - we give you what no one does.

Vision of being the best

We have the vision of making our journals the best and the most authoritative journals in their respective specialties. We are working towards this goal every day of every week of every month of every year.

Exceptional services

We care for you, your work and your time. Our efficient, personalized and courteous services are a testimony to this.

Editorial Review

All manuscripts submitted to Edorium Journals undergo pre-processing review, first editorial review, peer review, second editorial review and finally third editorial review.

Peer Review

All manuscripts submitted to Edorium Journals undergo anonymous, double-blind, external peer review.

Early View version

Early View version of your manuscript will be published in the journal within 72 hours of final acceptance.

Manuscript status

From submission to publication of your article you will get regular updates (minimum six times) about status of your manuscripts directly in your email.

Our Commitment

Six weeks

You will get first decision on your manuscript within six weeks (42 days) of submission. If we fail to honor this by even one day, we will publish your manuscript free of charge.*

Four weeks

After we receive page proofs, your manuscript will be published in the journal within four weeks (31 days). If we fail to honor this by even one day, we will publish your manuscript free of charge and refund you the full article publication charges you paid for your manuscript.*

Favored Author program

One email is all it takes to become our favored author. You will not only get fee waivers but also get information and insights about scholarly publishing.

Institutional Membership program

Join our Institutional Memberships program and help scholars from your institute make their research accessible to all and save thousands of dollars in fees make their research accessible to all.

Our presence

We have some of the best designed publication formats. Our websites are very user friendly and enable you to do your work very easily with no hassle.

Something more...

We request you to have a look at our website to know more about us and our services.

* Terms and condition apply. Please see Edorium Journals website for more information.

We welcome you to interact with us, share with us, join us and of course publish with us.

Edorium Journals: On Web

Browse Journals

CONNECT WITH US

This page is not a part of the published article. This page is an introduction to Edorium Journals and the publication services.