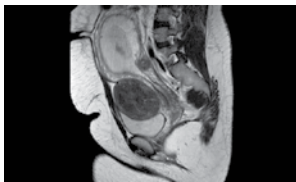


International Journal of Case Reports and Images



Cover Figure:



Contents

Vol. 7, No. 3 (March 2016)

Cover Image

A 30-year-old female with suspected recurrent ovarian granulosa cell tumor in pregnancy. Contrast-enhanced sagittal MRI image showing large predominantly isotense pelvic mass measuring 8.9 cm x 7.1 cm. Areas of hypointensities within it with correlating hyperintensities likely due to cystic changes appears separate from the uterus. (A: pregnant uterus, B: mass, C: bladder).

Case Report

- 143** A case report of papular-purpuric gloves and socks syndrome: A manifestation of the parvovirus B19
Inês Burmester, André Santa-Cruz, Julieta Ramalho, Maria João Regadas, Paulo Gouveia, Guilherme Castro Gomes, Cristina Ângela, Narciso Oliveira, Fernando Mota-Garcia, António Oliveira e Silva
- 149** Recurrent osteosarcoma of maxilla presenting as fungating mass: A case report
T. T. Sivakumar, Pratheep Jeevadas, Varun B. Raghavanpillai, Subramonian Sivaraj, Anna P. Joseph, Saira E. Denny
- 154** Disseminated varicella zoster in an immunocompromised patient: A case report
Raymond E. Kennedy, Narpinder Dhanoa, Kevin Frey
- 158** Recurrent giant hydatid cyst in the left axilla: A case report
Abbas Alibakhshi, Mehrdad Larry
- 162** Preauricular Pilonidal Sinus: The first reported case
Abdulwahid M. Salih, Fahmi H. Kakamad
- 165** Subserosal fibroid thought to be recurrent granulosa cell tumor in a pregnant patient
Hiba J. Mustafa
- 170** Childhood pyoderma gangrenosum: A case report
Pauline Dioussé, Ndiaga Gueye, Mariama Bammo, Thierno Abdou Aziz, Haby Dione, Amadou Mactar Gueye, Fatou Seck, Mame Thierno Dieng, Bernard Marcel Diop, Mamadou Moustapha Ka

- 175** Scalp pilonidal sinus: A case report
Abdulwahid M. Salih, Fahmi H. Kakamad
- 178** Testicular torsion in a patient with four testes and the ultrasound findings
Alborz Jahangiri, Arash Moghadam
- 181** Mucinous cystadenoma presenting as appendiceal mucocele
Nirav Kishor Desai, Vladimir Rubinshteyn, Mena Ayoub, Asaf Gave
- 185** Osteosarcoma of the middle and distal phalanges of the little toe with a cancerous ulcer
Tomoya Matsunobu, Hirofumi Bekki, Katsumi Harimaya, Yoshihiro Matsumoto, Makoto Endo, Kojiro Yoshitake, Yoshinao Oda, Yukihide Iwamoto
- 190** A huge ovarian tumor: Perioperative ventilation challenges
Wan Fadzlina Wan Muhd Shukeri, Wan Mohd Nazaruddin Wan Hassan

Clinical Images

- 195** Left main coronary artery originating from the non-coronary sinus: A rare low-risk coronary anomaly
Razan F. Binyousef, Fahed K. Habib, Mohammed W. Althobaiti
- 198** Is it just another case of acute uncomplicated cholecystitis? A case of emphysematous cholecystitis an uncommon complication and associated image findings
Sinead Culleton, John Bruzzi
- 201** Bicipitoradial bursitis in a patient with rheumatoid arthritis
Pui Shan Julia Chan

All Articles:



SUBMISSION INSTRUCTIONS

All manuscripts, including illustrations, should be submitted at: www.ijcasereportsandimages.com/submit or email to: submit@ijcasereportsandimages.com

Author Guidelines: www.ijcasereportsandimages.com/submit/instructions-for-authors.php

For any questions contact the Editorial Office via e-mail at: info@ijcasereportsandimages.com or Fax: 1-773-409-5040