CASE REPORT OPEN ACCESS

Free floating right atrial thrombus leading to occlusion of the tricuspid valve in a patient with cirrhosis

Turgut Karabag, Sait Mesut Dogan, Muhammet Rasit Sayin, Cem Çil, Mustafa Aydin

ABSTRACT

Introduction: Right atrial thrombi are rare conditions in structurally normal hearts, except for special conditions such as hypercoagulable states, malignant tumors and some systemic diseases. Case Report: We present a case of giant free-floating atrial thrombus extending from the inferior vena cava into the right atrium and leading to occlusion of the tricuspid valve, in a 55-year-old female patient being followed up for cirrhosis. Conclusion: Free-floating right heart thrombus is an extremely rare and dangerous phenomennon which can result in highly dangerous complications. Transthoracic echocardiography, being easily accessible and practical, is a valuable tool for rapid diagnosis. Free-floating thrombi, is an extremely dangerous phenomenon that requires immediate diagnosis and treatment. An immediate decision should be made in these patients for whom treatment options include thrombolytic therapy, medical treatment and surgical intervention in appropriate patients.

Keywords: Free-floating thrombus, Tricuspid valve occlusion, Cirrhosis, Hypercoagulable state

Turgut Karabag[1], Sait Mesut Dogan[1], Muhammet Rasit Sayin[1], Cem Çil[1], Mustafa Aydin[1]
Affiliations: [1]Zonguldak Karaelmas University, School of Medicine, Department of Cardiology, Zonguldak/Turkey.
Corresponding Author: Turgut Karabag, Karaelmas Universitesi Tıp Fakultesi, Kardiyoloji Bolumu, 67600-Kozlu-Zonguldak Turkey; Ph: +90 372 2571517; Fax: +90 372 2577395; Email: turgutkarabag@yahoo.com

Received: 04 October 2011
Accepted: 17 July 2012
Published: 01 October 2012

****

Karabag T, Dogan SM, Sayin MR, Çil C, Aydin M. Free floating right atrial thrombus leading to occlusion of the tricuspid valve in a patient with cirrhosis. International Journal of Case Reports and Images 2012;3(10):51–53.

****

doi:10.5348/ijcri-2012-10-200-CR-13

INTRODUCTION

Free-floating right heart thrombi are a rare phenomenon leading to severe complications such as occlusion of the tricuspid valve and severe pulmonary embolism [1]. We hereby present a case of giant free-floating atrial thrombus leading to occlusion of the tricuspid valve, which is considered to have migrated from the portal vein to the right atrium in a 55-year-old female patient being followed up for cirrhosis secondary to hepatitis C and discuss the treatment options.

CASE REPORT

A 55-year-old female patient was admitted to our hospital with complaints of swelling of the abdomen and legs. It was learnt that the patient had been followed up for cirrhosis secondary to hepatitis C for ten years and had received ribavirin treatment until last year. She was on amlodipine for hypertension and ursodeoxycholic acid. She had no history of drug abuse. Physical examination revealed blood pressure of 120/80 mmHg, pulse of 88/beat per minute and body temperature of 36.3°C. Cardiovasculary examination revealed diastolic murmur in the tricuspid focus. Bilateral leg edema was also noted and there were findings consistent with ascites in the abdomen. Other system examinations were normal. Electrocardiography and teleradiography were also normal. Two dimensional echocardiogarphy

revealed a 62x35 mm mobile thrombus extending from the inferior vena cava into the right atrium (Figure 1). Thrombus was moving to and fro into the right ventricle with each cycle (Figure 2). Thrombus was found to have caused occlusion of the tricuspid valve, with a maximum gradient of 10 mmHg and a mean gradient of 5 mmHg by continuous wave Doppler (Figure 3). The patient had a normal ejection fraction with dilated left atrium and mild mitral regurgitation. An abdominal ultrasound showed ascites in the abdomen, enlargement of the hepatic vein and portal vein and a 29 mm-long thrombus in the portal vein. The thrombus in the right atrium was considered to have originated from the portal vein. Levels of protein C, protein S and antithrombin III were 73%, 54% and 97%, respectively. Protein C and antithrombin III levels were near, protein S was under to the lower limit. Levels of D-dimer and ANA were normal. Deep venous thrombus was not detected in bilateral lower-extremity Doppler. The patient was advised for surgery, with a joint decision by gastroenterology and cardiovascular surgery. The patient refused surgical intervention and was placed under follow-up with heparin infusion followed by warfarin administration. After six months, no complication was occured and the thrombus was completely resolved.

DISCUSSION

Free-floating right heart thrombus is an extremely rare phenomenon which can result in highly dangerous complications. The condition manifests mainly through its symptoms, which result from the occlusion of the tricuspid valve or from a pulmonary embolism [1]. The mortality rate is approximately 40% in cases of right heart thrombi with the potential to cause severe pulmonary embolism [2]. Thus, transthoracic echocardiography, being easily accessible and practical, is a valuable tool for rapid diagnosis. Right atrial thrombi are rare in structurally normal hearts, except for catheter-related thrombi. However, it can occur in association with hypercoagulable states, malignant tumors [3] and some systemic diseases [1]. Right atrial thrombus can also be seen in low output states, cardiomyopathies and cardiac arrhythmias [4]. Although its mechanism in cirrhosis has not been fully elucidated, a hypercoagulable state can occur due to various local and systemic mechanisms. It often leads to a tendency for thrombosis due to decreased portal venous flow and decreased natural anticoagulants such as, protein C, S and antithrombin III [5] which were detected near or under the normal limits in our patient. Besides, one study reported that up to 70% of all patients with portal vein thrombosis and cirrhosis have an underlying inherited hypercoagulable state (such as Factor V Leiden mutation and prothrombin 20210 gene mutation) [6]. In our case, thrombus in the right atrium was considered to have migrated from the portal vein thrombosis through inferior vena cava into the right atrium. Our patient had no systemic disease or

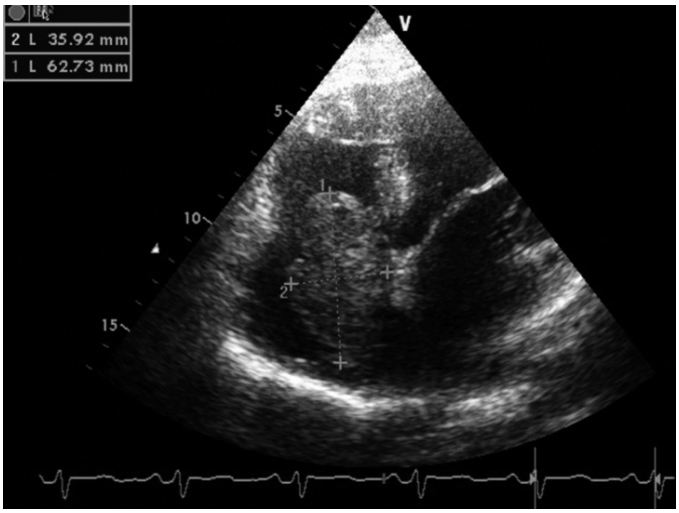

Figure 1: Apical four chamber view demonstrating free-floating thrombus in the right atrium (62x35 mm).

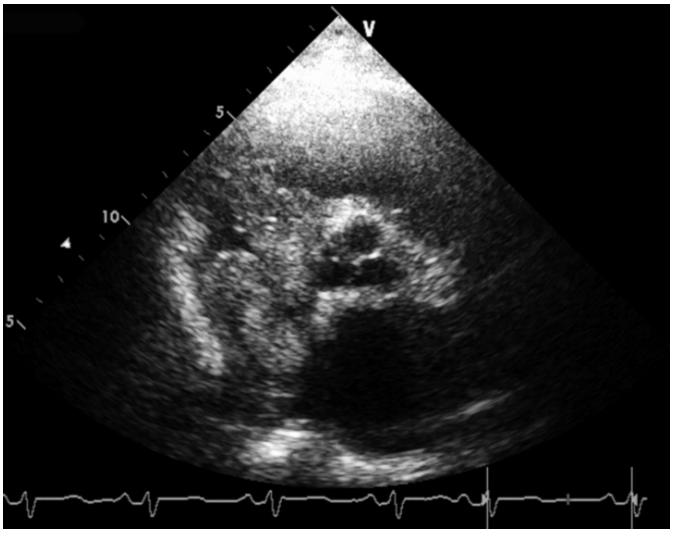

Figure 2: Parasternal short axis view showing thrombus moving to and fro into the right ventricle.

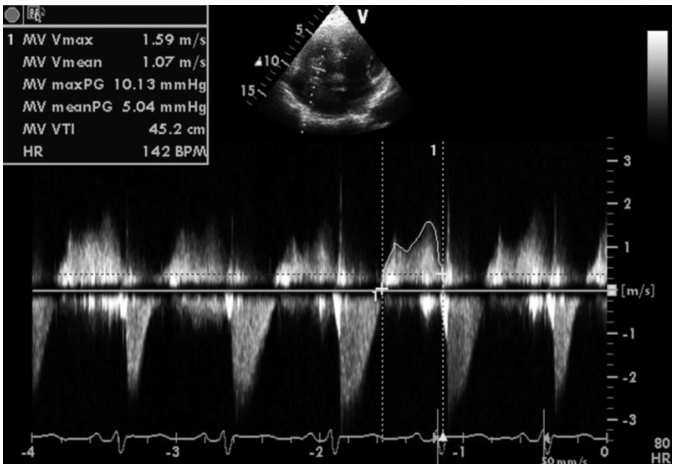

Figure 3: Apical four chamber view demonstrating tricuspid valve occlusion and gradient through valve caused by thrombus by CW Doppler.

malignancy other than cirrhosis. The patient was in sinus rhythm and had no structural heart disease such as cardiomyopathy.

Right atrial thrombus, detected by two-dimensional echocardiography, may take different configurations during the cardiac cycle, reflecting, as seen in our case, the coiling and uncoiling of the elongated clot as it moves back and forth through the tricuspid valve, thus even leading to occlusion of the tricuspid valve [7]. Even though the treatment of right heart thrombi remains controversial, recommended treatment options include surgery, thrombolytic therapy and medical follow-up. Surgical intervention is recommended as soon as the diagnosis is established in patients with thrombus in the right atrial cavity [8], whereas thrombolytic therapy is another treatment of choice. The possibility of a pulmonary embolism caused by a fragmented thrombus due to thrombolytic therapy can cause unfavorable complications [9]. In addition, anticoagulation with heparin followed by warfarin administration is another treatment option in patients at high risk for surgery [10]. Surgery was recommended for this patient due to the size of the thrombus and high risk for pulmonary embolism. However, the patient refused surgical intervention and was placed under follow up with heparin infusion followed by warfarin administration.

CONCLUSION

Right heart thrombi, particularly free-floating thrombi, is an extremely dangerous phenomenon that requires immediate diagnosis and treatment. Transthoracic echocardiography may prove useful in emergency diagnosis. An immediate decision should be made in these patients for whom treatment options include thrombolytic therapy, medical treatment and surgical intervention in appropriate patients.

****

Author Contributions

Turgut Karabag – Conception and design, Acquisition of data, Analysis and interpretation of data, Drafting the article, Revising it critically for important intellectual content, Final approval of the version to be published
Sait Mesut Dogan – Conception and design, Acquisition of data, Analysis and interpretation of data, Drafting the article, Revising it critically for important intellectual content, Final approval of the version to be published
Muhammet Rasit sayin – Conception and design, Acquisition of data, Analysis and interpretation of data, Final approval of the version to be published
Cem Cil – Conception and design, Acquisition of data, Analysis and interpretation of data, Final approval of the version to be published
Mustafa Aydin – Drafting the article, Revising it critically for important intellectual content, Final approval of the version to be published

Guarantor

The corresponding author is the guarantor of submission.

Conflict of Interest

Authors declare no conflict of interest.

Copyright

REFERENCES

1. Sökmen G, Sökmen A, Yasım A, Oksüz H. Witnessed migration of a giant, free-floating thrombus into the right atrium during echocardiography, leading to fatal pulmonary embolism. Arch Turk Soc Cardiol 2009;37:41–3.
2. Barriales V, Tamargo JA, Aguado MG, Martín M, Rondán J, Segovia E, et al. Floating thrombi on the Eustachian valve as a complication of venous thromboembolic disease. Int J Cardiol 2004;93:289–91.
3. DeGroat TS, Parameswaran R, Popper PM, Kotler MN. Left ventricular thrombi in association with normal left ventricular wall motion in patients with malignancy. Am J Cardiol 1985;56:827–8.
4. Panidis IP, Kotler MN, Mintz GS, Ross J. Clinical and echocardiographic features of right atrial masses. Am Heart J 1984;107:745–8.
5. Parikh S, Shah R, Kapoor P. Portal Vein Thrombosis. The American Journal of Medicine 2010;123:111–9. (review).
6. Amitrano L, Brancaccio V, Guardascione MA, Margaglione M, Iannaccone L, D'Andrea G, et al. Inherited coagulation disorders in cirrhotic patients with portal vein thrombosis. Hepatology 2000;31:345–8.
7. Alhaddad IA, Soubani AO, Brown EJ, Jonas EA, Freeman I. Cardiogenic shock due to huge right atrial thrombus. Chest 1993;104:1609–10.
8. Farfel Z, Shechter M, Vered Z, Rath S, Goor D, Gafni J. Review of echocardiographically diagnosed right heart entrapment of pulmonary emboli-in-transit with emphasis on management. Am Heart J 1987;113:171–8.
9. Pierre-Justin G, Pierard LA. Management of mobile right heart thrombi: a prospective series. Int J Cardiol 2005;99:381–8.
10. Porath A, Avnun L, Hirsch M, Ovsyshcher I. Right atrial thrombus and recurrent pulmonary emboli secondary to permanent cardiac pacing--a case report and short review of literature. Angiology 1987;38:627–30.